

Recessed Femoral Interference Screws in Anterior Cruciate Ligament Reconstruction

Anup A. Shah, MD, Michael M. Heckman, MD, and James S. Gilley, MD

Abstract

There are multiple modes of femoral fixation for the treatment of the anterior cruciate ligament (ACL)-deficient knee. Femoral interference screws are commonly used and are often buried to accommodate a graft-tunnel mismatch.

After performing ACL reconstructions and imaging the ACL in 3 cadaveric knee specimens, obvious graft excursion and impingement was seen with recessed femoral interference screw fixation. The consequences of impingement are well known, and when faced with a graft-tunnel mismatch, alternative modes of fixation are advised.

Anterior cruciate ligament (ACL)-deficient knees have multiple surgical treatment options with a variety of graft and femoral fixation techniques, including autografts and allografts using interference screws, transfixion pins, EndoButtons (Smith & Nephew Endoscopy, Andover, Mass), and staples and sutures to a screw post. Commonly used autografts include bone-patellar tendon-bone (BTB), quadrupled semitendinosus/gracilis tendon, and quadriceps tendon. Allograft options include bone-patellar tendon-bone, hamstring tendons, anterior and posterior tibialis tendons, and Achilles tendon.¹⁻³

Numerous techniques for ACL graft fixation have been advocated in both clinical and biomechanical studies, but the specific type of ACL graft fixation that is used appears to be primarily a matter of personal preference on the part of the surgeon. Although the surgeon performing an ACL reconstruction now has the option to use techniques such as transfixion pin and EndoButton systems, interference screws are still used commonly as a graft fixation technique.

We conducted this study to elucidate the complications that can occur when interference screws are buried in the femoral tunnel during ACL reconstruction, particularly in the case of a graft-tunnel mismatch.

Dr. Shah is a Chief Resident, and Dr. Heckman is Clinical Professor, University of Texas Health Science Center, San Antonio, Texas.

Dr. Gilley is in private practice in San Antonio, Texas.

Address correspondence to: Anup A. Shah, MD, 7703 Floyd Curl Dr, MC 7774, San Antonio, TX 78229 (tel, 210-567-5139; fax, 210-567-5277; anupshah78@hotmail.com).

Am J Orthop. 2009;38(6):291-294. Copyright, Quadrant HealthCom Inc. 2009. All rights reserved.

MATERIALS AND METHODS

Four fresh-frozen knee specimens were obtained. Open ACL reconstructions were performed using BTB autografts with the Acufex guide system (Smith & Nephew Endoscopy, Andover, Mass) on 3 of these knees, leaving the fourth as a control. Femoral fixation with interference screws and an EndoButton was performed. Knee 1 had a buried femoral interference screw (Figure 1), knee 2 had a screw at the bone-joint interface (Figure 2), knee 3 underwent EndoButton fixation (Figure 3), and knee 4 was the control (used to evaluate natural excursion of ACL).

ACL reconstruction with interference screws was performed using a midline medial parapatellar approach with BTB graft harvest. The graft was prepared, each bone plug was sized to 10 mm, and polyester sutures (Ethibond; Ethicon, Ciudad Juarez, Chihuahua, Mexico) were placed for graft passage and fixation. The native ACL was resected, and a minimal femoral notchplasty was performed. Notchplasty was performed using quarter-inch osteotomes and removing approximately 3 mm of bone in each direction around the notch. Ten-millimeter tibial and femoral tunnels were created, and the over-the-top position on the posterior lateral femur was confirmed by direct visualization. Subsequently, the graft was pulled into position. Next, a pilot hole for screw placement was made anterior to the graft at the femoral notch-joint interface. A cannulated titanium screw set (Figures 4A, 4B) was used to place the interference screws (9×20 mm). For knee 1, the screw was buried approximately 10 mm. For knee 2, the screw was placed at the notch-joint interface.

An identical surgical technique was used when reconstructing the ligament with the EndoButton. Ten-millime-

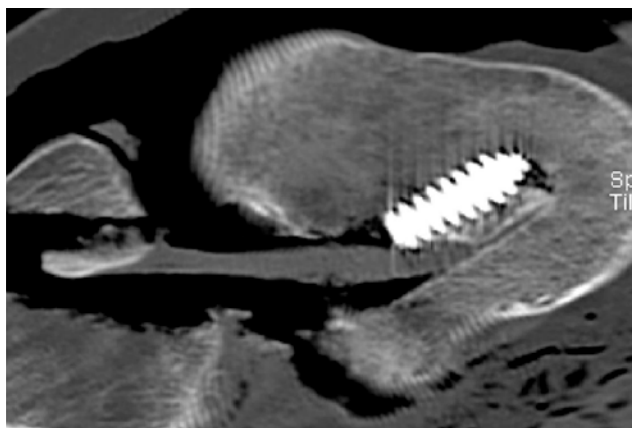


Figure 1. Anterior cruciate ligament reconstruction with recessed femoral interference screw.

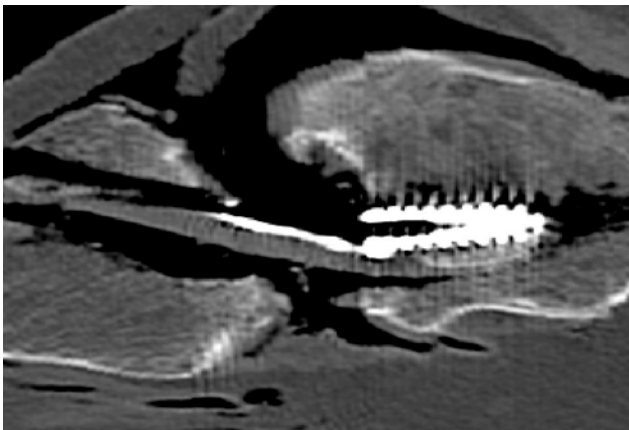


Figure 2. Anterior cruciate ligament reconstruction with femoral interference screw at bone joint interface.

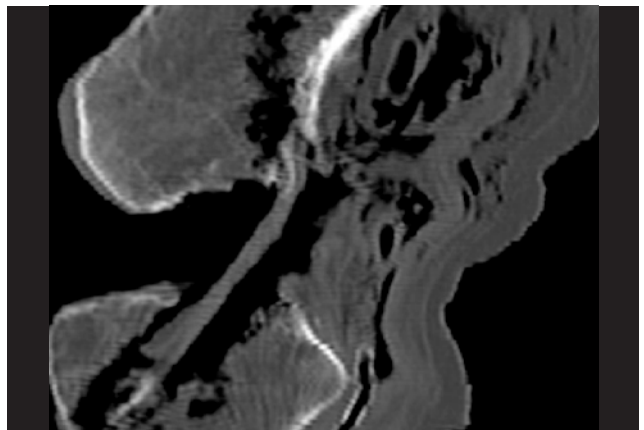


Figure 3. Anterior cruciate ligament reconstruction with EndoButton.

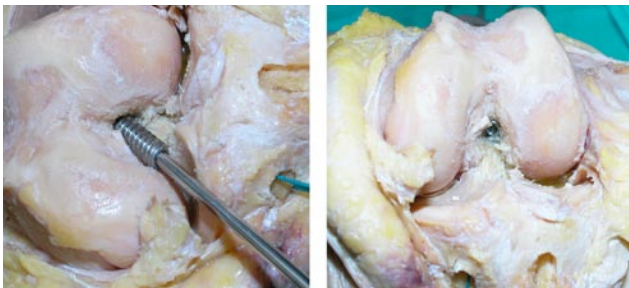


Figure 4. (A,B) Femoral interference screw placement.

ter tunnels were created, and calculations were performed to seat the femoral bone plug within 5 mm of the joint surface. The EndoButton and graft were then finally pulled into position (Figure 5).

Sagittal computed tomography (CT; Siemens spiral CT, Sensation 4, 1-mm cuts with reconstructions) scans of each specimen were taken at 0°, 30°, 60°, and 90° of flexion. Angles were confirmed with a goniometer. During imaging, constant tension on the graft was maintained with 5 pounds of longitudinal traction through a tensiometer attached to the graft.

RESULTS

Each of the 3 reconstructed ACL knee specimens revealed satisfactory graft placement within 1 to 2 mm of the posterior femoral cortex documented by direct visualization and CT. As the knee specimens were extended from 90° of flexion to 0° of extension, increased graft excursion and obvious graft impingement occurred on the edge of the interference screw and roof of the intercondylar notch in knee 1 (Figures 6A–6D). Minimal contact occurred between the graft and the lateral femoral condyle. The anterior defect created to accommodate placement of the interference screw added to graft translation and impingement. This was grossly visualized and seen radiographically in full extension (Figure 6D). On the basis of similar sagittal images, no graft excursion or obvious impingement occurred in knees 2 through 4 (Figures 7A–7C).

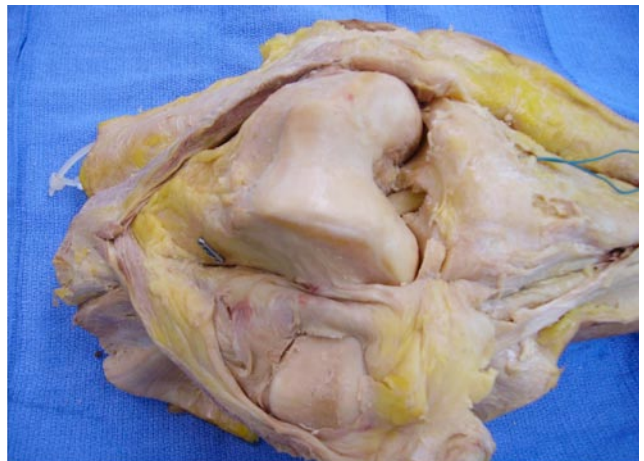


Figure 5. EndoButton on anterolateral aspect of distal femur.

DISCUSSION

ACL reconstruction can be technically challenging, and its pitfalls have been well documented. Emphasis has been placed on graft–tunnel position, and several studies have revealed that creating an anterofemoral tunnel within the intercondylar notch is the most common technical error in single-incision arthroscopic ACL surgical techniques.⁴⁻⁷ Anterior femoral tunnel placement affects graft isometry, causing the graft to tighten in knee flexion, and results in intercondylar roof and anterior notch impingement in extension.

This study reveals that burying femoral interference screws within the femoral tunnel is another technical error, one that in effect results in intercondylar roof and notch impingement, as is clear in Figures 6A through 6D, which show significant graft excursion and impingement to the point of “kinking of the graft.” Taylor and colleagues⁸ acknowledged the theoretical concern of graft impingement with femoral bone plug recession; however, the clinical symptoms of tendon abrasion were not seen. Although this study was performed on cadaver specimens, obvious radiographic impingement occurred, and the consequences of buried screws should be noted. Impingement at the screw–tendon interface is another potential complication

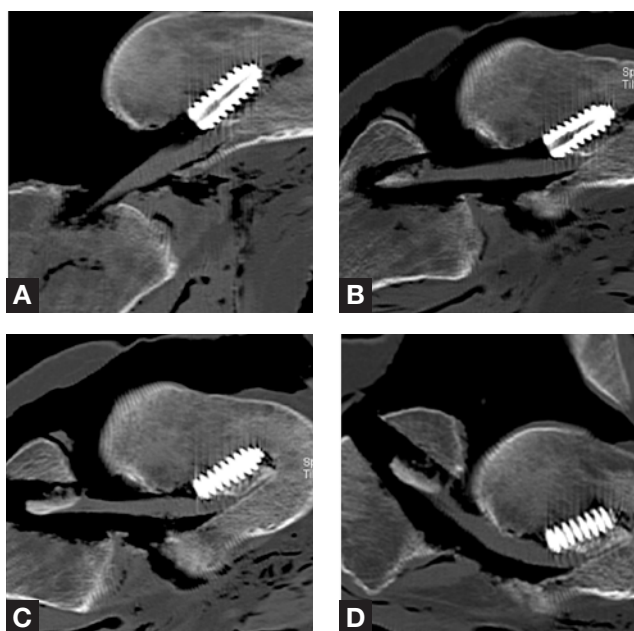


Figure 6. Sagittal images at 90° (A), 60° (B), 30° (C), and 0° (D) of knee 1 (recessed interference screw).

with recessed screws; however, this is usually seen when the screw is proud relative to the bone plug. In this study, great care was taken to advance the screws enough to prevent the possible stress riser from a screw–tendon interface.

If a surgeon is faced with a graft–tunnel mismatch, interference screws are often buried in an attempt to correct the mismatch. A graft–tunnel mismatch occurs when the BTB graft is too long and the tibial bone plug is exposed on the anterior tibial cortex when the femoral bone plug is placed at a level flush to the surface of the femoral intercondylar notch (Figure 8). Graft–tunnel mismatch may also occur when a tibial tunnel is drilled short, which results in minimal length for the graft to be placed within the tibia (Figure 8). To correct for this mismatch, the BTB graft is often advanced into the femoral tunnel, and the interference screws are buried adjacent to the femoral bone plug. When femoral interference screw and bone plug are driven deeper, satisfactory tibial bony healing can occur, protrusion of the tibial plug is prevented, and creation of a tibial metaphyseal trough is avoided. As a result, a larger anterior defect occurs in the femoral tunnel, resulting in excursion, impingement, and increased graft–roof contact pressures, all of which have proved to be deleterious to the tendon grafts.

Much has been written about use of anatomical landmarks, angle of entry variation, and graft and tunnel measurements to prevent graft–tunnel mismatches.^{9–13} This article does not delve into the details of graft–tunnel mismatch prevention but informs surgeons about the consequences of burying femoral bone plugs and screws when correcting for the mismatch.

Impingement of the ACL against the intercondylar notch is thought to cause anterior knee pain, extension deficit, and potential graft failure with recurrent instability.^{14–17} Watanabe

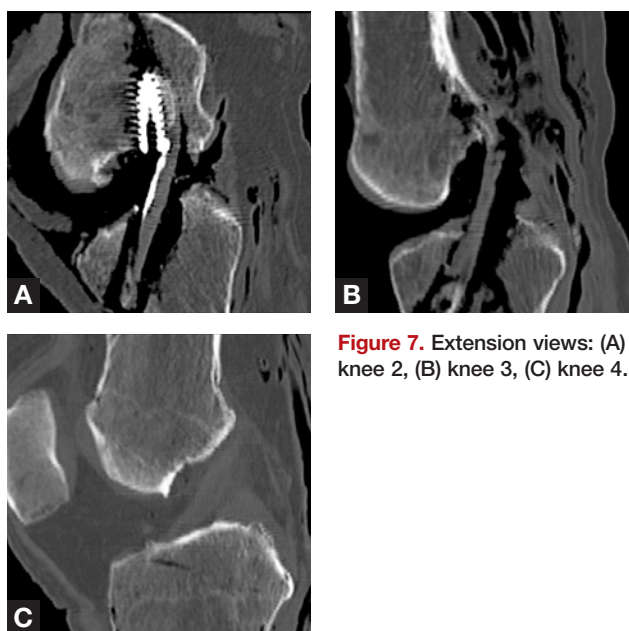

Figure 7. Extension views: (A) knee 2, (B) knee 3, (C) knee 4.

and Howell¹⁸ described the arthroscopic findings of impingement. During a “second look” arthroscopy, they noted grafts having one or more of the following: fractured bundles, guillotined remnants at the tibial insertion, parallel fragmentation of an uninterrupted graft, a fibrous nodule, or an extrusion of graft material at the outlet of the notch. These findings, they concluded, were caused by a mechanical injury, which may have been responsible for the clinical symptoms of impingement. In addition, Goss and colleagues¹⁹ established that graft damage occurred secondary to increased contact pressures with roof impingement. Given the findings in our present study, burying femoral interference screws is another cause of impingement. Therefore, previous recommendations to recess femoral interference screws as a means of correcting for graft–tunnel mismatch should not be followed.

Although an aggressive notchplasty would seem to mitigate the effects of impingement in patients with narrow intercondylar notches or anterior femoral tunnel placement,

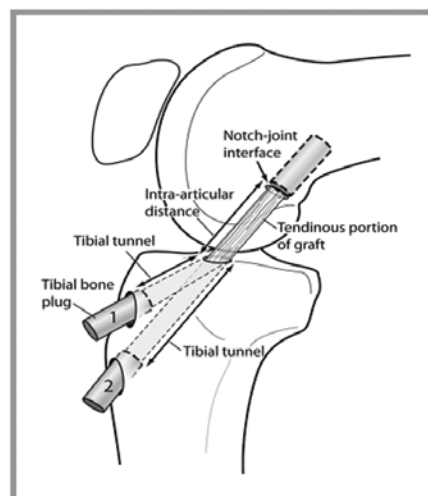


Figure 8. Graft–tunnel mismatch.

Fu and colleagues²⁰ and Hame and colleagues²¹ discussed roofplasty and its potential consequences, including abnormal kinematics secondary to displacement of the femoral insertion, articular cartilage histopathologic changes consistent with degenerative arthrosis, increased postoperative pain, bleeding, swelling, and potential notch overgrowth. We calculated that, when the graft is buried 10 mm, approximately 1.5 cm of bone in the intercondylar notch (sum of osteotomized notch bone) would have to be resected after graft placement to prevent notch impingement.

CONCLUSIONS

Accurate femoral tunnel placement and fixation are crucial steps in ACL reconstruction. Although surgeons make every attempt to place the graft as posterior as possible in the femur, this placement can be compromised when interference screws are buried. Recessing the graft and screw creates a large defect that allows anterior graft excursion and impingement at the intercondylar roof and anterior notch before full extension. Therefore, we recommend placing femoral interference screws and bone plug at the bone–joint interface and either creating a tibial trough or providing alternative means of fixation in the case of a graft–tunnel mismatch.

AUTHORS' DISCLOSURE STATEMENT AND ACKNOWLEDGMENTS

The authors report no actual or potential conflict of interest in relation to this article.

We thank South Texas Radiology for assistance with imaging of cadaveric knee specimens and James Muzzucca for assistance with knee specimens.

REFERENCES

1. Levitt RL, Malinin T, Posada A, Michalow A. Reconstruction of anterior cruciate ligaments with bone–patellar tendon–bone and Achilles tendon allografts. *Clin Orthop*. 1994;(303):67-78.
2. Siebold R, Buelow JK, Bos L, Ellerman A. Primary anterior cruciate reconstruction with fresh frozen patellar vs. Achilles tendon allograft. *Arch Orthop Trauma Surg*. 2003;123(4):180-185.
3. Zamorano DP, Gold SM. Reverse Achilles tendon allograft technique for

- anterior cruciate ligament reconstruction. *Arthroscopy*. 2005;21(6):769.
4. Harner CD, Giffin JR, Dunteman RC, Annunziata CC, Friedman MJ. Evaluation and treatment of recurrent instability after anterior cruciate ligament reconstruction. *Instr Course Lect*. 2001;50:463-474.
5. Johnson DL, Fu FH. Anterior cruciate ligament reconstruction: why do failures occur? *Instr Course Lect*. 1995;44:391-406.
6. Johnson DL, Harner CD, Maday MG, Fu FH. Revision anterior cruciate ligament surgery. In: Fu FH, Harner CD, Vince KG, eds. *Knee Surgery*. Baltimore, MD: Williams & Wilkins: 1994:877-895.
7. Wetzler MJ, Bartolozzi AR, Gillespie MJ, et al. Revision anterior cruciate ligament reconstruction. *Oper Tech Orthop*. 1996;6:181-189.
8. Taylor DE, Dervin GF, Keene GC. Femoral bone plug recession in endoscopic anterior cruciate ligament reconstruction. *Arthroscopy*. 1996;12(4):513-515.
9. Fowler BL, DiStefano VJ. Tibial tunnel bone grafting: a new technique for dealing with graft–tunnel mismatch in endoscopic anterior cruciate ligament reconstruction. *Arthroscopy*. 1998;14(2):224-228.
10. Gill TJ, Steadman JR. Anterior cruciate ligament reconstruction the two-incision technique. *Orthop Clin North Am*. 2002;33(4):727-735.
11. Hartman GP, Sisto DJ. Avoiding graft–tunnel mismatch in endoscopic anterior cruciate ligament reconstruction: a new technique. *Arthroscopy*. 1999;15(3):338-340.
12. Mariani PP, Calvisi V, Margheritini F. A modified bone–tendon–bone harvesting technique for avoiding tibial tunnel–graft mismatch in anterior cruciate ligament reconstruction. *Arthroscopy*. 2003;19(1):E3.
13. Shaffer B, Gow W, Tibone JE. Graft–tunnel mismatch in endoscopic anterior cruciate ligament reconstruction: a new technique of intraarticular measurement and modified graft harvesting. *Arthroscopy*. 1993;9(6):633-646.
14. Ferkel RD, Fox JM, Wood D, Del Pizzo W, Friedman MJ, Snyder SJ. Arthroscopic “second look” at the Gore-Tex ligament. *Am J Sports Med*. 1989;17(2):147-152.
15. Howell SM, Clark JA. Tibial tunnel placement in anterior cruciate ligament reconstructions and graft impingement. *Clin Orthop*. 1992;(283):187-195.
16. Howell SM, Taylor MA. Failure of reconstruction of the anterior cruciate ligament due to impingement by the intercondylar roof. *J Bone Joint Surg Am*. 1993;75(7):1044-1055.
17. Jackson DW, Schaefer RK. Cyclops syndrome: loss of extension following intra-articular anterior cruciate ligament reconstruction. *Arthroscopy*. 1990;6(3):171-178.
18. Watanabe BM, Howell SM. Arthroscopic findings associated with roof impingement of an anterior cruciate ligament graft. *Am J Sports Med*. 1995;23(5):616-625.
19. Goss BC, Hull ML, Howell SM. Contact pressure and tension in anterior cruciate ligament grafts subjected to roof impingement during passive extension. *J Orthop Res*. 1997;15(2):263-268.
20. Fu FH, Bennett CH, Ma CB, Menetrey J, Lattermann C. Current trends in anterior cruciate ligament reconstruction. Part II. Operative procedures and clinical correlations. *Am J Sports Med*. 2000;28(1):124-130.
21. Hame SL, Markolf KL, Hunter DM, Oakes DA, Zoric B. Effects of notchplasty and femoral tunnel position on excursion patterns of an anterior cruciate ligament graft. *Arthroscopy*. 2003;19(4):340-345.

This paper will be judged for the Resident Writer's Award.
