

Osteochondral Lesion of the Femoral Head in a Fencer: A Case Report

Yoshihide Nakamura, MD, PhD, Hiromasa Mitsui, MD, PhD,
Satoshi Toh, MD, PhD, and Naoki Echigoya, MD, PhD

Osteochondral lesions, including osteochondritis dissecans (OCD) in the elbow, knee, and ankle, are very common in athletes.¹⁻³ However, there are few reports of osteochondral lesions of the hip.^{4,5} Weaver and colleagues⁵ reported 11 cases of femoral head osteochondral lesions in athletes. Other authors have reported subchondral stress fractures of the femoral head associated with repeated impaction and axial loads in young populations.^{4,6-8}

We report a rare case of an osteochondral lesion in a young female fencer. Repeated axial impaction force may cause osteochondral lesions of the femoral head in addition to stress fractures. This condition is easily overlooked because there are less typical clinical findings. We emphasize the usefulness of arthroscopy to diagnose this rare

condition and to avoid unnecessary surgical treatment, such as osteotomy and arthroplasty. The authors have obtained the patient's guardian's written informed consent for print and electronic publication of the case report.

months after she first complained of right hip pain (10 months after starting fencing), she again noticed right hip pain during fencing, especially when performing lunging or attacking actions. During these actions, the player plants the heel firmly on

“We emphasize the usefulness of arthroscopy to diagnose [osteochondral lesions] and to avoid unnecessary surgical treatment, such as osteotomy and arthroplasty.”

CASE REPORT

A 16-year-old girl had begun fencing at age 13. She had suffered from right hip pain 3 months after starting fencing. The symptoms spontaneously disappeared after a few weeks without any medical treatment. Seven

the floor with the right hip in deep flexion and knee flexed to thrust the body forward. The patient presented to our hospital 10 months after the onset of symptoms. She complained of persisting hip pain and was not able to continue fencing. A

Dr. Nakamura is Associate Professor, Dr. Mitsui is Research Associate, and Dr. Toh is Professor, Department of Orthopaedic Surgery, Hirosaki University Graduate School of Medicine, Hirosaki City, Aomori, Japan.

Dr. Echigoya is Chief Orthopedic Surgeon, Department of Orthopaedic Surgery, Kuroishi Hospital, Kuroishi City, Aomori, Japan.

Address correspondence to: Yoshihide Nakamura, MD, Department of Orthopaedic Surgery, Hirosaki University Graduate School of Medicine, 5 Zaifucho, Hirosaki City, Aomori, Japan 036-8562 (tel, 81-172-39-5083; fax, 81-172-36-3826; e-mail, yoshi-n@cc.hirosaki-u.ac.jp).

Am J Orthop. 2009;38(7):356-359. Copyright, Quadrant HealthCom Inc. 2009. All rights reserved.

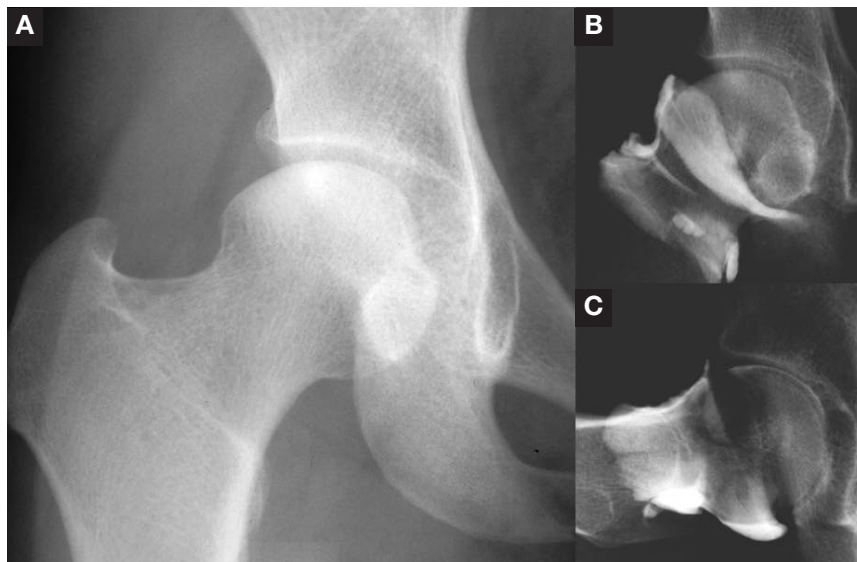


Figure 1. (A) Plain radiograph shows very minimal osteosclerotic change of the weight-bearing portion of the femoral head. (B, C) The arthrography showed no findings of torn labrum or any free bodies.

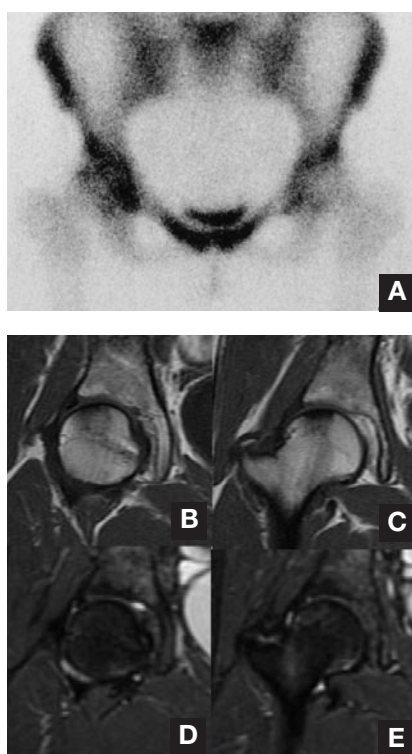


Figure 2. (A) High-uptake lesion was seen in bone scintigram at the femoral head. There was a low-signal area in the upper part of the femoral head both in T₁-weighted (B, C) and T₂-weighted (D, E) magnetic resonance images. There were no findings of bone marrow edema in the acetabulum.

plain radiograph showed very minimal change of osteosclerosis of the weight-bearing portion of the femoral head (Figure 1A). The arthrography showed no findings of torn labrum or any free bodies (Figures 1B, 1C). A high-uptake lesion was seen in bone scintigram at the femoral head (Figure 2A). There was a low-signal area in the upper part of the femoral head in both T₁-weighted (Figures 2B, 2C) and T₂-weighted magnetic resonance images (MRI) (Figures 2D, 2E). There were no findings of bone marrow edema in the acetabulum.

Although the patient was restricted from fencing, avoided partial weight-bearing, and used double crutches for 2 months, her hip pain remained. For further investigation, we performed an arthroscopy of the right hip. There were no abnormal findings at the acetabular cartilage. The labrum did not show a tear or detachment (Figure

3A). Mild softening of the articular cartilage of the weight-bearing portion of the femoral head was noted (Figure 3B). No surgical intervention was performed under arthroscopy.

After the arthroscopy, the patient was permitted weight-bearing walking as she tolerated the hip pain. She gradually returned to fencing 14 months after the onset of symptoms (2 months after arthroscopy). She fully recovered and returned to competition-level fencing 15 months after the onset of symptoms. Therefore, 5 months of repose were needed for full recovery until she returned to the sport. She continued fencing for 19 months until she graduated from high school.

When the patient visited our hospital 4 years after the onset of symptoms, she did not complain of any symptoms around the hip. The mobility of the affected hip was normal without pain during motion. The radiographs at the latest follow-up showed no abnormal findings except mild residual sclerotic lesion of the femoral head (Figure 4A). A remarkably diminished, small, low-signal lesion of the upper part of the femoral head was confirmed on MRIs at the latest follow-up (Figures 4B-4E).

DISCUSSION

Previous epidemiologic studies have shown that hip injuries constitute 5% to 9% of injuries sustained by high school athletes. Osteochondral lesion of the femoral head is a very rare con-

dition.⁹⁻¹¹ Some authors have reported OCD following Legg-Calvé-Perthes disease, but there are few reports of OCD or osteochondral lesions of the femoral head associated with sport activities.¹²⁻¹⁴

Linden and colleagues¹⁵ described 15 cases of OCD. They reported that they found no explanation for OCD other than trauma in 5 patients in their series. Weaver and colleagues⁵ reported 11 cases of femoral head osteochondral lesions in athletes. In only 4 of these 11 cases did the patients recall a discrete traumatic event preceding the onset of the hip pain. The authors postulated that transient subluxation with resultant shearing force or impaction force, such as the force in sudden stops or landing from jumps, is a mechanism for occurrence of osteochondral lesion of the hip. They claimed that MRI evidence of damage to the joint capsule and associated soft-tissue injuries, such as hematoma or edema in muscles or fat, would not necessarily be expected from impaction force because all the abnormal forces would be transmitted directly to the joint itself. Our case also had no definite injury or trauma and also showed no evidence of soft-tissue changes at initial examination.

Etiology of osteochondral lesion or OCD is still unclear and multifactorial.⁸ Several causes have been postulated, including inflammation, genetics, ischemia, ossification, and repetitive trauma. Kusumi and col-

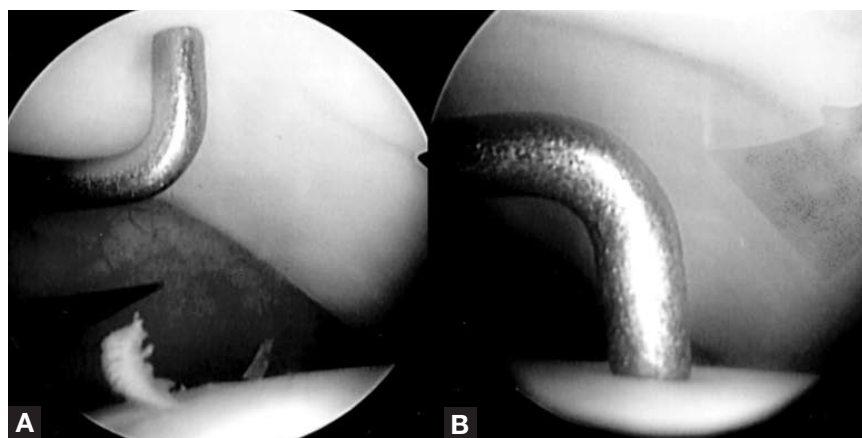


Figure 3. (A) The labrum shows no injury. (B) Softening of the articular cartilage of the weight-bearing portion of the femoral head was confirmed.

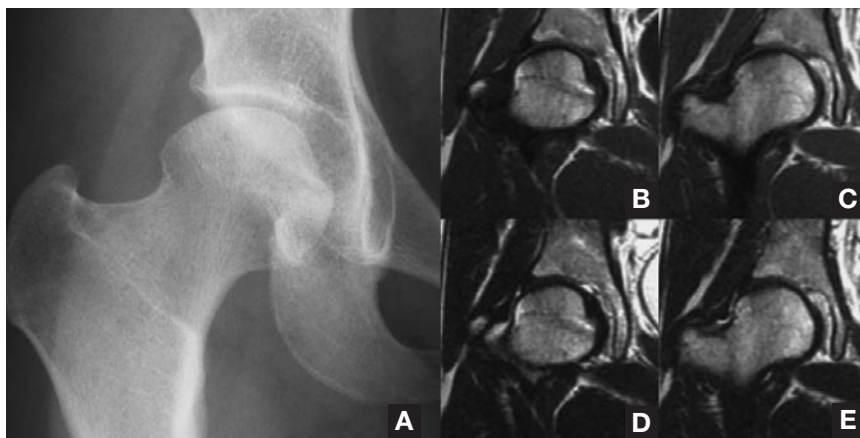


Figure 4. (A) Radiograph at the latest follow-up shows no abnormal findings except mild residual sclerotic lesion of the femoral head. An extremely small low-signal lesion of the upper part of the femoral head was still seen both in T_1 -weighted (B, C) and T_2 -weighted (D, E) magnetic resonance images.

leagues¹⁶ studied the mechanism of progression of osteochondral lesions in the elbow histopathologically. They revealed that the primary pathological changes of the condition were due to damage of articular cartilage induced by repeated stress. In our case, we believe repeated impaction and axial loads to the femoral head in the lunge action of fencing were the primary cause of this condition.

T_1 -weighted and T_2 -weighted MRIs reflected the healing process of the lesion. The absence of low-signal intensity lesions on T_1 -weighted MRIs and high-signal intensity lesions on T_2 -weighted MRIs was due to an adequate period passing to allow for healing of bone marrow edema. Osteochondral lesions should be differentiated from osteonecrosis of the femoral head in order to pro-

There were no findings of obvious cartilage changes in MRIs. In our case, arthroscopy revealed mild softening of the joint cartilage of the femoral head without soft-tissue injuries. Arthroscopy was useful for denying detachment of the labrum, for which the MRI did not provide any findings.^{19,20} Conservative treatments successfully relieved the symptoms in the present case, although a small, abnormal-signal lesion remained only in the MRI.

When a young athlete complains of hip pain, the surgeon should consider osteochondral lesion of the femoral head. It is essential to perform a differential diagnosis from necrosis of the femoral head through careful estimation of the radiographs, MRIs, and bone scintigram. Arthroscopy may be useful in confirming the absence of osteochondral loose bodies or torn labrum, as reported by Edwards and colleagues¹⁹ and Kelly and colleagues.²⁰ To treat osteochondral lesions, one needs to rest the joint and carefully observe the symptoms. The symptoms should disappear in 4 to 6 months by restricting sports activity,

“Because repeated impaction force to the hip joint may be a cause of osteochondral lesions of the femoral head, the surgeon should consider this condition when a young athlete exposed to such impaction force presents with hip pain.”

In recent years, some authors have reported stress fractures of the femoral head in young people.^{4,6-8} Repeated impaction load is the most probable cause of stress fracture of the femoral head, but subchondral stress fractures rarely occur in teenagers such as our patient. Maturity of the skeleton, including cartilage thickness, cartilage strength, and subchondral bone stiffness, may be associated with occurrence of osteochondral lesion or subchondral stress fracture.

In our case, radiographs and MRIs were obtained more than 6 months after the onset of symptoms. Sclerotic change in the radiographs and low-signal intensity lesions on

vide appropriate treatment. The typical finding of osteonecrosis of the femoral head is a band of low-signal intensity on T_1 -weighted MRIs representing the reparative fibrovascular tissue and the reactive new bone formation at the outer margin of the necrotic area.^{17,18} On the other hand, in a MRI of the hip with an osteochondral lesion, there is no band of abnormal signal around the lesion as in previously reported cases.¹⁹ The high-uptake lesion on the scintigram represented residual inflammation or healing process of the lesion. In contrast, a typical finding of osteonecrosis on scintigram is a “cold in hot” pattern.

including limitation of weight-bearing. We believe arthroscopy is useful in clarifying the lesion and avoiding unnecessary surgical treatment, such as osteotomy and arthroplasty, in this relatively rare condition.

CONCLUSIONS

We report a case of osteochondral lesion of the hip associated with sport activity. To our knowledge, this report is the first documentation of an osteochondral lesion in a fencer. Because repeated impaction force to the hip joint may be a cause of osteochondral lesions of the femoral head, the surgeon should consider this con-

dition when a young athlete exposed to such impaction force presents with hip pain.

AUTHORS' DISCLOSURE STATEMENT

The authors report no actual or potential conflict of interest in relation to this article.

REFERENCES

- Kocher MS, Tucker R, Ganley TJ, Flynn JM. Management of osteochondritis dissecans of the knee: current concepts review. *Am J Sports Med.* 2006;34(7):1181-1191.
- Loomer R, Fisher C, Lloyd-Smith R, Sisler J, Cooney T. Osteochondral lesions of the talus. *Am J Sports Med.* 1993;21(1):13-19.
- Yamamoto Y, Ishibashi Y, Tsuda E, Sato H, Toh S. Osteochondral autograft transplantation for osteochondritis dissecans of the elbow in juvenile baseball players: minimum 2-year follow-up. *Am J Sports Med.* 2006;34(5):714-720.
- Song WS, Yoo JJ, Koo KH, Yoon KS, Kim YM, Kim HJ. Subchondral fatigue fracture of the femoral head in military recruits. *J Bone Joint Surg Am.* 2004;86(9):1917-1924.
- Weaver CJ, Major NM, Garrett WE, Urbaniak JE. Femoral head osteochondral lesions in painful hips of athletes: MR imaging findings. *Am J Roentgenol.* 2002;178(4):973-977.
- Indelli PF, Nisbet JK, Taljanovic MS, Cohen R, Grana WA. Subchondral fracture of the hip caused by axial loading: a case report and review of the literature. *Am J Orthop.* 2005;34(4):198-201.
- Todd RC, Freeman MA, Pirie CJ. Isolated trabecular fatigue fractures in the femoral head. *J Bone Joint Surg Br.* 1972;54(4):723-728.
- Visuri T. Stress osteopathy of the femoral head. 10 military recruits followed for 5-11 years. *Acta Orthop Scand.* 1997;68(2):138-141.
- DeLee JC, Farney WC. Incidence of injury in Texas high school football. *Am J Sports Med.* 1992;20(5):575-578.
- Gomez E, DeLee JC, Farney WC. Incidence of injury in Texas girls' high school basketball. *Am J Sports Med.* 1996;24(5):684-687.
- Messina DF, Farney WC, DeLee JC. The incidence of injury in Texas high school basketball. A prospective study among male and female athletes. *Am J Sports Med.* 1999;27(3):294-299.
- Goldman AB, Hallel T, Salvati EM, Freiburger RH. Osteochondritis dissecans complicating Legg-Perthes disease. A report of four cases. *Radiology.* 1976;121(3):561-566.
- Kamhi E, MacEwen GD. Osteochondritis dissecans in Legg-Calve-Perthes disease. *J Bone Joint Surg Am.* 1975;57(4):506-509.
- Rowe SM, Moon ES, Yoon TR, Jung ST, Lee KB, Lee JJ. Fate of the osteochondral fragments in osteochondritis dissecans after Legg-Calve-Perthes' disease. *J Bone Joint Surg Br.* 2002;84(7):1025-1029.
- Linden B, Jonsson K, Redlund-Johnell I. Osteochondritis dissecans of the hip. *Acta Radiol.* 2003;44(7):67-71.
- Kusumi T, Ishibashi Y, Tsuda E, et al. Osteochondritis dissecans of the elbow: histopathological assessment of the articular cartilage and subchondral bone with emphasis on their damage and repair. *Pathol Int.* 2006;56(10):604-612.
- Kubo T, Yamamoto T, Inoue S, et al. Histological findings of bone marrow edema pattern on MRI in osteonecrosis of the femoral head. *J Orthop Sci.* 2000;5(5):520-523.
- Sakai T, Sugano N, Nishii T, Haraguchi K, Ochi T, Ohzono K. MR findings of necrotic lesions and the extralesional area of osteonecrosis of the femoral head. *Skeletal Radiol.* 2000;29(3):133-141.
- Edwards DJ, Lomas D, Villar RN. Diagnosis of the painful hip by magnetic resonance imaging and arthroscopy. *J Bone Joint Surg Br.* 1995;77(3):374-376.
- Kelly BT, Williams RJ 3rd, Philippon MJ. Hip arthroscopy: current indications, treatment options, and management issues. *Am J Sports Med.* 2003;31(6):1020-1037.

CALL FOR PAPERS

TIPS OF THE TRADE

We invite you to use the journal as a forum for sharing your tips with your colleagues.

All submitted manuscripts will be subject to the journal's standard review process.

Manuscripts should be submitted via an online submission system, Editorial Manager[®], at www.editorialmanager.com/AmJOrthop.

Please follow the guidelines listed in Guidelines for Authors found on our website, amjorthopedics.com.