

# Septic Trochanteric Bursitis in an Adolescent

Daoud Makki, MD, MRCS, DipSEM, and Alex James Watson, MBBS, FRCS (Orth)

## Abstract

Trochanteric bursitis, whether septic or inflammatory in origin, is a condition that affects middle-aged patients. Here we report the rare case of an adolescent with septic trochanteric bursitis (treated successfully with intravenous antibiotics), review the available literature on septic bursitis, illustrate the importance of prompt recognition and treatment of this condition in any age group, and describe the clinical presentation and the radiologic findings.

**B**ursae function as gliding mechanisms for overlying muscles and are vulnerable to inflammation and irritation from any repetitive stress caused by microtrauma or friction.

Around the greater trochanter are 3 main bursae—the subgluteus maximus, medius, and minimus. These lie close to the greater trochanter and its 4 bony facets—the anterior, lateral, posterior, and superoposterior facets.<sup>1</sup>

*Trochanteric bursitis* (or *trochanter pain syndrome*) refers to a nonspecific pain around the hip region. An inflammatory etiology is debatable, as the condition has been attributed to gluteal tendinopathy.<sup>2,3</sup>

*Septic bursitis* is usually caused by direct inoculation from a traumatic injury or by contiguous spread from cellulitis (50%-70% of cases). Other routes, bacteremia and contiguous spread from septic arthritis, are believed to be less common (10%).<sup>4</sup> Reports on infected olecranon and prepatellar bursitis suggest that *Staphylococcus aureus* is the most common causative organism (~85% of cases), followed by streptococci.<sup>5,6</sup> Other organisms, including mycobacteria (tuberculous and nontuberculous strains), *Pseudomonas aeruginosa*, and *Fusobacterium gonidiaformans*, have also been reported.<sup>4,7-10</sup>

Septic bursitis is more common in prepatellar and olec-

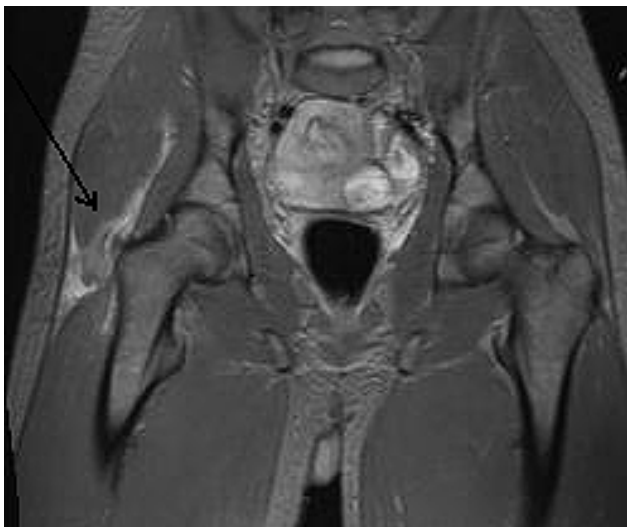ranon regions than at the hip and can be fulminant enough to cause significant systemic toxicity necessitating hospital admission.<sup>11</sup>

To our knowledge, there are no reported cases of septic trochanteric bursitis in an adolescent. In this article, we describe the clinical presentation, investigation, and management of an adolescent patient with septic trochanteric bursitis.

The authors have obtained informed written consent from the patient's guardian for print and electronic publication of the case report.

## CASE REPORT

A 15-year-old boy was brought to the hospital by ambulance with a 1-day history of severe right hip pain and inability to weight-bear. Previously, he had been generally fit and well, and he had no history of recent trauma, illness, or foreign travel. On clinical examination, he was pyrexial (38.5°C) and tachycardic (heart rate, 107 bpm). He appeared uncomfortable in bed and was trying to avoid lying on the affected hip, being held in slight flexion. There was no apparent swelling, erythema, or rash over the leg. The patient had severe tenderness over the lateral aspect of the thigh from the greater trochanter to the midhigh region and decreased range of painful hip motion (flexion, 70°; external rotation, 40°; internal rotation, 15°); the pain was elicited mainly on flexion and internal rotation of the leg. Two inguinal lymph nodes were palpable in the right

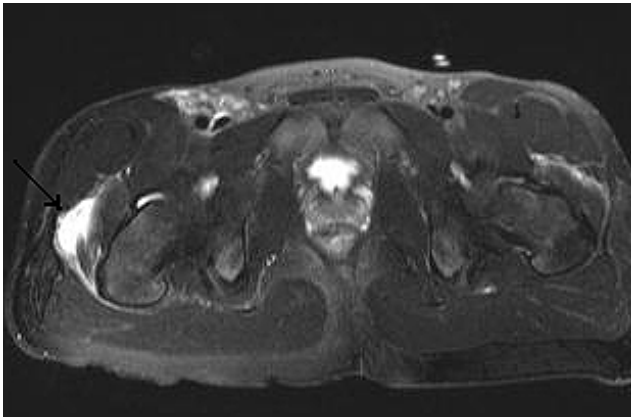


**Figure 1.** Coronal T<sub>2</sub>-weighted magnetic resonance imaging of 15-year-old male patient hips shows fluid accumulation in greater trochanteric region on right (thin arrow).

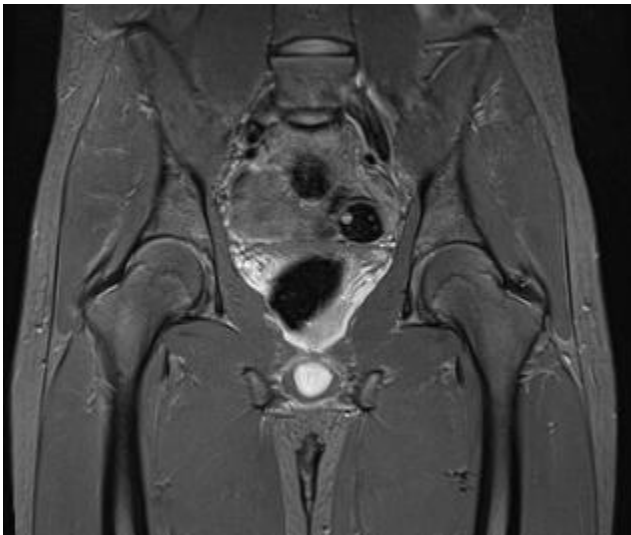
Dr. Makki is Trust Registrar, and Dr. Watson is Consultant Orthopaedic Surgeon, Department of Trauma and Orthopaedics, Princess Alexandra Hospital, Harlow, United Kingdom.

Address correspondence to: Daoud Makki, MD, MRCS, DipSEM, Department of Trauma and Orthopaedics, Tye Green Ward, Princess Alexandra Hospital, Hamstel Road, Harlow, CM20 1QX, United Kingdom (tel, 44-127-944-4455, bleep 139; mobile, 44-773-800-7238; fax, 44-127-982-7579; e-mail, daoudmakki@hotmail.com).

*Am J Orthop.* 2010;39(1):E1-E3. Copyright Quadrant HealthCom Inc. 2010. All rights reserved.



**Figure 2.** Axial T<sub>2</sub>-weighted magnetic resonance imaging of patient's hips on presentation shows effusion (thin arrow).



**Figure 3.** Coronal T<sub>2</sub>-weighted magnetic resonance imaging of patient's hips 6 months later shows almost complete resolution of effusion.

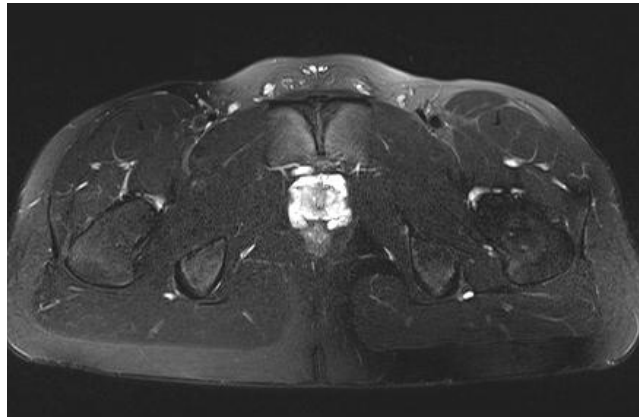groin. However, there was no distal neurovascular deficit in the leg. The other clinical assessments, including chest and abdominal examinations, were unremarkable.

C-reactive protein level was 64 nmol/L, neutrophil count was  $9.2 \times 10^9/L$ , urinalysis excluded any urinary tract infection or hematuria, and radiographs of the chest and pelvis were normal.

An urgent ultrasound scan of the hip revealed no effusion within the hip joint but rather a fluid collection in the trochanteric region. As the patient was stable enough, urgent magnetic resonance imaging (MRI) was performed (Figures 1, 2). MRI confirmed the presence of effusion in the greater trochanter region along with inguinal lymph nodes.

MRI interpretation led to the diagnosis of septic trochanteric bursitis, and treatment was started with intravenous flucloxacillin and benzylpenicillin according to our policy for the treatment of soft-tissue infections. In addition, the patient received oral anti-inflammatory drugs.

A surgical drainage was to be considered if the patient



**Figure 4.** Axial T<sub>2</sub>-weighted magnetic resonance imaging of patient's hips 6 months later shows almost complete resolution of effusion.

did not improve after the initial medical treatment. However the patient made a marked recovery within 12 hours after admission, and the surgery was deferred. Over the next 5 days, he made further satisfactory recovery, with a noticeable improvement in the hip pain, and was able to mobilize full weight-bearing. The results of the blood cultures taken at admission confirmed the presence of *S aureus* sensitive to the antibiotics he had been prescribed.

The patient was discharged home on day 7 with 1 week of oral antibiotics and arrangements for outpatient follow-up. On subsequent review, he was noted to progress satisfactorily but had residual discomfort in the right hip region. Several months later, however, the hip pain was noted to be increased after sporting activities, and he was advised to reduce his amount of training and sport.

At 6 months, the patient was still having hip pain after exercise. MRI showed almost complete resolution of the original trochanteric bursitis; there remained a small amount of soft-tissue edema in the greater trochanter region (Figures 3, 4).

Possibly unrelated to the original problem, this patient was also investigated for concurrent blackouts. An echocardiogram was suggestive of mitral valve thickening. Our consultant cardiologist's opinion was that this was either a normal entity for his age or evidence of a previous onset of endocarditis.

## DISCUSSION

Trochanteric bursitis, whether or not septic in origin, is more common in middle-aged women but has been reported in other age groups.<sup>3,12,13</sup>

Cases of infective trochanteric bursitis in middle-aged patients were reported as being caused by hematologic spread or after hip arthroplasty.<sup>14</sup> In children (mean age, 9 years), septic bursitis was found to occur commonly in the olecranon, prepatellar, and subacromial bursae.<sup>15</sup>

Although *S aureus* is the most common microorganism involved in septic bursitis,<sup>4,14</sup> the other organisms (tuberculosis, *P aeruginosa*, etc) have been reported more often in the trochanteric bursa.<sup>7-10</sup>

Gómez-Rodríguez and colleagues<sup>6</sup> reviewed 40 cases of septic bursitis and found that prepatellar bursitis acted in an aggressive clinical manner. In the case of our adolescent patient, clinical, biochemical, and radiologic findings supported a diagnosis of septic trochanteric bursitis, which was successfully treated with intravenous antibiotics—no need for incision and drainage.

That our patient was still having atypical pain in the trochanteric region after sport activities suggests he might have acquired greater trochanteric pain syndrome after the acute episode of septic trochanteric bursitis. If true, it may have been caused by scarring in the soft tissues or gluteal muscles.

The mitral valve thickening noted on echocardiogram may have resulted from endocarditis, which may have been the cause or the result of septic trochanteric bursitis. Rheumatologic manifestations can occur in association with infective endocarditis and have been reported, usually in men in their 50s; these manifestations can take the form of sacroiliitis, discitis, monoarthritis, and trochanteric bursitis.<sup>16</sup>

We conclude that septic trochanteric bursitis is not age related. Although a diagnosis of septic arthritis should be excluded first in adolescents or children presenting with hip pain and pyrexia, septic trochanteric bursitis should be added to the list of differential diagnoses in this age group. Its clinical presentation can be fulminant and serious. When bacteremia is present, other coexisting septic foci should also be investigated. Empirical antibiotics should be commenced immediately if the patient is unwell, and, if the patient is stable, investigations such as ultrasound and MRI can help in reaching the diagnosis. Surgical drainage may be considered in cases in which there is no response to antibiotherapy along with presence of a defined collection identified on MRI or ultrasound scan.

## AUTHORS' DISCLOSURE STATEMENT

The authors report no actual or potential conflict of interest in relation to this article.

## REFERENCES

1. Pfirrmann CW, Chung CB, Theumann NH, Trudell DJ, Resnick D. Greater trochanter of the hip: attachment of the abductor mechanism and a complex of three bursae—MR imaging and MR bursography in cadavers and MR imaging in asymptomatic volunteers. *Radiology*. 2001;221(2):469-477.
2. Silva F, Adams T, Feinstein J, Arroyo RA. Trochanteric bursitis: refuting the myth of inflammation. *J Clin Rheumatol*. 2008;14(2):82-86.
3. Kong A, Van der Vliet A, Zadow S. MRI and US of gluteal tendinopathy in greater trochanter pain syndrome. *Eur Radiol*. 2007;17(7):1772-1783.
4. Chang E. Bursitis. Emedicine. Boston, MA: Massachusetts General Hospital. <http://emedicine.medscape.com>. Updated July 9, 2008. Accessed February 15, 2009.
5. Söderquist B, Hedström SA. Predisposing factors, bacteriology and antibiotic therapy in 35 cases of septic bursitis. *Scand J Infect Dis*. 1986;18(4):305-311.
6. Gómez-Rodríguez N, Méndez-García MJ, Ferreiro-Seoane JL, Ibáñez-Ruán J, Penelas-Cortés Bellas Y. Infectious bursitis: study of 40 cases in the pre-patellar and olecranon regions [in Spanish]. *Enferm Infecc Microbiol Clin*. 1997;15(5):237-242.
7. Haritides J, Christodoulou P, Tsakonas A. Tuberculous trochanteric bursitis. *Chir Organi Mov*. 2004;89(2):177-180.
8. Crespo M, Pigrau C, Flores X, et al. Tuberculous trochanteric bursitis: report of 5 cases and literature review. *Scand J Infect Dis*. 2004;36(8):552-558.
9. González-Gay MA, Bal M, Santiago J, López Morán MS, Pulpeiro JR. Septic trochanteric bursitis caused by *Pseudomonas aeruginosa* in a drug addict [in Spanish]. *An Med Interna*. 1994;11(4):206-207.
10. Lefebvre C, Lambert M, Bastien P, Wauters G, Nagant de Deuxchaisnes C. Septic trochanteric bursitis caused by *Fusobacterium gonidiaformans*. *J Rheumatol*. 1985;12(2):391-392.
11. Zimmermann B 3rd, Mikolich DJ, Ho G Jr. Septic bursitis. *Semin Arthritis Rheum*. 1995;24(6):391-410.
12. Cea-Pereiro JC, Garcia-Meijide J, Mera-Varela A, Gomez-Reino JJ. A comparison between septic bursitis caused by *Staphylococcus aureus* and those caused by other organisms. *Clin Rheumatol*. 2001;20(1):10-14.
13. Shbeeb MI, Matteson EL. Trochanteric bursitis (greater trochanter pain syndrome). *Mayo Clin Proc*. 1996;71(6):565-569.
14. Berquist TH, Bender CE, Maus TP, Ward EM, Rand JA. Pseudobursae: a useful finding in patients with painful hip arthroplasty. *AJR Am J Roentgenol*. 1987;148(1):103-106.
15. Paisley JW. Septic bursitis in childhood. *J Pediatr Orthop*. 1982;2(1):57-61.
16. González-Juanatey C, González-Gay MA, Llorca J, et al. Rheumatic manifestations of infective endocarditis in non-addicts. A 12-year study. *Medicine (Baltimore)*. 2001;80(1):9-19.