

Arthroscopic Excision of a Painful Bipartite Patella Fragment

Joseph Carney, MD, Darcy Thompson, MS, Joseph O'Daniel, MD, and Jeffrey Cassidy, MD

ABSTRACT

Bipartite patella is an uncommon finding, with the majority of cases discovered incidentally on radiographs. Occasionally, bipartite patella can become painful through sports activities, overuse, or following an injury, and the large majority of these cases resolve with nonoperative treatment. However, for patients who do not respond to a prolonged course of nonoperative treatment, surgical options may be considered.

We report a successful case of arthroscopic excision of a painful bipartite patella fragment in a 19-year-old male collegiate basketball player. A review of the literature is included.

A bipartite patella has an accessory ossification center that does not fuse to the primary patella. The incidence of bipartite patella has been reported to be 2%, with 50% of cases occurring bilaterally.^{1,2}

Dr. Carney is Staff Orthopaedic Surgeon, Naval Medical Center San Diego, San Diego, California.

Ms. Thompson is a medical student, UCLA David Geffen School of Medicine, Los Angeles, California.

Dr. O'Daniel is General Medical Officer, Navy Mobile Construction Battalion, Gulfport, Mississippi.

Dr. Cassidy is Staff Orthopaedic Surgeon, Helen DeVos Children's Hospital, Grand Rapids, Michigan.

Address correspondence to: Joseph Carney, MD, Naval Medical Center San Diego, Department of Orthopaedic Surgery, 34800 Bob Wilson Drive, Suite 112, San Diego, CA 92134 (email, joseph.carney@med.navy.mil).

Am J Orthop. 2010;39(1):40-43. Copyright, Quadrant HealthCom Inc. 2010. All rights reserved.

The majority of cases are asymptomatic and are discovered as incidental findings on routine radiographs. Occasionally, a bipartite patella can become painful through strenuous sports activities, overuse, or following an injury.³⁻⁶ Nonoperative treatment is effective for most cases with successful return to normal function and sports activities. However, for those patients who do not respond to

after a collision on the court in which another player's knee struck his left knee. The patient denied any twisting injury or hearing a pop at the time of the initial injury. There was no knee effusion, and he finished the game. Since the initial injury, the patient's knee pain steadily increased to the point where he was unable to participate in basketball at the same level as he did prior to the onset of

"Arthroscopic excision...allows for early and aggressive postoperative rehabilitation."

a prolonged course of conservative treatment, surgical options may be considered, including open excision of the accessory ossification center, release of the vastus lateralis attachment to the accessory ossification center alone or in combination with accessory ossification center excision, and open reduction and internal fixation of the secondary ossification center. Recently, Azarbod and colleagues⁷ reported the arthroscopic excision of a painful bipartite patella fragment with 6 weeks of follow-up.

We report a successful case of arthroscopic excision of a painful bipartite patella fragment in a 19-year-old male collegiate basketball player with 6 months of follow-up. A review of the literature is included. The authors have obtained the patient's written informed consent for print and electronic publication of the case report.

CASE REPORT

A 19-year-old male collegiate basketball player presented with the chief complaint of chronic left knee pain for 2 years. His symptoms began

his symptoms. The patient localized the pain to the lateral aspect of his patella and reported exacerbation of his knee pain with any sports activity. He denied any instability or knee swelling and reported no mechanical symptoms. The patient had no remote history of knee pain or injury. His symptoms had not improved despite multiple trials of physical therapy since the time of his injury.

The patient's physical exam revealed no effusion or obvious deformity. He was tender to palpation over the superolateral aspect of the patella, and he confirmed this area to be the source of discomfort while playing basketball. The patient's knees had symmetric and full active range of motion without pain. He had no ligamentous laxity, and his exam showed no meniscal pathology. He had normal patellar tracking during active knee extension and had a negative J sign. Medial and lateral translation of his patella was symmetric and unremarkable, and he had normal patellar tilt with patellar tilt test. He had no discernable muscle weakness but his

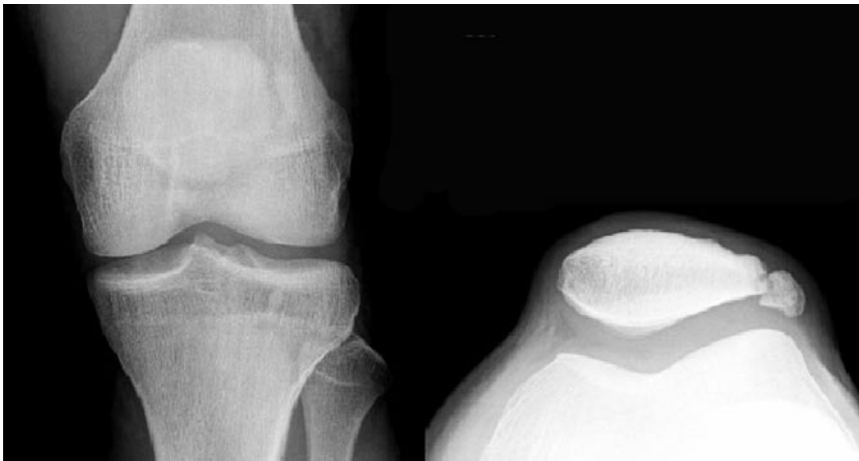

Figure 1. Preoperative radiographs reveal Saupé Type III bipartite patella.

affected leg did have mild quadriceps muscle atrophy. Radiographic examination revealed a Saupé Type III bipartite patella (Figure 1).

The patient was educated on the diagnosis of symptomatic bipartite patella, and nonoperative versus operative treatment was discussed with the patient. After discussing his options with family and coaches, the patient relayed a strong desire for surgical treatment and for an early return to collegiate basketball. He was offered arthroscopic versus open excision of the symptomatic bipartite fragment. Risks, benefits, and expected outcomes were explained, and all the patient's questions were answered. The patient acknowledged understanding the surgical options and consented to have arthroscopic excision of the bipartite patella fragment.

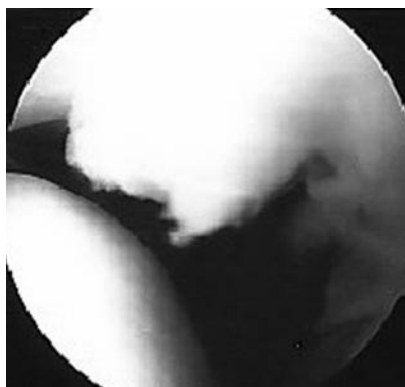


Figure 2. Arthroscopic view of step-off at patella and bipartite fragment interface.

A left knee arthroscopy with excision of the bipartite fragment was performed through standard anteromedial, anterolateral, and superolateral portals. During the diagnostic part of the procedure, no meniscal, ligamentous, or cartilage pathology was identified. Upon completion of the diagnostic arthroscopy, the bipartite patella was visualized through the arthroscope and a step-off at the junction of the patella and the bipartite segment was appreciated (Figure 2). This segment was mobile with palpation using a probe. A curved underwater Bovie was used to perform a release of the vastus lateralis along the border of the bipartite patellar fragment (Figure 3). Once lateral release around the fragment was complete, an elevator was used to further mobilize the fragment. An aggressive arthroscopic shaver was then used to entirely excise the

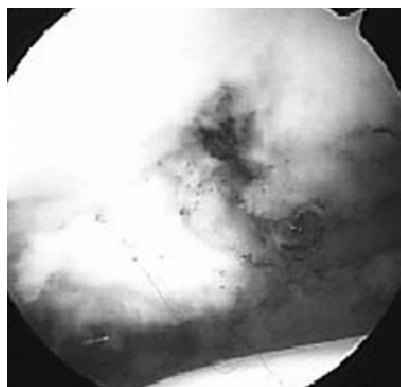


Figure 3. Arthroscopic view of vastus release.

bipartite patella fragment (Figure 4). Once the bipartite segment was completely removed, fibrocartilagenous tissue was cleared from the previous junction of the bipartite patella and the normal-appearing patella using a combination of arthroscopic shaver and thermal energy. The arthroscopic portals were closed with sutures, and a sterile bandage and knee immobilizer were applied. The patient was instructed to keep the immobilizer on full-time until his follow-up appointment.

The patient's postoperative course was uneventful. Sutures were removed at his first postoperative visit 10 days after surgery, and he began passive and active range of motion exercises as tolerated. A physical therapy consultation was ordered to assist in his rehabilitation. Six weeks after surgery, the patient had well-healed arthroscopic portal incisions around the left knee and only mild tenderness to palpation along the lateral patella. No effusion was present. The patient's patellar tracking and mobility were symmetric, and he retained symmetric full flexion and extension of his knees. At this point, the patient was instructed to continue aggressive physical therapy and return to sporting activities as tolerated.

Six months after surgery, the patient reported complete resolution of his symptoms and denied any weakness. He reported that his strength and level of play were identical to presymptom levels. The patient denied any difficulties with cutting and jumping

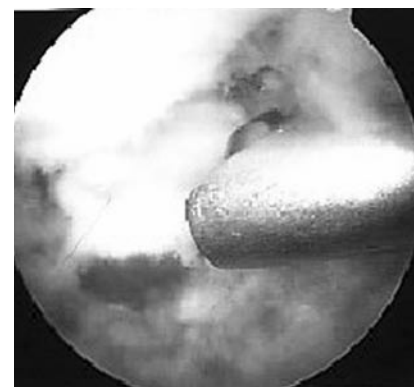


Figure 4. Excision of bipartite fragment using arthroscopic shaver.

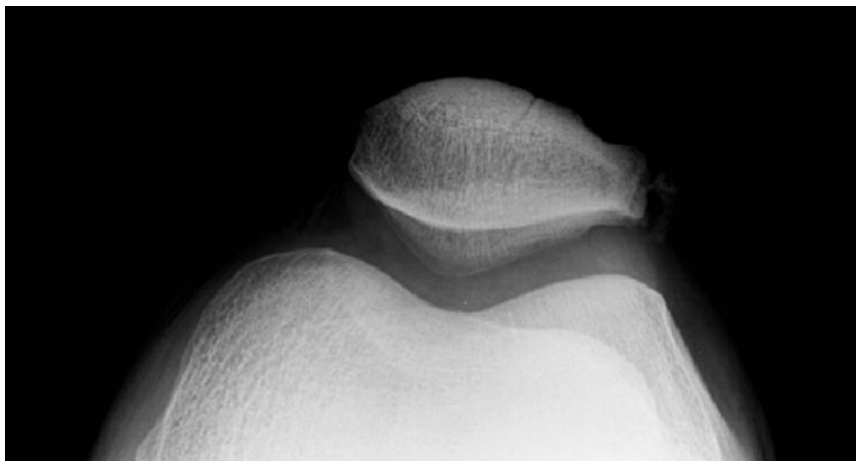


Figure 5. Radiograph at 6-month follow-up shows excision of accessory ossification center.

activities and stated that his jumping ability had returned to his presymptom level. His exam showed no tenderness to palpation and no obvious quadriceps atrophy. Radiographic analysis at 6-month follow-up was consistent with successful excision of the accessory ossification center of the patella (Figure 5).

DISCUSSION

The patella is the largest sesamoid bone in the human body and develops from a cartilaginous anlage that ossifies at age 4–6 years. In 77% of children, the patella ossifies from one center. In the other 23%, the patella ossifies from 2 or 3 centers.⁸ The secondary centers of ossification occur around age 12, and most secondary centers fuse with the main patella during adolescence; however, approximately 2% of these secondary ossification centers do not fuse with the main patella.^{8–10} The majority of secondary ossification centers are located at the superolateral pole.^{3,11,12} Saupé¹³ proposed a classification system for bipartite patella based on the position of accessory ossification center with Type I at the inferior pole (5%), Type II at the lateral margin (20%) and Type III at the superolateral pole (75%) (Figure 6).

Fibrocartilaginous tissue remains between the accessory and main patella, and, sometimes, repetitive stresses on the cartilage from sports activities and overuse or direct trauma

from an injury manifests as knee pain.^{3–6} The cause of pain in these patients is thought to be mobility in the synchondrosis between the accessory fragment and the main patella.^{3,6} Reports of a thickened vastus lateralis tendon attached to the painful fragment suggest that symptoms are part of a response to tensile force trauma to the cartilage tissue interposed between patella fragments.

The pain associated with symptomatic bipartite patella usually presents in one of two ways: gradual onset during activity or sudden onset after injury. The pain is usually localized to the anterior knee, and, in most patients, it can be further localized to the area of the accessory patella fragment. Pain tends to increase with exercise and often interferes with activity. Examination of the knee is usually significant for a tender patellar fragment with palpation. Effusions are rare and if present should raise suspicion for concomitant intraarticular injury from a traumatic episode. In patients with long-standing symptoms, quadriceps atrophy is usually present because the patient tends to self-limit to avoid painful symptoms. Range of motion tends not to be limited, but active extension of the knee may be limited owing to pain at the accessory ossification site.

Routine standard radiographs are not useful in distinguishing asymptomatic and symptomatic variants of bipartite patella. In the symptom-

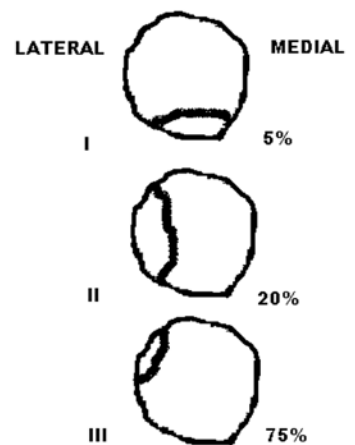


Figure 6. Saupé classification system of bipartite patella.

atic bipartite patella patient, skyline radiographic views taken with the patient in a squatting position with weight bearing may show a wider separation of the accessory fragment from the patella than the non-weight-bearing views, but this “squatting position test” is somewhat difficult to perform.¹⁴ Ultrasound has been described as a useful tool to diagnose bipartite patella but its effectiveness in evaluating a symptomatic bipartite patella has not been established.¹⁵ Bone scan may demonstrate an increased uptake at the superolateral pole of the patella. Magnetic resonance imaging findings can provide very helpful diagnostic information by demonstrating bone marrow edema within both adjacent fragments of the patella on fluid-sensitive sequences.

In most cases of painful bipartite patella, nonoperative treatment is effective with successful return to normal function and sports activities. Nonoperative treatment may include activity modifications, immobilization, nonsteroidal anti-inflammatory medications, and local steroid injections. Indications for surgery are not well defined and may include a limited response to nonsurgical treatment over 3 months combined with a decrease in activity tolerance.¹⁴ Surgical options include open excision of the accessory ossification center, release of the vastus lateralis attachment to the accessory ossifica-

tion center alone or in combination with accessory ossification excision, or open reduction and internal fixation of a large secondary ossification center. Multiple authors have described a predictably successful postoperative course and recovery with excision of the accessory fragment.^{3,6,10,14,16-18} Adachi and colleagues¹⁹ and Mori and colleagues²⁰ have reported successful treatment with release of the vastus lateralis attachment to the accessory ossification center alone and promote this procedure as a less invasive alternative to excision of the fragment. Ogata²¹ has also reported success with vastus lateralis attachment release alone but advocates excision of the fragment if it is found to be grossly mobile at time of surgery.

More recently, Azarbod and colleagues⁷ reported the arthroscopic excision of a painful bipartite patella fragment. In their case report of a 26-year-old man with a Saupé Type III bipartite patella, the patient made a full recovery and was pain free 6 weeks after arthroscopic excision. Azarbod and colleagues⁷ suggested that arthroscopic excision of the accessory fragment eliminates some of the long-term theoretical problems of open procedures, such as quadriceps weakness and subsequent muscle wasting. Furthermore, the authors postulated that arthroscopic excision expedites recovery and allows for more aggressive postoperative rehabilitation. The report by Azarbod and colleagues⁷ is the only one of arthroscopic excision of the patella accessory fragment that the authors are aware of and only offers 6 weeks of follow-up in a patient who does not compete in a high-level sports activity.

Our case adds to the literature on arthroscopic excision of painful bipartite patella in high-level ath-

letes. The 6-month postsurgical exam and radiographs reported in this case provide the longest documented follow-up that the authors are aware of for the procedure described. Furthermore, our patient competed in basketball, a demanding jumping sport, at the collegiate level and was able to return to his sport at the same level of function that he performed at before his symptoms began. This result offers valuable insight into the ability of arthroscopic excision of painful bipartite patella to achieve a successful pain-free outcome without compromise of quadriceps strength.

CONCLUSIONS

Arthroscopic excision of a painful bipartite patella accessory ossification center is a less invasive surgical method than open procedures and allows for early and aggressive postoperative rehabilitation. In our case, the procedure successfully eliminated a collegiate basketball player's painful bipartite patella symptoms and allowed him to quickly return to his sport at the same level of function that he performed at prior to onset of symptoms. The authors conclude that arthroscopic excision of a painful bipartite patella is an acceptable first choice for surgical treatment in athletes wishing for relief of their painful bipartite symptoms with a chance for early return to play.

AUTHORS' DISCLOSURE STATEMENT

The authors report no actual or potential conflict of interest in relation to this article.

The views expressed in this article are those of the authors and do not reflect the official policy or position of the Department of the Navy, Department of Defense, or the United States Government.

REFERENCES

- George R. Bilateral bipartite patellae. *Br J Surg*. 1935;22:555-560.
- Insall J. Current concepts review: patellar pain. *J Bone Joint Surg Am*. 1982;64(1):147-152.
- Ogden JA, McCarthy SM, Jokl P. The painful bipartite patella. *J Pediatr Orthop*. 1982;2(3):263-269.
- Iossifidis A, Brueton RN. Painful bipartite patella following injury. *Injury*. 1995;26(3):175-176.
- Canizares GH, Selesnick FH. Bipartite patella fracture: a case report. *Arthroscopy*. 2003;19(2):215-217.
- Weaver JK. Bipartite patellae as a cause of disability in the athlete. *Am J Sports Med*. 1977;5(4):137-143.
- Azarbod P, Agar G, Patel V. Arthroscopic excision of a painful bipartite patella fragment: a case report. *Arthroscopy*. 2005;21(8):1006.
- Carter SR. Traumatic separation of a bipartite patella. *Injury*. 1989;20(4):244.
- Rask BP, Micheli LJ. The pediatric knee. In: Scott WN, ed. *The Knee*. St. Louis: Mosby Company;1994:229-275.
- Bourne MH, Bianco AJ Jr. Bipartite patella in the adolescent: results of surgical excision. *J Pediatr Orthop*. 1990;10(1):69-73.
- Coonce DF, Pinstein M, Scott R. Radiology case of the month: bipartite patella. *J Tenn Med Assoc*. 1980;73(9):655-656.
- Medlar RC, Lyne ED. Sinding-Larsen-Johansson disease. Its etiology and natural history. *J Bone Joint Surg Am*. 1978;60(8):1113-1116.
- Saupé H. Primäre Knochenmark seilerung der Kniescheibe. *Deutsch Z Chir*. 1943;258:386.
- Ishikawa H, Sakurai A, Hirata S, Ohno O, Kita K, Sato T, Kashiwagi D. Painful bipartite patella in young athletes. The diagnostic value of skyline views taken in squatting position and the results of surgical excision. *Clin Orthop*. 1994;(305):223-238.
- Blankstein A, Cohen I, Salai M, Diamant L, Chechick A, Ganel A. Ultrasonography: an imaging modality enabling the diagnosis of bipartite patella. *Knee Surg Sports Traumatol Arthrosc*. 2001;9(4):221-224.
- Eberhard P, Manueddu C, Hoffmeyer P, Vasey H. Progressive fragmentation of a bipartite patella: apropos of a case. *Rev Chir Orthop Reparatrice Appar Mot*. 1995;81(1):78-80.
- Green WT Jr. Painful bipartite patellae: A report of three cases. *Clin Orthop*. 1975;(110):197-200.
- Halpern AA, Hewitt O. Painful medial bipartite patellae: a case report. *Clin Orthop*. 1978;(134):180-181.
- Adachi N, Ochi M, Yamaguchi H, Uchio Y, Kuriwaka M. Vastus lateralis release for painful bipartite patella. *Arthroscopy*. 2002;18(4):404-411.
- Mori Y, Okumo H, Iketani H, Kuroki Y. Efficacy of lateral retinacular release for painful bipartite patella. *Am J Sports Med*. 1995;23(1):13-18.
- Ogata K. Painful bipartite patella. A new approach to operative treatment. *J Bone Joint Surg Am*. 1994;76(4):573-57.