

Advanced Shoulder Joint Tuberculosis Treated With Débridement and Closed Continuous Irrigation and Suction: A Report of Two Cases

Kiyohisa Ogawa, MD, and Noriaki Nakamichi, MD

ABSTRACT

Tuberculosis of the shoulder is rare and its diagnosis is likely to be delayed because its symptoms often resemble those of the primary frozen shoulder or rotator cuff syndrome. The standard treatment is principally antituberculous chemotherapy plus débridement, if necessary.

In this report, we describe 2 patients with advanced shoulder joint tuberculosis that were treated by débridement and closed continuous irrigation and suction using normal saline followed by early range-of-motion exercise with satisfactory results. We emphasize that surgical débridement and closed continuous irrigation and suction, which is one of the standard treatment methods for severe or chronic musculoskeletal infection, should be considered in treating advanced shoulder joint tuberculosis.

Approximately 1% to 3% of all tuberculosis involves bone and joints.¹ Among bone and joint tuberculosis cases, shoulder involvement is rare,²⁻⁵ and its diagnosis is likely to be delayed because symptoms often resemble those of shoulder peri-arthritis or rotator cuff syndrome.⁶ Standard treatment is mainly antituberculous chemotherapy plus, if required, débridement.¹⁻³

In this article, we describe 2 patients with advanced shoulder joint tuberculosis treated with débridement and then closed continuous irrigation and suction concomitant with early range-of-motion exercise. The authors have obtained written informed consent from both patients for print and electronic publication of their case reports.

Dr. Ogawa is Consultant, Sports Clinic, School of Medicine, and Dr. Nakamichi is Surgeon, Department of Orthopedic Surgery, School of Medicine, Keio University, Shinjuku, Tokyo, Japan.

Address correspondence to: Kiyohisa Ogawa, MD, Sports Clinic, School of Medicine, and Noriaki Nakamichi, MD, Department of Orthopedic Surgery, School of Medicine, Keio University, 35 Shinanomachi, Shinjuku, Tokyo 160-8582, Japan.

Am J Orthop. 2010;39(2):E15-E18. Copyright Quadrant HealthCom Inc. 2010. All rights reserved.

CASE REPORTS

Case 1

A woman in her mid-40s in good general health presented with pain and gradually progressing (20 months) contracture of the left shoulder. At another clinic, she had been conservatively treated for peri-arthritis but without any degree of recovery. One month before presentation, a mass had appeared on the anterior shoulder and began enlarging gradually. When the pain worsened after steroid injection to the shoulder joint, she was referred to us.

From the left anterior deltoid to the anterior axilla, we found an elastic mass with no local warmth, tenderness, or erythema. The *active* mobility of the shoulder was severely restricted to 40° in elevation, 15° in external rotation, and L4 in internal rotation. Family and medical histories were unremarkable, and there were no socioeconomic problems or exposure to tuberculosis. Radiography and computed tomography (CT) showed multiple erosive lesions on the humeral head and glenoid with necrotic bone (Figure 1A). Magnetic

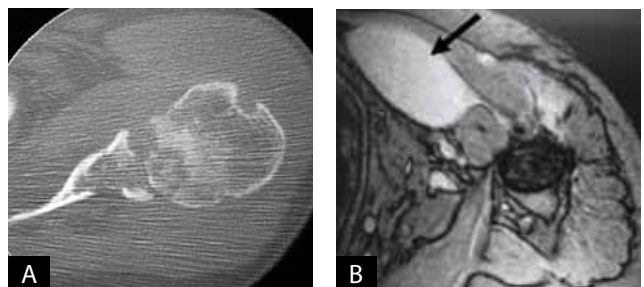


Figure 1. Case 1 imaging. (A) Preoperative computed tomography shows multiple erosive lesions with segmental necrotic bones in humeral head and severely destroyed glenoid. (B) Preoperative magnetic resonance imaging shows large cyst with effusion beneath pectoralis major (arrow). (C) Ten-year follow-up radiograph shows deformed humeral head and glenoid with sclerotic margin.

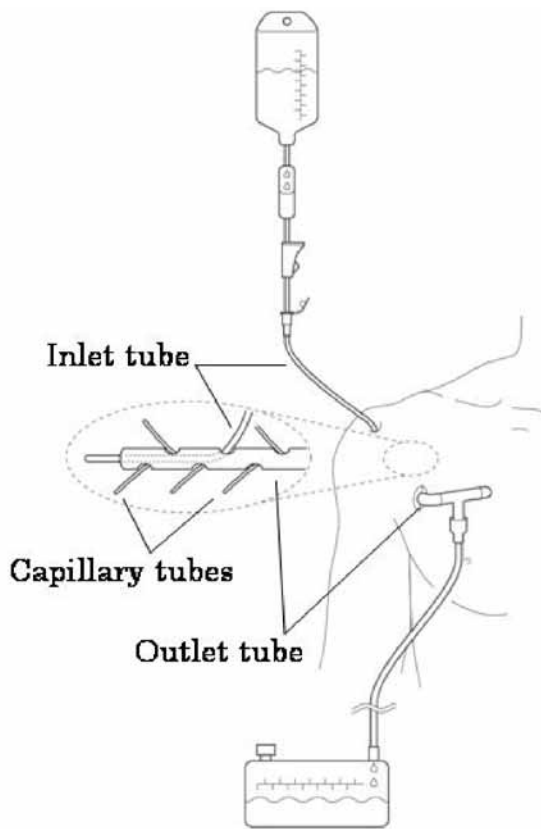


Figure 2. Irrigation system developed by Dr. Hamano. It works as siphon to produce constant, gentle suction. Close-up in circle highlights lesion or joint area where inlet tube passes through side hole on outlet tube. Capillary tubes in outlet tube secure adequate fluid flow and, if needed, clean inside of outlet tube. As system is simple and light and does not involve machinery, patients can move freely with entire system in place.

resonance imaging (MRI) showed a large effusion in the axilla (Figure 1B). Chest radiograph was normal. White blood cell count was 5600 per μL with 65% neutrophils and 28.4% lymphocytes. The Mantoux test was positive. As culturing of the joint fluid demonstrated growth of *Mycobacterium tuberculosis*, an antituberculous regimen of isoniazid, rifampin, and ethambutol was started. After the first 4 weeks of antibiotics, we initiated a 2-week regimen of débridement of the shoulder joint and abscess followed by closed continuous irrigation and suction using normal saline. Passive joint motion exercise was begun just after removal of the irrigation tube. The antituberculous chemotherapy was continued for 2 years because of a prolonged high erythrocyte sedimentation rate.

Ten years after surgery, the patient had no pain during activities of daily living (ADLs) and no infection recurrence. Active shoulder motion was 75° in elevation, 10° in external rotation, and L2 in internal rotation. Constant shoulder score ratios to the normal side were 67%.⁷ Radiography showed a deformity of the humeral head and glenoid with a sclerotic margin (Figure 1C).

Case 2

A man in his mid-50s presented with left shoulder pain of 21 months' duration. For 1 year at another hospital, he had been treated with nonsteroidal anti-inflammatory drugs and physiotherapy for shoulder peri-arthritis. He had had a discharging sinus at the upper arm and was introduced to our clinic because of persistent drainage. There were no remarkable family or medical histories, no socioeconomic problems, and no tuberculosis exposure. On examination, a sinus without inflammatory change was observed in the anterior portion of the upper arm. Active shoulder motion was severely limited to 30° in elevation, 0° in external rotation, and L4 in internal rotation. Radiography and CT showed absence of shoulder joint space, a large cystic lesion with necrotic bone, and erosive changes in the humeral head and glenoid. Culturing of the discharge fluid demonstrated *Mycobacterium tuberculosis* with subsequent antituberculous chemotherapy. Three months later, we débrided the shoulder and the sinus and then performed closed continuous irrigation and suction using normal saline. Twelve days later, the irrigation tube was removed, and passive motion exercise was started. The antituberculous chemotherapy was continued for 1 year.

Seven years after surgery, the patient had no pain during ADLs, including golf, and no infection recurrence. Active shoulder motion was 100° in elevation, 5° in external rotation, and T11 in internal rotation. Constant shoulder score ratios to the normal side were 84%.⁷ The latest radiograph showed medial migration of the humeral head and a sclerotic margin.

DISCUSSION

The incidence of tuberculosis and the extrapulmonary manifestations of the disease have increased in recent years for several reasons, including increasing global travel and immigration; an increasing number of elderly reactivated, chronically ill, or artificially immunosuppressed patients; and an increasing number of patients with acquired immunodeficiency syndrome, alcohol abuse, or intravenous drug use.¹ Approximately 10% to 11% of extrapulmonary tuberculosis involves bone and joints, accounting for 1% to 3% of all tuberculosis cases.¹ In Japan, the incidence of tuberculosis recently decreased to 22.2 cases per 100,000. Extrapulmonary tuberculosis constitutes 20% of all tuberculosis cases. Bone and joint tuberculosis comprises 7.6% of extrapulmonary tuberculosis and 1.5% of all tuberculosis, and its morbidity rate is 0.16 per 100,000.⁸ Approximately 13% of joint tuberculosis affect the upper extremities.²

In upper extremity joint tuberculosis, the shoulder lesion rate has been 16%, lower than the elbow lesion rate.² However, Garrido and colleagues⁹ investigated peripheral tuberculous arthritis and found that upper limb joint infection is far from uncommon in elderly or debilitated patients and that shoulder infection represented 62% of joint involvement in the elderly.

Primary bone and joint involvement can be difficult to diagnose in the early stages. Unawareness of the existence of this disorder and absence of distinctive signs and symptoms often lead to a considerable delay in diagnosis and treatment. In the shoulder joint, diagnosis of such an uncommon condition as tuberculosis is especially likely to be delayed, as shoulder pain of mechanical origin is quite common.⁵ Further, symptoms often resemble those of rotator cuff syndrome,⁶ or shoulder peri-arthritis (as in the 2 cases presented here), and have thus been misdiagnosed. Richter and colleagues¹⁰ reported that mean time from complaint onset to diag-

nosis was 1.6 years in 50 patients with surgically treated shoulder tuberculosis. In the case of our 2 patients, the diagnosis delays were 20 and 21 months. Prevention of unacceptable delays in diagnosis and further joint destruction requires maintaining a high index of suspicion for tuberculous arthritis.¹

“Closed continuous irrigation and suction allow for minimizing the surgical intervention and removing the resultant residual necrotic tissue and are expected to facilitate local blood flow.”

nosis was 1.6 years in 50 patients with surgically treated shoulder tuberculosis. In the case of our 2 patients, the diagnosis delays were 20 and 21 months. Prevention of unacceptable delays in diagnosis and further joint destruction requires maintaining a high index of suspicion for tuberculous arthritis.¹

A prolonged course of antituberculous drugs is the basis of treatment. Optimal duration of treatment has been an issue of considerable debate.^{3,5} Watts and Lifeso³ recommended that treatment be continued for a minimum of 12 months for osteoarticular involvement, extending to perhaps 18 months for certain problems. Although Martini and colleagues² usually found tuberculosis of the shoulder joints in an advanced stage (III or IV, according to their classification; 92%), good functional results were produced with conservative management and rehabilitation, despite the extent of joint destruction.^{2,6} In addition, they reported all their shoulder patients healed and were pain-free, though abduction was less than 60° in 3 of their 12 cases, and external rotation was invariably restricted to less than 20°.² Antti-Poika and colleagues¹¹ reported a case of shoulder tuberculosis in which disease progression caused joint destruction and secondary arthrosis despite chemotherapy. Therefore, patients who have extensive advanced lesions or who do not respond adequately to chemotherapy usually require surgical intervention, such as débridement, synovectomy, or curettage.⁴ The surgical treatment followed by 2 weeks of continuous irrigation and suction that we used is indicated after 4 weeks of appropriate antibiotics to treat advanced joint tuberculosis either with massive necrotic soft and bony tissue or with extra-articular abscess. Closed continuous irrigation and suction allow for minimizing the surgical intervention and removing the resultant residual necrotic tissue and are expected to facilitate local blood flow.

Lynch¹² applied closed continuous irrigation and suction drainage combined with débridement of caseous soft

tissue and bone to tuberculosis of the greater trochanter and reported excellent results. Closed continuous irrigation and suction now constitute one of the standard methods for treating the chronic infectious conditions of the bone and soft tissue. This method was developed by Goldman and colleagues¹³ as a means of providing artificial circulation to continuously bathe the infected bone and its surroundings in a fluid containing an adequate concentration of an antibiotic. Nemoto and colleagues¹⁴ introduced in the literature a siphon technique, developed in Japan, which produces constant gentle suction at the focus of infection. We applied this method to our 2 cases (Figure 2). Its advantages are many: Debris and pus are constantly washed out; the wound is closed, and the dead space can be minimized; local administration of antibiotics is possible; adhesion of the tissue may be reduced; and irrigation need not be performed manually or by machine.¹⁴ The value of adding topical antibiotics to the irrigation fluid, however, has been debated for many years.¹⁵ We believe that the continuous gentle suction reduces edema of the surrounding soft tissue and consequently facilitates local blood flow to increase and deliver the adequate amount of the systematically driven antituberculous drugs to the lesions. Therefore, we did not instill any antibiotic in the normal saline as the irrigation fluid.

In conclusion, we recommend that surgical débridement and closed continuous irrigation and suction using normal saline followed by early motion exercise in association with a prolonged course of antituberculous drugs should be considered in treating advanced tuberculous arthritis of the shoulder.

AUTHORS' DISCLOSURE STATEMENT

The authors report no actual or potential conflict of interest in relation to this article.

REFERENCES

1. Ohl CA. Infectious arthritis of native joints. In: Mandell GL, Bennett JE, Dolin R, eds. *Principles and Practice of Infectious Diseases*. 6th ed. Philadelphia, PA: Elsevier; 2005:1311-1322.
2. Martini M, Benkeddache Y, Medjani Y, Gottesman H. Tuberculosis of the upper limb joints. *Int Orthop*. 1986;10(1):17-23.
3. Watts HG, Lifeso RM. Tuberculosis of bones and joints. *J Bone Joint Surg Am*. 1996;78(2):288-298.
4. Wang CT, Sun JS, Hou SM. Mycobacterial infection of the upper extremities. *J Formos Med Assoc*. 2000;99(9):710-715.
5. Monach PA, Daily JP, Rodriguez-Herrera G, Solomon DH. Tuberculous osteomyelitis presenting as shoulder pain. *J Rheumatol*. 2003;30(4):851-856.
6. Skoll PJ, Hudson DA. Tuberculosis of the upper extremity. *Ann Plast Surg*. 1999;43(4):374-378.

Advanced Shoulder Joint Tuberculosis

7. Constant CR, Murley AH. A clinical method of functional assessment of the shoulder. *Clin Orthop*. 1987;(214):160-164.
8. Japan Anti-Tuberculosis Association. *Statistics of Tuberculosis 2006*. Tokyo, Japan: Japan Anti-Tuberculosis Association; 2007.
9. Garrido G, Gomez-Reino JJ, Fernández-Dapica P, Palenque E, Prieto S. A review of peripheral tuberculous arthritis. *Semin Arthritis Rheum*. 1988;18(2):142-149.
10. Richter R, Nübling W, Schulz HJ, Köhler G. Tuberculosis of the shoulder joint [in German]. *Z Orthop Ihre Grenzgeb*. 1986;124(1):36-45.
11. Antti-Poika I, Vankka E, Santavirta S, Vastamäki M. Two cases of shoulder joint tuberculosis. *Acta Orthop Scand*. 1991;62(1):81-83.
12. Lynch AF. Tuberculosis of the greater trochanter: a report of eight cases. *J Bone Joint Surg Br*. 1982;64(2):185-188.
13. Goldman MA, Johnson RK, Grossberg NM. Artificial circulation: a new approach to chronic osteomyelitis. *Orthopedics*. 1960;2(4):63-65.
14. Nemoto K, Yanagida M, Nemoto T. Closed continuous irrigation as a treatment for infection in the hand. *J Hand Surg Br*. 1993;18(6):783-789.
15. Harris PA, Nanchahal J. Closed continuous irrigation in the treatment of hand infections. *J Hand Surg Br*. 1999;24(3):328-333.