

Reconstruction of a Chronic Monteggia Fracture With Associated Radioulnar Synostosis

Jason A. Stein, MD, and Anand M. Murthi, MD

Abstract

Patients with multiple traumatic injuries can be difficult to treat, especially when a head injury is involved. In these cases, orthopedic injuries can be missed or ignored. In patients who recover, the orthopedic injuries can be more difficult to manage at a later date.

We report the case of a patient whose Monteggia fracture was unmanaged while his head injury was addressed, resulting in a malunited ulna, chronically dislocated radial head, and radioulnar synostosis.

Chronic Monteggia fractures more commonly occur in pediatric patients because of subtle ulnar fractures and because of radial head subluxation or dislocation missed in the emergency department. The literature includes many reports on how to manage these problems in the pediatric population but fewer reports on how to treat adults, particularly for injuries associated with head trauma and proximal radioulnar synostosis.

In this report, we describe the case of a 19-year-old man with a head injury and a chronic type 1 Monteggia fracture with proximal radioulnar synostosis. The authors have obtained the patient's written informed consent for print and electronic publication of the case report.

CASE REPORT

A 19-year-old man was referred to our shoulder and elbow service 2 years after a motor vehicle accident. He had been treated at an outside facility for multiple extremity injuries, including a right elbow type 1 Monteggia fracture. He had been in a coma for several months, and the right elbow fracture had been managed nonoperatively. He presented to us with a chief complaint of right elbow pain and stiffness and was unable to range

his elbow in flexion-extension or supination-pronation.

On physical examination, the patient was able to follow commands. He had intact sensation to pin prick and 2-point discrimination distally in the hand. He was able to flex and extend all digits with mild stiffness. The biceps and triceps were firing. He was able to elevate the arm 130° at the shoulder. The elbow was fixed at 40° of flexion and neutral pronation-supination. He was unable to actively or passively range the elbow. The findings of electromyography and nerve conduction studies were normal in the right upper extremity.

Radiographic examination of the elbow revealed a chronic type 1 Monteggia fracture, a proximal ulnar apex anterior malunion with an anterior radial head dislocation. Radioulnar synostosis also was observed. Extensive heterotopic ossification was present. The ulna fracture healed with approximately 30° of angulation (Figure 1).

The risks and benefits of a surgical solution were discussed with the patient and his family. We thought he would benefit from surgery because of the poor position of the arm in space and his inability to perform activities of daily living (ADLs) with that arm. We decided to perform a radial head resection to remove the mechanical block to flexion-extension and an ulnar osteotomy to correct the malalignment of the ulna to better align the radius for increased range of motion (ROM). In addition, an extensive anterior and posterior capsular release was planned.

The patient was taken to the operating room and placed supine on the operating table. The arm was

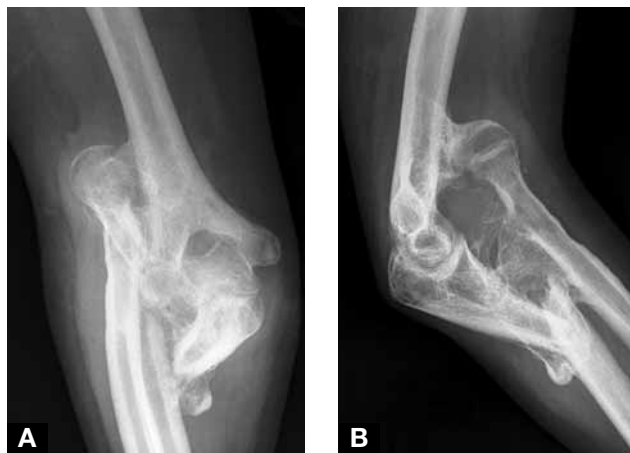

Figure 1. (A) Anteroposterior and (B) lateral radiographs at presentation show patient's chronic type 1 Monteggia fracture with 30° angulated ulnar malunion and proximal radioulnar synostosis.

Dr. Stein is Assistant Professor, Shoulder and Elbow Service, and Dr. Murthi is Assistant Professor and Chief, Shoulder and Elbow Surgery, Shoulder and Elbow Service, Department of Orthopaedics, University of Maryland School of Medicine, Baltimore, Maryland.

Address correspondence to: Anand M. Murthi, MD, Department of Orthopaedics, University of Maryland School of Medicine, 2200 Kernan Dr, Suite 1154, Baltimore, MD 21207 (tel, 410-448-6416; fax, 410-448-6387; e-mail, amurthi@umoa.umm.edu).

Am J Orthop. 2010;39(4):E36-E38. Copyright Quadrant HealthCom Inc. 2010. All rights reserved.

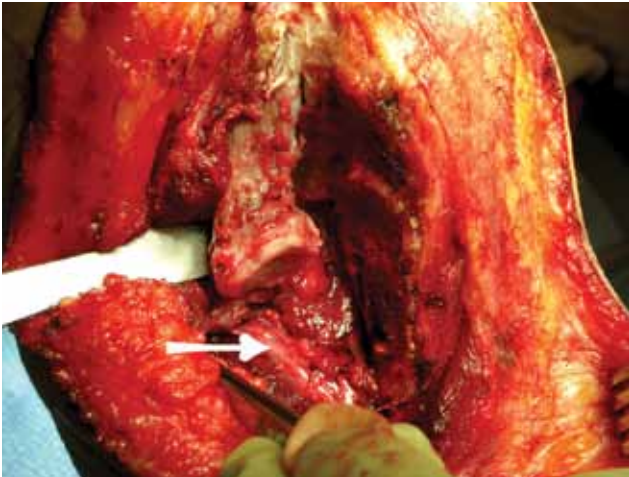


Figure 2. Surgical wound after synostosis takedown. Radial head is visible, and radial nerve is protected.

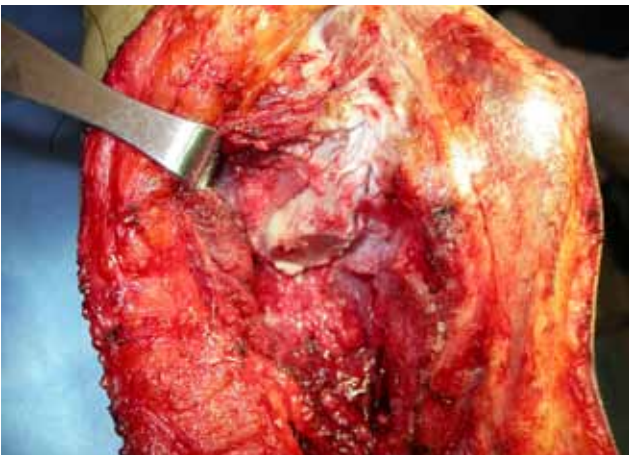

Figure 3. Radial head is resected.

prepped and draped in normal fashion, and a sterile tourniquet was applied to the arm. A posterior incision was made and carried through the subcutaneous tissue. Full-thickness skin flaps were raised medially and laterally. The lateral skin flap was developed until the brachialis muscle was identified. The brachioradialis-brachialis interval was identified. Then the radial nerve was addressed. It was identified proximally and then dissected out distally, including the posterior interosseous nerve, just distal to the elbow. The nerve was protected during the entire case (Figure 2). The extensor muscles were elevated off the lateral column, and an extensive anterior and posterior capsulectomy was performed. An osteotome was used to remove all visible heterotopic bone. The proximal radial head was then resected, and the olecranon fossa was débrided (Figure 3). The attenuated lateral collateral ligament complex was identified and protected. The radial head was completely devoid of viable cartilage. At the time of resection of the radial head, a significant increase in ROM was achieved.

The incision was extended distally over the ulnar crest, exposing the proximal ulna between the anconeus and flexor carpi ulnaris muscles. The ulnar malunion

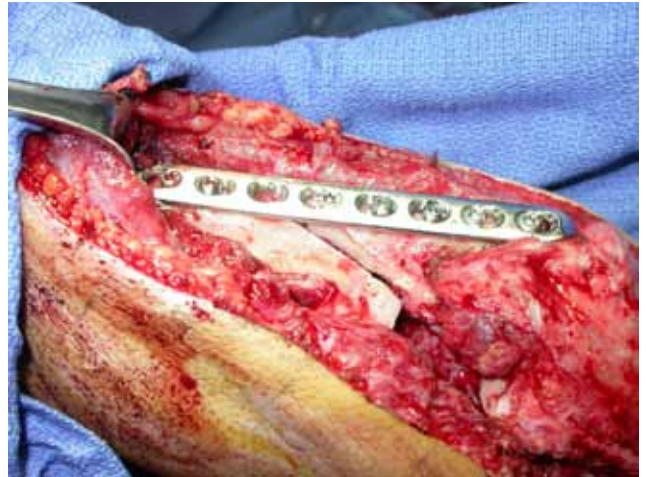


Figure 4. Ulnar malunion has been osteotomized, mobilized, and compression-plated in proper alignment.

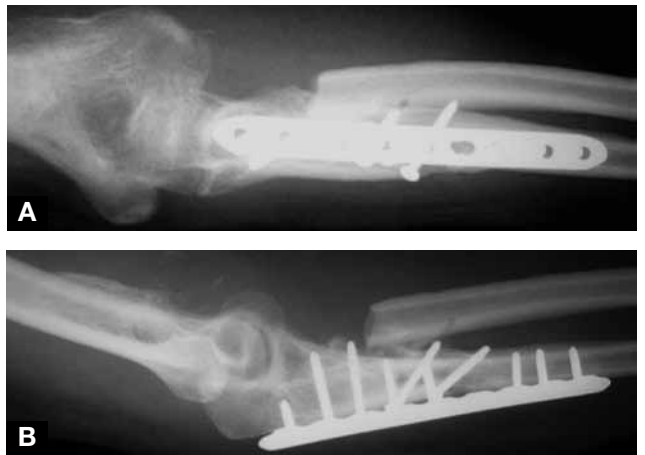

Figure 5. Final postoperative (A) anteroposterior and (B) lateral radiographs show synostosis removal, radial head resection, and realignment of forearm with ulnar osteotomy.

site was identified and mobilized with the use of a combination of osteotomes and sharp curettes. It was then aligned at the proper length and rotation and was plated in compression with local autogenous bone graft (Figure 4). This osteotomy brought the radius and ulna into proper anatomical alignment. After the incisions were closed, ROM was from full extension to 150° of flexion (Figure 5).

After surgery, the arm was placed in a well-padded anterior splint in full extension. The splint was transitioned to a nighttime extension splint, and aggressive occupational therapy, including progressive static splinting in both flexion and extension, was begun. There were no postoperative complications. The patient was given sustained-release indomethacin 75 mg for 3 weeks after surgery as prophylaxis against heterotopic ossification. At the last follow-up visit, 30 months after surgery, arc of motion was from full extension to 110° of flexion (Figure 6).

DISCUSSION

Most of the literature on chronic Monteggia fractures involves pediatric cases. For the skeletally immature,

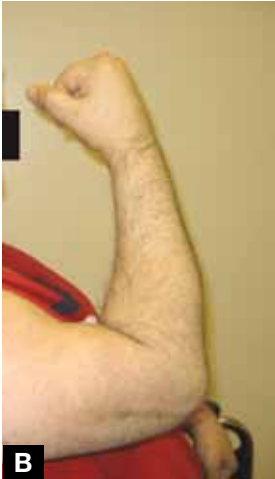
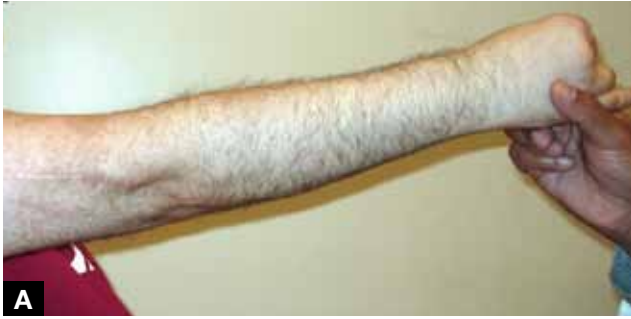
Figure 6. Clinical photographs 30 months after surgery show current arc of elbow motion from (A) extension to (B) flexion.

every attempt should be made to reduce the radial head. The radial head can be reduced up to 6 years after injury by performing a straightening ulnar osteotomy and radial shaft shortening osteotomy.¹ Other surgeons have managed these fractures with gradual lengthening of the ulna by external fixation.² In some cases, annular ligament reconstruction has assisted in the reduction of the radial head.^{3,4}

The literature on chronic Monteggia fractures in adults does not include any case reports of late reconstructions that enabled radial head reduction in the chronic setting. Our patient also had a head injury and radioulnar synostosis. There are many reports on the management of proximal forearm synostosis. Some authors have advocated interposing fat,⁵ muscle,⁶ or bone wax⁷ at the synostosis takedown site. Others have thought that interposition is not necessary.⁸

Very few of the reported cases involved patients with head injuries. Our patient had a combination of chronic radial head dislocation, ulnar malunion, and radioulnar synostosis. Motion was achieved through radial head resection, synostosis takedown, and ulna realignment concomitant with circumferential capsular release. We did not perform an interposition at the synostosis site, and no heterotopic bone reformed. We prescribed indo-

methacin as prophylaxis, which might have prevented new bone formation. Several investigators have described removal of heterotopic bone from the elbow and suggested that nonsteroidal anti-inflammatory drugs, radiation, and bisphosphonates can be effective in preventing recurrence.⁹⁻¹¹ We thought the safest way to protect our patient's skin flaps and prevent wound breakdown and infection would be to administer indomethacin. ROM increased to a level that enabled the patient to perform his ADLs and maintain that level for more than 2 years. His level of functioning without a radiocapitellar joint was more than adequate for all his ADLs.

This case nevertheless provides further evidence that physicians cannot neglect orthopedic injuries in head-injured patients. It is impossible to predict a patient's final potential, so all injuries should be appropriately managed as soon as the patient is medically stable and able to undergo orthopedic procedures.

AUTHORS' DISCLOSURE STATEMENT AND ACKNOWLEDGMENT

The authors report no actual or potential conflict of interest in relation to this article.

The authors thank Dori Kelly, MA, senior editor and writer, for expert manuscript editing and figure preparation.

REFERENCES

1. Freedman L, Luk K, Leong JC. Radial head reduction after a missed Monteggia fracture: brief report. *J Bone Joint Surg Br.* 1988;70(5):846-847.
2. Exner GU. Missed chronic anterior Monteggia lesion. Closed reduction by gradual lengthening and angulation of the ulna. *J Bone Joint Surg Br.* 2001;83(4):547-550.
3. Gyr BM, Stevens PM, Smith JT. Chronic Monteggia fractures in children: outcome after treatment with the Bell-Tawse procedure. *J Pediatr Orthop B.* 2004;13(6):402-406.
4. Hui JH, Sulaiman AR, Lee HC, Lam KS, Lee EH. Open reduction and annular ligament reconstruction with fascia of the forearm in chronic Monteggia lesions in children. *J Pediatr Orthop.* 2005;25(4):501-506.
5. Muramatsu K, Ihara K, Shigetomi M, Kimura K, Kurokawa Y, Kawai S. Posttraumatic radioulnar synostosis treated with a free vascularized fat transplant and dynamic splint: a report of two cases. *J Orthop Trauma.* 2004;18(1):48-52.
6. Bell SN, Bengler D. Management of radioulnar synostosis with mobilization, anconeus interposition, and a forearm rotation assist splint. *J Shoulder Elbow Surg.* 1999;8(6):621-624.
7. Kamineneni S, Maritz NG, Morrey BF. Proximal radial resection for posttraumatic radioulnar synostosis: a new technique to improve forearm rotation. *J Bone Joint Surg Am.* 2002;84(5):745-751.
8. Jupiter JB, Ring D. Operative treatment of post-traumatic proximal radioulnar synostosis. *J Bone Joint Surg Am.* 1998;80(2):248-257.
9. Hastings H 2nd, Graham TJ. The classification and treatment of heterotopic ossification about the elbow and forearm. *Hand Clin.* 1994;10(3):417-437.
10. Ayers DC, Everts CM, Parkinson JR. The prevention of heterotopic ossification in high-risk patients by low-dose radiation therapy after total hip arthroplasty. *J Bone Joint Surg Am.* 1986;68(9):1423-1430.
11. Cullen JP, Pellegrini VD Jr, Miller RJ, Jones JA. Treatment of traumatic radioulnar synostosis by excision and postoperative low-dose irradiation. *J Hand Surg Am.* 1994;19(3):394-401.