

Dedifferentiated Liposarcoma of Thigh With Chondrosarcomatous Dedifferentiated Component

Richard S. Yoon, BS, Joseph Benevenia, MD, Kathleen S. Beebe, MD, and Meera Hameed, MD

Abstract

Liposarcomas are common soft-tissue sarcomas arising predominantly in deep soft tissue and the retroperitoneum with varied mortality and recurrence rates, largely dependent on histologic type. Thought to arise *de novo*, liposarcomas typically are classified into 5 types based on strict morphologic characteristics: well-differentiated, dedifferentiated, myxoid, round cell, and pleomorphic. More specifically, dedifferentiated liposarcoma, a common type most prevalent in the retroperitoneum, often has 2 distinct components, a well-differentiated lipomatous component and a dedifferentiated nonlipomatous component composed of sarcomas, such as myxofibrosarcomas or other spindle-cell sarcomas. Morphology typically ranges from low- to high-grade components, most commonly exhibiting myxofibrosarcoma and malignant fibrous histiocytoma components. However, the case reported in this article is unique—the dedifferentiated component exhibited only chondrosarcomatous differentiation—and it is, to our knowledge, the first such case to be described.

Liposarcomas can be classified into 5 types (well-differentiated, dedifferentiated, myxoid, round cell, pleomorphic) based on histology.¹⁻³ The biological behavior of these types depends on histology and tumor grade.^{3,4} Well-differentiated and dedifferentiated liposarcomas commonly occur in the retroperitoneum; myxoid, round cell, and pleomorphic liposarcomas typically present in an extremity, most commonly within the thigh.⁵

Mr. Yoon is Medical Student, and Dr. Benevenia is Professor and Chairman, and Dr. Beebe is Assistant Professor, Department of Orthopaedic Surgery, University of Medicine and Dentistry of New Jersey–New Jersey Medical School, Newark, New Jersey. Dr. Hameed is Attending Pathologist, Department of Pathology, Memorial Sloan-Kettering Cancer Center, New York, New York.

Address correspondence to: Kathleen S. Beebe, MD, Division of Musculoskeletal Oncology, Department of Orthopaedics, University of Medicine and Dentistry of New Jersey–New Jersey Medical School, Suite D-1610, ACC Building, 140 Bergen St, Newark, NJ 07103 (tel, 973-792-3534; fax, 973-972-5296; e-mail, beebeka@umdnj.edu).

Am J Orthop. 2010;39(11):E114-E118. Copyright Quadrant HealthCom Inc. 2010. All rights reserved.

Dedifferentiated liposarcoma is a nonlipogenic, usually indiscernible sarcoma arising juxtaposed to a well-differentiated liposarcoma.⁴ On gross examination, these tumors show a well-differentiated component exhibiting large multinodular yellow masses, which represent less primitive, more identifiable lipomatous differentiation, with delineated solid, tan-grayish nonlipomatous, more primitive, less identifiable regions.⁴ Seemingly homogeneous, morphologic heterogeneity often is found in the dedifferentiated regions, ranging from low- to high-grade areas. These primitive regions, comprising mostly undifferentiated tumor cells composed of spindle and/or pleomorphic cells, are morphologically similar to myxofibrosarcoma and/or malignant fibrous histiocytoma and, seldom, to an identifiable cell type, such as rhabdomyosarcoma or leiomyosarcoma.⁴⁻¹¹

To our knowledge, the case described in this article is the first reported case of dedifferentiated liposarcoma with a chondrosarcomatous dedifferentiated component. The patient provided written informed consent for print and electronic publication of this case report.

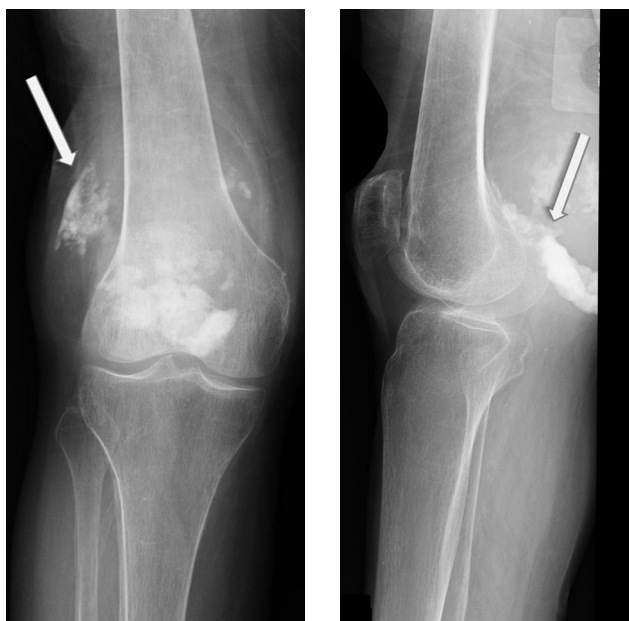

Figure 1. Anteroposterior (A) and lateral (B) radiographs of right knee show soft-tissue swelling and calcification (arrows).

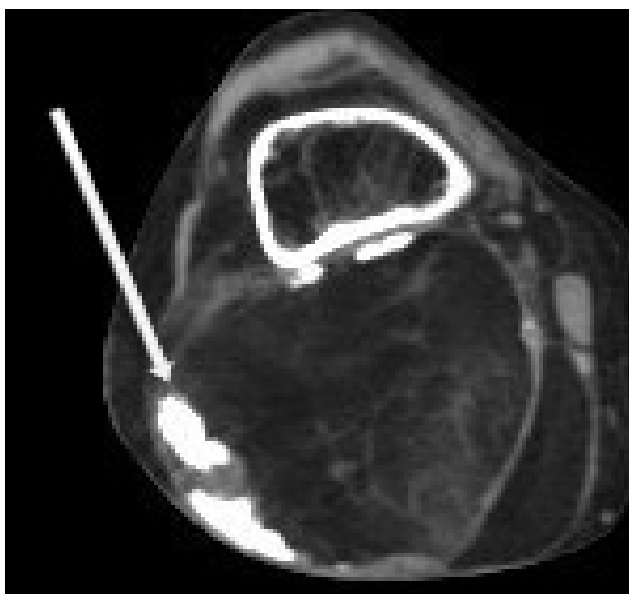


Figure 2. Axial computed tomography image shows central fat and peripheral calcification (arrow).

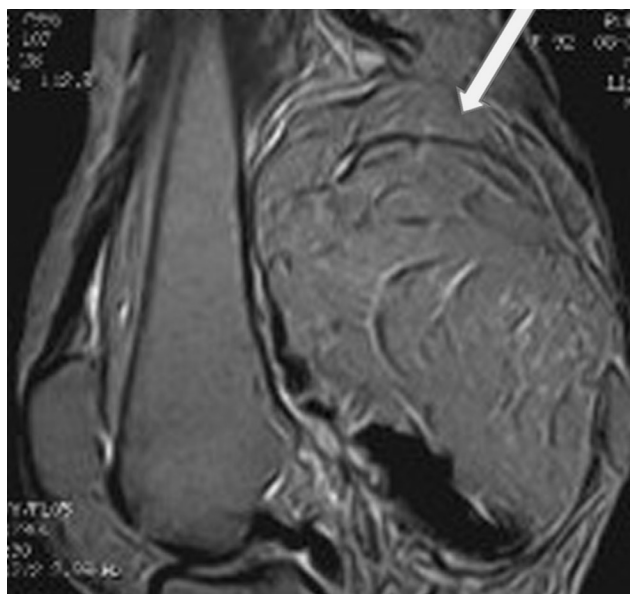


Figure 4. T₂-weighted sagittal image with gadolinium shows heterogeneous mass with septations (arrow).

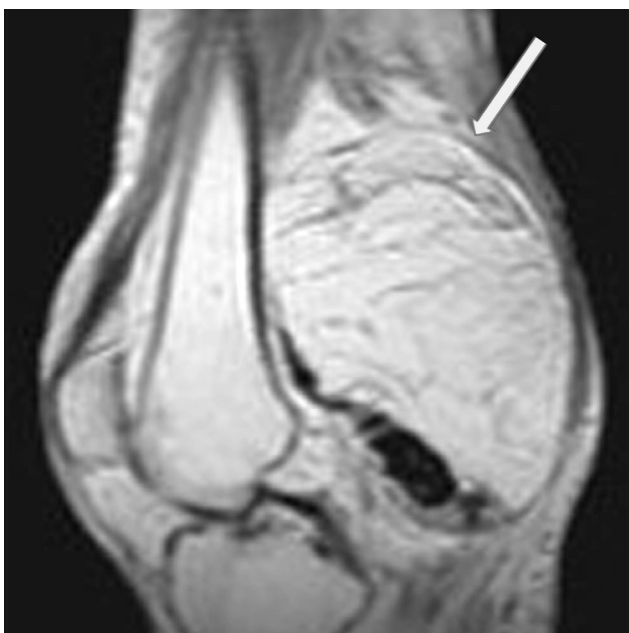

Figure 3. T₁-weighted sagittal image shows heterogeneous mass with septations (arrow).

CASE REPORT

A 92-year-old woman presented with complaints of a mass behind the right knee. She had noted the mass approximately 3 years earlier but had not sought medical counsel, as the mass had remained relatively small, allowing for uninhibited range of motion (ROM) and right limb function. In the 6 to 8 months before presentation, however, the mass had decidedly increased in size, decreasing her ROM. Furthermore, the patient's daughter had noted an "odd limp," indicating that the mother was having difficulty bringing her toes and right foot upward.

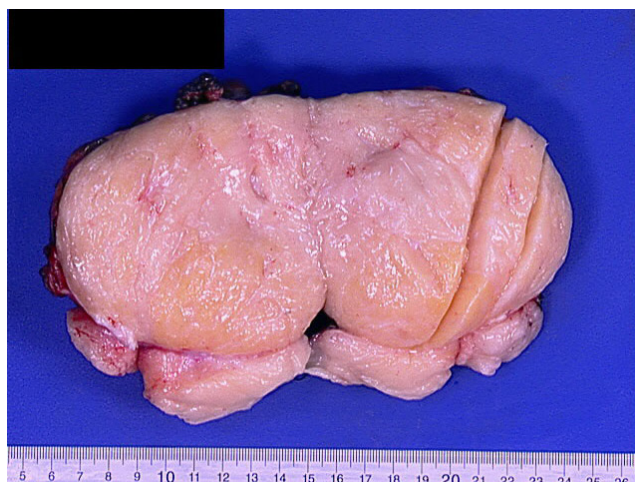


Figure 5. Gross photograph of mass with heterogeneous appearance shows yellow and pink-to-tan cut surfaces.

Patient and daughter denied any associated pain, trauma, excessive unintended weight loss, mentation change, fatigue, appetite loss, and mood changes. Of note, the patient reported having undergone surgical resection of a benign tumor at an outside institution approximately 25 years earlier (records could not be obtained). The patient denied additional cancer history, radiation therapy, and exposure to workplace or environmental toxins.

Physical examination revealed a firm, well-circumscribed mass with normal overlying integument (10×14 cm) on the posterior aspect of the right knee covering the proximal half of the popliteal fossa. Right knee ROM (active extension, 0°; active flexion, 95°) was painless. There was no tenderness on palpation of the mass or the surrounding joint. Distally, strength testing yielded significant deficits on dorsiflexion along

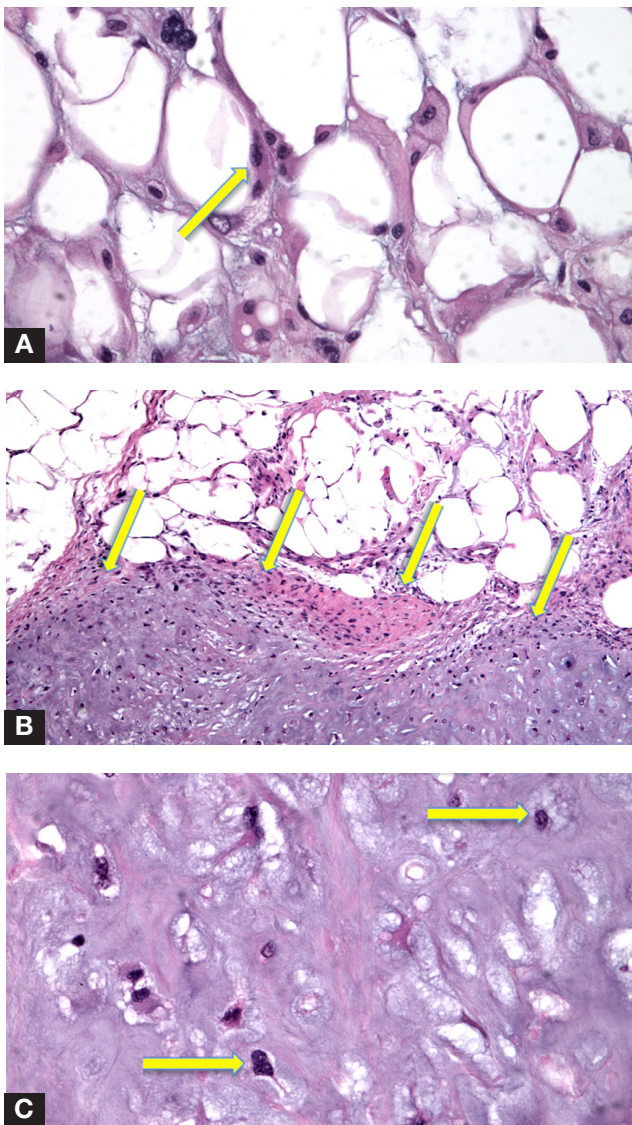


Figure 6. (A) Photomicrograph of well-differentiated liposarcoma shows lipoblasts with hyperchromatic nuclei (arrow) (hematoxylin-eosin, original magnification $\times 400$). (B) Photomicrograph of dedifferentiated liposarcoma shows abrupt transition (arrows) from well-differentiated liposarcoma to dedifferentiated chondrosarcoma (hematoxylin-eosin, original magnification $\times 200$). (C) Photomicrograph of dedifferentiated chondrosarcoma shows moderately cellular hyaline cartilage with atypical and hyperchromatic nuclei (arrows) (hematoxylin-eosin, original magnification $\times 400$).

with sensory deficits in the first dorsal web space; distal pulses were intact, but mildly diminished compared with those of the contralateral side. In addition, no appreciable lymphadenopathy was found in the inguinal or head and neck regions.

Further work-up consisted of complete blood cell count with differential, complete metabolic panel, erythrocyte sedimentation rate, core needle biopsy of mass, and diagnostic imaging, which included plain radiographs, computed tomography (CT), and magnetic resonance imaging (MRI) of the affected site. Laboratory test values were within normal limits. Imaging likely

confirmed initial suspicions of a malignant process. Opaque radiodensities consistent with calcification were seen on plain radiographs (Figures 1A, 1B) and concurrent CT (Figure 2). Magnetic resonance imaging showed, more specifically, a well-encapsulated heterogeneous mass containing internal septations measuring $10 \times 12 \times 7$ cm (Figures 3, 4). On T_1 -weighted sequences, the mass was hyperintense; on short TI inversion recovery (STIR) sequences, it was suppressed. Magnetic resonance imaging also showed the mass compressing the popliteal vessels against the femur without evidence of invasion into adjacent osseous structures. Core biopsy results indicated a pathologic diagnosis of extraskeletal chondrosarcoma arising in an infiltrating lipoma. With there being clinical, imaging, and pathologic evidence of liposarcoma, the patient was evaluated for potential metastasis. Plain chest radiography and positron emission tomography CT both showed no evidence of metastasis.

Adipose tumor was the diagnosis initially suspected, and, with core biopsy confirmation, considerations of surgical and nonsurgical management (primarily, radiation therapy) were discussed at length with the patient and her family. After extensive discussion, and weighing of the risks and benefits of both treatment options, the decision was made to perform definitive removal through wide resection with confirmed negative margins. Gross pathologic examination revealed a multilobulated mass ($12 \times 10 \times 7.5$ cm) with heterogenous areas of yellow fat and tan-pink gritty areas (Figure 5). Microscopic analysis revealed a lipomatous neoplasm composed of lipocytes of varying size and shape admixed, seldom, with lipoblasts and fibrous septae containing atypical bizarre stromal cells; there was an abrupt transition to a chondroid component that consisted of cellular cartilage with binucleated and trinucleated hyperchromatic chondrocytes scattered among calcification and osseous metaplasia (Figures 6A–6C). Karyotyping revealed supernumerary rings and marker chromosome indicative of dedifferentiated liposarcoma sharing a common

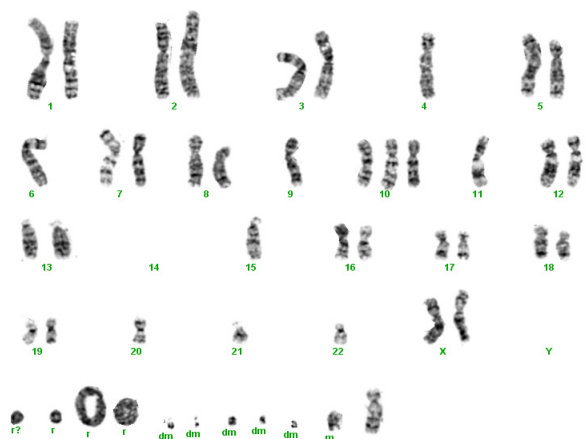


Figure 7. Photomicrograph shows female karyotype with rings (r), markers (m), and double minutes (dm).

Dedifferentiation and Dedifferentiated Liposarcoma Defined

In the early 1970s, Dahlin and Beabout¹⁹ were the first to describe dedifferentiation. They defined it as the progression of a well-differentiated neoplasm to a higher grade, more primitive cancer—a late complication within the natural course of low-grade chondrosarcomas. In 1979, Evans²⁰ reassessed that definition and coined the term *dedifferentiated liposarcoma*, which presents not as a complication but as a primary, de novo, bimorphic neoplasm with components of both a low-grade, well-differentiated liposarcoma and an entirely histologically different high-grade sarcoma. Dedifferentiated liposarcoma

is a biphasic, well-differentiated liposarcoma found with a high-grade pleomorphic sarcoma, occurring either as a primary, de novo complication or a secondary, late-stage complication.¹⁶ Henricks and colleagues¹³ analyzed 155 cases and proposed expanding the definition to include the dedifferentiated liposarcomas that also contain areas of low-grade dedifferentiation or low-percentage dedifferentiated areas, as they exhibited the same behavior as a fully malignant, high-grade sarcoma. This is the definition used today.

genetic origin (Figure 7). Also observed were double minutes, small fragments of DNA commonly found as gene amplification agents in tumor cells that afford selective advantages for tumor cell survival (ie, drug resistance). In addition, immunohistochemical studies revealed MDM2 protein positivity. Final pathologic diagnosis was dedifferentiated liposarcoma with low-grade chondrosarcomatous morphology.

Postoperative radiation was offered as adjuvant therapy but was refused by the family, who hoped to avoid further intervention and the potential complications associated with the patient's advanced age. At 17-month follow-up, the patient had full, painless ROM of the right knee with restored dorsiflexion strength and first dorsal web space distal sensation.

DISCUSSION

Soft-tissue sarcomas, which include liposarcoma and its subtypes, have a predilection to the musculoskeletal system, the retroperitoneum, and the trunk.¹² Liposarcoma most commonly is found in the retroperitoneum and the lower extremities but also can occur in the upper extremities, head and neck region, thorax, abdomen, and pelvis, albeit at lower rates of incidence.¹²⁻¹⁴

Clinically, our patient presented in a relatively classic fashion. She described a pain-free, indolent process of lower extremity swelling, eventually manifesting as a firm, nontender mass with evidence of pressure effects manifested by diminished distal strength and neurovascular status.^{2,4,15} The mass presented in a delayed, innocuous fashion, in one of the most common areas; fell within ranges of past reported tumor burden; and met diagnostic criteria for dedifferentiated liposarcoma through imaging and clinicopathoanalytic modalities.^{2,4,5,9,10,15,16} More specifically, although plain radiographs of the affected extremity showed a slight indication of a potential malignant process, they did not offer much information, certainly not the characteristic biphasic, lipogenic, nonlipogenic pattern of dedifferentiated liposarcoma noted by Hoshi and colleagues¹⁷ in a small case series. Also offering little information was the limb CT, which showed abnormal fat presence (attenuation coefficients

higher than normal adipose).^{9,16} On the other hand, MRI offered much more diagnostic information; it precisely delineated fascial planes, vessels, nerves, and bone from the actual soft-tissue mass. In addition, the mass exhibited intermediate signal on T₁ with bright signal on T₂, consistent with typical presentation of well-differentiated liposarcoma.^{6,17} Furthermore, the dedifferentiated focal nonlipomatous portions of the mass provided a non-specific appearance coupled with prolonged T₁ and T₂ relaxation times. Finally, STIR fat-suppression sequences allowed for relative confidence in a malignant liposarcoma diagnosis.^{6,17,18} Despite the confidence provided by clinical and imaging modalities, however, it was necessary to obtain preoperative diagnosis through core biopsy as well as confirmation with negative margins during resection to officially identify a dedifferentiated liposarcomatous lesion. In this patient's case, histopathologic analysis would reveal novel morphology.

Histologic analysis of our patient's resected mass revealed that it met the criteria for dedifferentiated liposarcoma (see box above) containing both well-differentiated lipocytic components and a primitive, pleomorphic chondrosarcomatous portion juxtaposed within the same mass. Important distinctions were made to ensure avoidance of erroneous diagnosis of dedifferentiated liposarcoma instead of high-grade sarcoma. Furthermore, before making the definitive diagnosis, we conducted an extensive review of the literature to ensure proper classification. On review, we found no reported cases of dedifferentiated liposarcoma with chondrosarcomatous differentiation. Evans and colleagues²¹ reported a case of dedifferentiated liposarcoma containing cartilaginous and osseous metaplasia, but this was not considered dedifferentiation because of insufficient cellularity and lack of mitotic activity around the cartilage and bone. Although our pathologic specimen consisted of some components of hyaline cartilage and bone, accompanying foci of clear-cut malignant cartilaginous areas characterized by nuclear atypia and pleomorphism indicated dedifferentiation. In addition, staining for MDM2 protein, a useful marker in identifying well-differentiated liposarcoma, was found to be

positive in both well-differentiated and dedifferentiated chondrosarcomatous foci, offering further support.²² Cytogenetic analysis indicated presence of supernumerary ring and giant marker chromosomes, again, in both well-differentiated and dedifferentiated areas, confirming diagnosis and a common genetic origin for the neoplasm in question.

Although features of our patient's case had not been reported in the literature, our treatment decisions were the standard ones considered in cases of dedifferentiated liposarcoma—surgical resection with or without adjuvant radiotherapy (chemotherapy was not discussed, simply because of its unknown efficacy on soft-tissue sarcoma).¹² Extensive discussion with the patient and her family followed, emphasizing the benefits and risks of surgical resection. Particular emphasis was placed on the patient's advanced age, and we noted increased risk for postsurgical complications, risk for recurrence, and chance of metastasis after treatment.^{4,5,23} Despite increased risks, the concurrent decision to proceed with surgical resection was made based on the notion that the tumor was deemed resectable on imaging studies with potentially obtainable wide resection margins.²³ To diminish the risk for local recurrence, adjuvant radiotherapy was offered, but it was refused by the patient and her family, citing improvement in quality of life through resection as the main goal and potential complications with radiation as undesirables. Important adherence to follow-up surveillance was agreed on, and the patient remained disease-free after 17 months.

CONCLUSIONS

We have presented the first reported account of dedifferentiated liposarcoma with chondrosarcomatous differentiation further highlighting the range of possible histologic variants that can present within the dedifferentiated portions of dedifferentiated liposarcoma. In spite of the unusual chondrosarcomatous dedifferentiated component, this tumor showed cytogenetic alterations of rings, marker chromosomes, double minutes, and MDM2 over expression similar to those of other dedifferentiated liposarcomas.

AUTHORS' DISCLOSURE STATEMENT

The authors report no actual or potential conflict of interest in relation to this article.

REFERENCES

1. Barile A, Zugaro L, Catalucci A, et al. Soft tissue liposarcoma: histological subtypes, MRI and CT findings. *Radiol Med*. 2002;104(3):140-149.
2. Springfield D. Liposarcoma. *Clin Orthop*. 1993;(289):50-57.
3. Fletcher C, Unni K, Mertens F. *Pathology and Genetics of Tumors of Soft Tissue and Bone*. Lyon, France: International Agency for Research on Cancer Press; 2002.
4. Dalal KM, Antonescu CR, Singer S. Diagnosis and management of lipomatous tumors. *J Surg Oncol*. 2008;97(4):298-313.
5. Dalal KM, Kattan MW, Antonescu CR, Brennan MF, Singer S. Subtype specific prognostic nomogram for patients with primary liposarcoma of the retroperitoneum, extremity, or trunk. *Ann Surg*. 2006;244(3):381-391.
6. Irie T, Hatori M, Watanabe M, Ehara S, Kokubun S. Radiologically and histologically mixed liposarcoma: a report of two biphasic cases. *Jpn J Clin Oncol*. 2003;33(9):482-485.
7. Karmali S, Benediktson H, Temple W, Bathe OF. A unique dedifferentiated tumor of the retroperitoneum. *World J Surg Oncol*. 2004;2:25.
8. Kind M, Stock N, Coindre JM. Histology and imaging of soft tissue sarcomas. *Eur J Radiol*. 2009;72(1):6-15.
9. Kransdorf MJ, Meis JM, Jelinek JS. Dedifferentiated liposarcoma of the extremities: imaging findings in four patients. *AJR Am J Roentgenol*. 1993;161(1):127-130.
10. Nascimento AG. Dedifferentiated liposarcoma. *Semin Diagn Pathol*. 2001;18(4):263-266.
11. Song JS, Gardner JM, Tarrant WP, et al. Dedifferentiated liposarcoma with peculiar meningeothelial-like whorling and metaplastic bone formation. *Ann Diagn Pathol*. 2009;13(4):278-284.
12. Blakely LJ, Trent JC, Patel S. Soft tissue and bone sarcomas. In: Kantarjian HM, Wolff RA, Koller CA, eds. *MD Anderson Manual of Medical Oncology*. New York, NY: McGraw-Hill; 2006:879-902.
13. Henricks WH, Chu YC, Goldblum JR, Weiss SW. Dedifferentiated liposarcoma: a clinicopathological analysis of 155 cases with a proposal for an expanded definition of dedifferentiation. *Am J Surg Pathol*. 1997;21(3):271-281.
14. Mack TM. Sarcomas and other malignancies of soft tissue, retroperitoneum, peritoneum, pleura, heart, mediastinum, and spleen. *Cancer*. 1995;75(1 suppl):211-244.
15. Reszel PA, Soule EH, Coventry MB. Liposarcoma of the extremities and limb girdles. A study of two hundred twenty-two cases. *J Bone Joint Surg Am*. 1966;48(2):229-244.
16. Weiss SW. Lipomatous tumors. *Monogr Pathol*. 1996;38:207-239.
17. Hoshi M, Matsumoto S, Manabe J, et al. Surgery for dedifferentiated liposarcoma, presenting two radiologically and pathologically distinctive patterns. *Jpn J Clin Oncol*. 2006;36(7):462-467.
18. Goffieri R, Baddeley H, Pringle JS, Souhami R. The role of the STIR sequence in magnetic resonance imaging examination of bone tumours. *Br J Radiol*. 1990;63(748):251-256.
19. Dahlin DC, Beabout JW. Dedifferentiation of low-grade chondrosarcomas. *Cancer*. 1971;28(2):461-466.
20. Evans HL. Liposarcoma: a study of 55 cases with a reassessment of its classification. *Am J Surg Pathol*. 1979;3(6):507-523.
21. Evans HL, Khurana KK, Kemp BL, Ayala AG. Heterologous elements in the dedifferentiated component of dedifferentiated liposarcoma. *Am J Surg Pathol*. 1994;18(11):1150-1157.
22. Meis-Kindblom JM, Sjögren H, Kindblom LG, et al. Cytogenetic and molecular genetic analyses of liposarcoma and its soft tissue simulators: recognition of new variants and differential diagnosis. *Virchows Arch*. 2001;439(2):141-151.
23. Mayerson JL, Schwartz HS. *OKU: Musculoskeletal Tumors 2, Surgical Management of Soft Tissue Sarcomas*. 2nd ed. Rosemont, IL: American Academy of Orthopaedic Surgeons; 2007.