

An Evaluation of Brachytherapy and External Beam Radiation Used With Wide-Margin Surgical Resection in the Treatment of Extra-abdominal Desmoid Tumors

Zain Husain, MD, Joseph Benevenia, MD, Anthony D. Ugliarolo, MD, Kathleen S. Beebe, MD, Francis R. Patterson, MD, Meera R. Hameed, MD, and Charles S. Cathcart, MD

Abstract

Surgical resection has had control rates of 53% to 77% in the treatment of extra-abdominal desmoid tumors. Surgical excision combined with external beam radiation therapy (EBRT) has had local control rates of up to 83% in some series. The purpose of this study was to evaluate the effectiveness of resection combined with radiotherapy (brachytherapy, EBRT, or both) in the treatment of extra-abdominal desmoid tumors.

We retrospectively reviewed the charts of 24 consecutive patients (27 histologically confirmed extra-abdominal desmoid tumors). Patients were included in the study if they had a lesion that was potentially resectable with a wide margin, allowing for limb salvage, and if they did not have a contraindication to radiotherapy. Limb functioning was assessed with the Musculoskeletal Tumor Society (MSTS) scoring system.

Seventeen patients (7 men, 10 women) with 19 tumors met the inclusion criteria. Mean age at diagnosis was 23.8 years. Follow-up (mean, 4.28 years) involved serial

clinical examinations and magnetic resonance imaging of tumor sites. After surgery, the tumors were treated with brachytherapy (n = 6), EBRT (n = 10), or both (n = 3). Two of the 17 tumors in patients with negative margins of resection recurred locally (local control rate, 88.2%). Mean MSTS score was 29/30 (96.7%).

The role of surgery, radiotherapy, chemotherapy, hormone therapy, and other treatments for extra-abdominal desmoid tumors is not well defined. When wide-margin resection and radiotherapy can be performed with limb preservation surgery, local control and complication rates compare favorably with those of other reported methods of treatment. Given the results and limitations of our study, we cannot make a definitive recommendation as to which modality—brachytherapy or EBRT—should be used in the treatment of extra-abdominal desmoid tumors.

Desmoid tumors are rare benign fibroblastic tumors sometimes referred to as aggressive fibromatoses, as they are characterized by aggressive local invasion into surrounding structures and high incidence of local recurrence after surgical excision. Because of their aggressiveness, they may compress local nerves and elicit pain or other neurologic symptoms that, when near joints, may limit normal motion.¹ Consequently, these tumors can result in significant functional impairment and affect quality of life.

The role of surgery, radiotherapy, chemotherapy, hormone therapy, and other treatments for extra-abdominal desmoid tumors is not well defined. There is no clear indication as to which patients may benefit from therapy after surgical removal. With its control rates of up to 77%, wide-margin surgical resection historically has been the first-line treatment for desmoid tumors.² Complete removal of these tumors is often curative, but there may be unfavorable effects on functioning and cosmesis.¹

Use of limb salvage surgery to preserve maximal functioning is complicated by tumoral infiltration of major blood vessels, nerves, bones, and joints. Underlying tissue may be spared in an attempt to preserve these important structures and prevent functional deficits, but the risk is a higher rate of recurrence.

At the time this study was conducted, Dr. Husain was Medical Student, University of Medicine and Dentistry of New Jersey-New Jersey Medical School, Newark.

Dr. Benevenia is Chair and Professor of Orthopaedic Surgery, Division of Musculoskeletal Oncology, Department of Orthopaedics, University of Medicine and Dentistry of New Jersey-New Jersey Medical School.

Dr. Ugliarolo is Surgical Resident, Lexon Hill Hospital, New York, New York.

Dr. Beebe is Assistant Professor, and Dr. Patterson is Associate Professor, of Orthopaedic Surgery, Division of Musculoskeletal Oncology, Department of Orthopaedics, University of Medicine and Dentistry of New Jersey-New Jersey Medical School.

Dr. Hameed is Attending Pathologist, Memorial Sloan-Kettering Cancer Center, New York, New York.

Dr. Cathcart is Radiation Oncologist, Newark Beth Israel Medical Center, Newark, New Jersey.

Address correspondence to: Kathleen S. Beebe, MD, Division of Musculoskeletal Oncology, Department of Orthopaedics, University of Medicine and Dentistry of New Jersey-New Jersey Medical School, 140 Bergen St, ACC Building, Suite D-1610, Newark, NJ 07103 (tel, 973-972-3534; fax, 973-972-5296; e-mail, beebeka@umdnj.edu).

Am J Orthop. 2011;40(5):E78-E82. Copyright Quadrant HealthCom Inc. 2011. All rights reserved.

Table. Patient Data and Treatment

Age, y	Sex	Anatomic Site	Presentation	Margins	Radiation, Gy	MSTS Score	Complications	Follow-up, mo
WR + BT								
16 ^a	M	Popliteal fossa	Recurrent	Negative	50.00	30	None	105.9
16 ^a	M	Ankle	Recurrent	Negative	50.00	28	None	105.9
39	F	Posterior thigh	Primary	Positive	40.92	30	None	82.9
17	F	Axilla	Primary	Negative	45.00	30	None	68.6
25 ^b	M	Posterior shoulder	Recurrent	Negative	30.00	30	None	23.1
26	M	Buttock	Primary	Negative	40.00	30	None	13.7
WR + EBRT								
24	M	Posterior thigh	Recurrent	Negative	49.60	30	None	106.2
38	F	Buttock	Primary	Negative	54.00	29	None	54.7
17	M	Anterior thigh	Primary	Positive	62.00	30	None	53.7
19	M	Flank	Primary	Negative	44.00	30	None	35.9
15	F	Back	Primary	Negative	54.00	30	None	41.6
15	F	Upper arm	Primary	Negative	50.00	30	None	65.0
13	F	Neck	Primary	Negative	45.00	30	None	5.9
54	F	Shoulder	Primary	Negative	45.00	28	None	63.9
23	M	Arm	Primary	Negative	59.40	30	None	7.2
22	F	Axilla	Primary	Negative	44.00	25	None	16.9
WR + BT + EBRT								
15	F	Back	Primary	Negative	20 (BT) 44 (EBRT)	27	Recurrence	57.8
27	F	Foot	Recurrent	Negative	15 (BT) 40 (EBRT)	27	None	34.0
24 ^b	M	Anterior chest wall	Recurrent	Negative	45 (BT) 54 (EBRT)	27	Recurrence	34.0

Abbreviations: BT, brachytherapy; EBRT, external beam radiation therapy; MSTS, Musculoskeletal Tumor Society; WR, wide-margin resection.

^aSame patient with 2 distinct tumors. ^bSame patient with 2 distinct tumors.

Often, wide-margin surgical resection is supplemented with chemotherapy or another therapy to prevent recurrence. However, response to therapy may be delayed, and the adverse systemic effects of chemotherapeutic agents have made this adjuvant therapy unpopular.

External beam radiation therapy (EBRT) has been an effective adjuvant in the treatment of desmoid tumors after resection. In cases of gross or microscopic residual disease or of recurrence, irradiation appears to improve local control.¹⁻⁴ In fact, local control rates of up to 83% have been reported for the combination of EBRT and resection.⁵ EBRT can also be used alone, in patients with unresectable tumors, the treatment of which otherwise may involve mutilating surgery, gross residual tumors, and positive margins.⁶ Although EBRT has favorable control rates, it also has limitations, including its deleterious effects on normal tissues—such as fibrosis, edema, and fracture of bone adjacent to the site of radiation exposure.

In a pivotal, 1986 study, Assad and colleagues⁷ combined surgery and brachytherapy in the treatment of extra-abdominal desmoid tumors. In brachytherapy, radiation is delivered in a high dose to a particular area and has minimal effects on other tissues. In their study, surgery combined with brachytherapy had local control rates slightly higher than those of wide-margin surgical excision combined with other modalities. To

our knowledge, few studies have revisited the efficacy of brachytherapy in the treatment of desmoid tumors. The purpose of this study was to evaluate the effectiveness of resection combined with radiotherapy (brachytherapy, EBRT, or both) in the treatment of extra-abdominal desmoid tumors.

MATERIALS AND METHODS

Using a musculoskeletal tumor database, we retrospectively identified all patients (N = 24) who presented with 1 or more extra-abdominal desmoid tumors (N = 27) to our institution between 1991 and 2008. Study inclusion criteria were a histologically proven diagnosis of extra-abdominal desmoid tumor, a potentially resectable lesion with a wide margin that allowed for limb salvage, and adjuvant treatment consisting only of radiotherapy.

We obtained institutional review board approval to conduct this study. The study's Attending Pathologist (M.R.H) reviewed the pathology of all the patients and noted tumor size, surgical margins, and other pathologic data. Additional information was obtained from perioperative medical records and office visit notes: patient demographics, treatment parameters, radiologic images, age at diagnosis, sex, site and size of lesion, dates of surgical procedures, and radiation delivery method and dose. Follow-up involved serial clinical examinations and magnetic resonance imaging of tumor sites

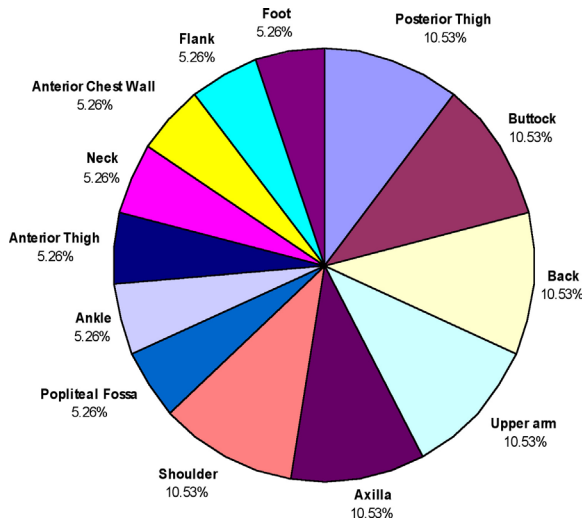


Figure. Anatomic location of desmoid tumors.

and was computed from last clinic visit. All surgical interventions involved wide-margin excision performed by 1 of 2 fellowship-trained musculoskeletal oncologists. Complete resection with negative histologic margins was intended in the management of all the patients. Radiation was initiated within 2 weeks of surgical intervention in all patients. Patients were treated with brachytherapy only, EBRT only, or both brachytherapy and EBRT. Treatment regimens were based on discussions in which the radiation oncologist and the musculoskeletal oncologist considered tumor size, anatomic location, and clinical presentation. No other chemotherapeutic agent or hormone was used initially in combination with the treatments described.

Clinical reports of complications and recurrences were noted. Recurrence and functional outcome data were obtained by reviewing the clinical examination reports and radiographs. Recurrence was defined as a pathologically diagnosed tumor appearing at the site of the initial tumor. At latest follow-up, the Musculoskeletal Tumor Society (MSTS) scoring system was used to assess the functioning of the treated extremity. This system has 6 categories: pain; extremity functioning; emotional acceptance of any residual deficit; use of mechanical supports; and, for the lower extremities, walking ability and gait. Each category is given a score from 0 (minimum) to 5 (maximum), leading to a possible total maximum score of 30.

RESULTS

We identified 24 consecutive patients (27 extra-abdominal desmoid tumors) and then excluded 7 patients (8 tumors): 3 patients with non-limb-salvageable tumors, 3 patients treated with resection but no radiotherapy, and 1 patient lost to follow-up. The remaining 17 patients (19 resectable tumors) were treated with radiotherapy (EBRT, brachytherapy, or both). There were 7 male

and 10 female patients. Mean age was 23.8 years (range, 13-54 years). Mean follow-up was 53.2 months (range, 5.9-105.9 months).

The 19 initial tumor sites (Figure) were the axilla (2), back (2), shoulder (2), posterior thigh (2), upper extremity (2), buttock (2), anterior thigh (1), foot (1), flank (1), chest (1), neck (1), ankle (1), and popliteal fossa (1). Of the 19 tumors, 18 were completely resected. The 1 tumor that could not be totally resected, because of its close proximity to the sciatic nerve, had positive margins but no recurrences.

The 19 tumor resection sites were subsequently treated with radiation therapy in one of the following treatment groups: brachytherapy only, EBRT only, and brachytherapy with EBRT.

The 5 patients (6 tumors) in the brachytherapy-only group underwent once-daily treatment with low dose rate remote afterloading iridium-192 (mean fraction dose, 42.7 Gy; median fraction dose, 43.0 Gy; range, 30.0-50.0 Gy). There were no local recurrences in this group.

The 10 patients (10 tumors) in the EBRT-only group underwent once-daily radiotherapy (mean fraction dose, 50.7 Gy; median fraction dose, 49.8 Gy; range, 44.0-62.0 Gy). There were no local recurrences in this group.

The 3 patients (3 tumors) in the brachytherapy-and-EBRT group underwent once-daily brachytherapy (mean fraction dose, 26.7 Gy; median fraction dose, 20.0 Gy; range, 15.0-45.0 Gy), followed by once-daily EBRT (mean fraction dose, 46.0 Gy; median fraction dose, 44.0 Gy; range, 40.0-54.0 Gy). There were 2 local recurrences in this group.

Of the 17 tumor resection sites with negative margins, there were 2 local recurrences (local control rate, 88.2%) over a mean follow-up of 49.4 months (Table). Both patients were treated with excision followed by brachytherapy and EBRT. One of these patients had a paraspinal desmoid tumor, and the other had a chest wall desmoid and a long history of multifocal extra-abdominal and intra-abdominal desmoid tumors.

The 19 procedures had no major postoperative complications (wound infections, delayed healing, neuritis, arthrofibrosis). The most noted minor complications were decreased range of motion (particularly in joint areas) and minor skin reactions.

At follow-up, mean overall MSTS functional score was 29/30 or 96.7% (range, 25-30). After wide-margin excision, tumors treated with brachytherapy alone had a mean MSTS functional score of 29.67 (range, 28-30), and those treated with EBRT alone had a mean MSTS functional score of 29.2 (range, 25-30). The 3 patients who underwent both brachytherapy and EBRT had a mean MSTS functional score of 27 (range, 27-27).

DISCUSSION

Desmoid tumors are locally aggressive fibromatoses. Extra-abdominal desmoid tumors are a subclass of these

broadly classified aggressive entities and are most commonly reported in the shoulder (21%); chest wall/back (17%); thigh (13%); mesentery (10%); neck (8%); and, less commonly, the knee (7%) and buttock/hip (6%).¹ Treatment often entails a multidisciplinary approach consisting of wide-margin resection followed by adjuvant treatment, such as radiotherapy or chemotherapy, to prevent recurrence. Although various adjuvant treatments have been used either individually or in combination, the optimal treatment for desmoid tumors has not been well defined.

First-line treatment for extra-abdominal desmoid tumors has been wide-margin surgical resection. Although this procedure usually removes the tumor in its entirety, it may leave the patient with significant functional impairment. These tumors tend to penetrate microscopically through local tissue, often necessitat-

significant radiation morbidity. Assad and colleagues⁷ treated 11 patients with brachytherapy using 14 implants with a median radiation dose of 45 Gy (range, 20-60.5 Gy). Each patient in our study received a radiation dose (range, 15.0-62 Gy) determined by the radiation oncologist according to the complexity of the patient's case.

Intraoperative or perioperative brachytherapy is an alternative form of radiotherapy that can be used to treat resected desmoid tumors after surgery. A close, collaborative effort between an orthopedic surgeon and a radiation oncologist is needed for precise mapping of the tumor bed for brachycatheter placement. The major advantage of brachytherapy over EBRT is the ability to deliver radiation in high doses to the tumor while minimizing its effects on adjacent, healthy tissue. In addition, EBRT requires multiple outpatient visits, whereas there is only a single admission to load the brachytherapy

“The major advantage of brachytherapy over EBRT is the ability to deliver radiation in high doses to the tumor while minimizing its effects on adjacent, healthy tissue.”

ing extensive soft-tissue resections. Several investigators have examined the effectiveness of surgical resection in desmoid tumor treatment. Five-year local control rates (local recurrence-free survival at 5 years) have ranged from 53% to 77%.^{2,8}

EBRT is often used to treat desmoid tumors after surgery. This modality is also used to treat unresectable tumors and positive margins. Several investigators have examined the effectiveness of treating extra-abdominal desmoids with EBRT alone. Nuyttens and colleagues⁴ conducted a meta-analysis of outcomes of 3 desmoid tumor treatments: surgery, EBRT, and surgery combined with EBRT. Results showed improved local control rates for the combination treatment. Patients with negative margins had local control rates of 94% with surgery plus EBRT. Individual studies have reported local control rates ranging from 72% to 83%.^{5,9} However, a serious limitation of EBRT is that it may adversely affect surrounding, healthy tissue. Radiotherapy may cause physeal growth arrest, fibrosis, edema, skin ulceration, cellulitis, neurologic changes, pathologic fracture, and secondary cancer.⁶

Radiation combined with wide-margin surgical resection may be more likely to prevent recurrence because it destroys the neoplastic cells that may remain after resection, regardless of margin status. There has been interest in determining optimal radiation doses in the treatment of desmoid tumors. So far, study results have indicated that radiation doses of 50 Gy to 60 Gy produce optimal results for local control,¹⁰ with a dose-response relationship in the range of 30 Gy to 60 Gy.⁹ However, radiation doses greater than 60 Gy have been implicated in

catheter. In addition, the rate of wound-healing complications of brachytherapy is reduced with improved techniques of wound closure and radiation dose planning standards. Use of thick, well-vascularized, tension-free skin flaps has been effective in preventing wound-healing complications.⁷

Desmoid tumors treated with a combination of surgery and brachytherapy have shown excellent local control and survival. Assad and colleagues⁷ retrospectively reviewed the cases of 14 patients whose desmoid tumors were treated with surgery and brachytherapy. Treatment was curative in 12 patients; the other 2 patients were treated palliatively. Eleven of the 12 cured patients were locally controlled, yielding a control rate of 92%, which is comparable to our control rate of 88.2%. Three patients developed wound-healing complications, which might be attributed to repeated surgical excisions, larger implanted volume, and addition of high-dose external radiation.⁷

The purpose of our study was to evaluate the effectiveness of resection combined with radiotherapy (brachytherapy, EBRT, or both) in the treatment of extra-abdominal desmoid tumors. When wide-margin resection and limb preservation were feasible and radiotherapy was used, the local control rate was 88.2%. Recurrence rates were similar for tumors treated with brachytherapy alone and tumors treated with EBRT alone (Table). Two patients in our series had a local recurrence, and in each case combination adjuvant therapy (brachytherapy and EBRT) was used. In our study population, oncologic recurrence was the only major complication.

Although margin status is the most important prognostic factor, correlating with likelihood of recurrence,

desmoid tumors often are unpredictable. Our patient with positive margins did not have a recurrence, whereas other investigators have reported significantly high rates of recurrence in patients with positive margins. Fontanesi and colleagues¹¹ studied the role of postoperative irradiation in the treatment of incompletely resected recurrent extra-abdominal desmoid tumors and concluded that use of postoperative radiation in recurrence is critical in establishing local control and that brachytherapy can be an effective option.

An important aspect of comparing the effectiveness of treatment modality is using MSTS scores to assess functional outcomes. In this study, mean MSTS scores were 29/30 (overall), 29.7 (brachytherapy only), 29.2 (EBRT only), and 27 (brachytherapy and EBRT). These scores indicate these radiotherapy regimens had similar functional outcomes—a finding not previously reported in the literature.

This study had several limitations. First, it was retrospective, so data collection and analysis depended on the quality of medical records. Second, power was limited because of the small sample size (a larger, multicenter study may be warranted). Third, patients were given different radiation doses, making analytical comparisons difficult (in the future, an optimal, standard radiation dose should be given). Fourth, we did not have enough controls for patients with different tumor sites and tumor grades. Fifth, we did not compare our local control rates with those of other treatment modalities, such as hormone therapy and chemotherapy. Future studies need to consider the risks and benefits of using these other modalities over brachytherapy and EBRT.

The role of surgery, radiotherapy, chemotherapy, hormone therapy, and other treatments for extra-abdominal desmoid tumors is not well defined. When wide-margin resection and radiotherapy can be performed with limb preservation surgery, local control and complication

rates compare favorably with those of other reported methods of treatment. Given the results and limitations of our study, we cannot make a definitive recommendation as to which modality, brachytherapy or EBRT, should be used in the treatment of extra-abdominal desmoid tumors.

AUTHORS' DISCLOSURE STATEMENT

The authors report no actual or potential conflict of interest in relation to this article.

REFERENCES

- Goy BW, Lee SP, Fu YS, Selch MT, Eilber F. Treatment results of unresected or partially resected desmoid tumors. *Am J Clin Oncol*. 1998;21(6):584-590.
- Merchant TE, Nguyen D, Walter AW, Pappo AS, Kun LE, Rao BN. Long-term results with radiation therapy for pediatric desmoid tumors. *Int J Radiat Oncol Biol Phys*. 2000;47(5):1267-1271.
- Ballo MT, Zagars GK, Pollack A. Radiation therapy in the management of desmoid tumors. *Int J Radiat Oncol Biol Phys*. 1998;42(5):1007-1014.
- Nuytens JJ, Rust PF, Thomas CR Jr, Turrisi AT 3rd. Surgery versus radiation therapy for patients with aggressive fibromatosis or desmoid tumors: a comparative review of 22 articles. *Cancer*. 2000;88(7):1517-1523.
- Spear MA, Jennings LC, Mankin HJ, et al. Individualizing management of aggressive fibromatoses. *Int J Radiat Oncol Biol Phys*. 1998;40(3):637-645.
- Hosalkar HS, Torbert JT, Fox EJ, Delaney TF, Aboulafia AJ, Lackman RD. Musculoskeletal desmoid tumors. *J Am Acad Orthop Surg*. 2008;16(4):188-198.
- Assad WA, Nori D, Hilaris BS, Shiu MH, Hajdu SI. Role of brachytherapy in the management of desmoid tumors. *Int J Radiat Oncol Biol Phys*. 1986;12(6):901-906.
- Jelinek JA, Stelzer KJ, Conrad E, et al. The efficacy of radiotherapy as postoperative treatment for desmoid tumors. *Int J Radiat Oncol Biol Phys*. 2001;50(1):121-125.
- Schmitt G, Mills EE, Levin V, Smith BJ, Boecker H, Pape H. Radiotherapy of aggressive fibromatosis. *Eur J Cancer*. 1992;28A(4-5):832-835.
- Zlotecki RA, Scarborough MT, Morris CG, et al. External beam radiotherapy for primary and adjuvant management of aggressive fibromatosis. *Int J Radiat Oncol Biol Phys*. 2002;54(1):177-181.
- Fontanesi J, Mott MP, Kraut MJ, Lucas DP, Miller PR. The role of postoperative irradiation in the treatment of locally recurrent incompletely resected extra-abdominal desmoid tumors. *Sarcoma*. 2004;8(2-3):83-86.