

Surgical Complications Associated With Extensive Tumoral Calcinosis

Joseph J. King, MD, Kristin B. Brennan, BA, Eileen A. Crawford, MD, Edward J. Fox, MD, and Christian M. Ogilvie, MD

Abstract

In this article, we describe the presenting features, radiographic appearance, and proposed pathogenesis of tumoral calcinosis; highlight the surgical complications we have encountered with the syndrome; and review the complications reported in the literature.

Tumoral calcinosis is an uncommon syndrome characterized by deposition of amorphous calcium salts and calcium hydroxyapatite crystals in soft tissues, typically around large joints. These calcium substances accumulate in the soft tissues and form masses that grow, sometimes to very large size. Surgery, at times coupled with medical management, is the principal treatment for tumoral calcinosis,^{1,2} but it comes not without difficulty and complications. Although removal of the calcified mass can relieve discomfort and mechanically improve joint function, recurrent lesions are a frequent complication of incomplete excision and usually grow more rapidly than the initial lesion.^{3,4} Specific surgical complications are only briefly mentioned in the literature.

In this article, we describe the presenting features, radiographic appearance, and proposed pathogenesis of tumoral calcinosis; highlight the surgical complications we have encountered with the syndrome; and review the complications reported in the literature.

Patients presenting with tumoral calcinosis most commonly report swelling of the affected areas with

or without associated pain.⁴⁻⁸ Results of a large study showed a slight female predominance.⁵ The syndrome more commonly presents in the first 2 decades of life but can occur at any age.^{7,9} Involvement is typically around the hip, elbow, and shoulder.^{2,4,7,10,11} Soft tissues around other joints, such as the knees, wrists, joints in hands and feet, and spine, also may be involved.^{4,7,10,12,13} These lesions can occur in the absence of vascular or visceral calcification and may infiltrate muscle and tendon,¹⁴ though the bones and joints near these lesions usually appear normal. Function is often limited in large lesions, however, which cause mechanical restriction, muscle dysfunction, and localized pain. Bony erosions have been reported but are rare.¹⁵⁻¹⁹ Unifocal lesions are more common than multifocal lesions.^{4,11}

The appearance of tumoral calcinosis on all imaging techniques is dominated by irregular, multinodular, densely calcified masses separated by fibrous septae, usually around large joints without skeletal changes.^{12,15,20} Although the calcified material is seen easily on plain radiography and computed tomography (CT), magnetic resonance imaging (MRI) is a common modality of assessment, as the masses are within the soft tissues. T₁-weighted sequences show a low signal intensity caused by the calcium deposition, fluid accumulation, and fibrosis.²¹ T₂-weighted sequences often show a heterogeneous high signal of the lesion despite the large amount of calcification.^{14,21-23} Fluid-calcium levels within the lesion may be detected on CT or MRI and are attributed to intralesional calcium sedimentation.^{15,22,24} Grossly, the masses are multilocular with prominent, traversing fibrous bands, and pockets of granular, white, paste-like fluid that are usually intramuscular or subcutaneous and may have infiltrative margins. The fibrous septae give rise to the nodular appearance on radiography.²⁰ Histologically, the lesions are composed of dense, fibrous tissue with cisterns of granular calcified material occasionally surrounded by foreign-body giant cells and a histiocytic reaction.^{7,8,10,14,25,26}

Although in most cases the exact pathogenesis of tumoral calcinosis is unknown, several disorders and genetic defects may share the common clinical feature of this syndrome.¹⁴ Smack and colleagues² described 3 disorder classifications based on serum levels of calcium and phosphorus as well as associated medical disorders.

Dr. King is Resident Physician, Department of Orthopaedic Surgery, Drexel University, Philadelphia, Pennsylvania.

Ms. Brennan is Medical Student, University of Pennsylvania School of Medicine, Philadelphia, Pennsylvania.

Dr. Crawford is Resident Physician, Department of Orthopaedic Surgery, University of Pennsylvania, Philadelphia, Pennsylvania.

Dr. Fox is Assistant Professor, Department of Orthopaedic Surgery, Pennsylvania State University, Hershey, Pennsylvania.

Dr. Ogilvie is Associate Professor, Department of Orthopaedic Surgery, University of Minnesota, Minneapolis, Minnesota.

Address correspondence to: Christian M. Ogilvie, MD, Department of Orthopaedic Surgery, University of Minnesota, 2512 South 7th Street, R200, Minneapolis, MN 55331 (tel, 612-273-8032; fax, 612-273-8038; e-mail, cogilvie@umn.edu).

Am J Orthop. 2011;40(5):247-252. Copyright Quadrant HealthCom Inc. 2011. All rights reserved.

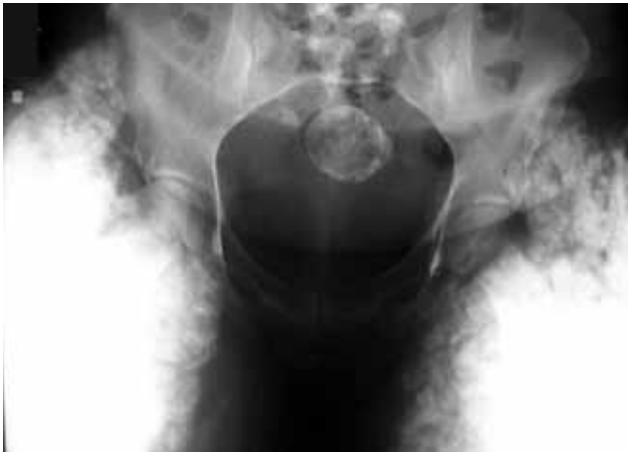

Figure 1. Plain anteroposterior radiograph of pelvis shows diffuse soft-tissue calcification in thighs bilaterally without involvement of hip joints.

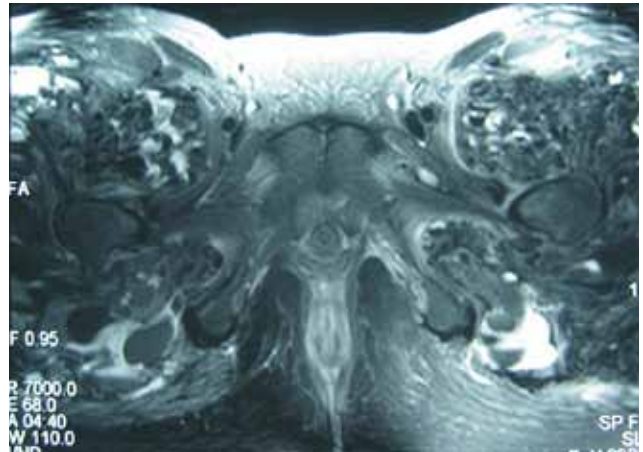


Figure 2. T₂-weighted magnetic resonance image shows diffuse calcium deposits around proximal femurs.

The first classification, primary normophosphatemic tumoral calcinosis, includes patients with normal serum calcium and phosphate levels and tumoral calcinosis with no apparent metabolic abnormality. This classification can be supported by 3 facts: More cases have been reported in tropical locations,^{5,7,27-29} a genetic predisposition has not been found,^{7,29} and these cases are more often associated with trauma.^{2,12,30}

The second classification, primary hyperphosphatemic tumoral calcinosis, includes patients with a normal serum calcium level and hyperphosphatemia. Other authors also have suggested that these patients should be classified separately, given the common clinical features,^{14,31} an apparent genetic predisposition,^{22,31} the predominance in people of African descent,¹⁴ and presence during the first and second decades of life.^{14,31} Some consider this classification of the disorder to be true tumoral calcinosis.¹⁴ Recently, 2 separate genetic defects in families with hyperphosphatemic tumoral calcinosis were described. Mutations in the GalNAc transferase 3 gene, *GALNT3*, encoding a glycosyltransferase were initially demonstrated in some patients in 2004,³² with other mutations of *GALNT3* identified later.³³⁻³⁵ In addition, defects in the fibroblast growth factor 23 gene, *FGF23*, resulting in decreased excretion of phosphorus in the proximal renal tubule, have been found in patients with tumoral calcinosis.³⁶⁻³⁹

The third classification, secondary tumoral calcinosis, includes patients with associated medical or metabolic disorders, such as chronic renal failure, hyperparathyroidism, milk-alkali syndrome, hypervitaminosis D, sarcoidosis, scleroderma, and other systemic disorders that lead to metabolic abnormalities.^{4,8,20,30}

Here we describe our experience with 2 tumoral calcinosis cases. We emphasize the surgical complications we encountered and highlight the many features that are common to the syndrome.

CASE REPORTS

Case 1

A 27-year-old African American woman with a 9-year history of bilateral hip pain and swelling presented with firm, bilateral, symmetrical, anterolateral masses. Past medical history was significant for iron-deficiency anemia, asthma, and chronic pain requiring narcotics. The patient demonstrated a Trendelenburg gait, full range of motion of the knees, and full flexion and extension of the hips bilaterally without edema, erythema, or adenopathy. Plain radiographs showed extensive soft-tissue calcifications in the thighs bilaterally (Figure 1). MRI without contrast showed multiple, rounded cystic structures in the soft tissues of the hip region, extending through the anterior, medial, lateral, and superior soft tissues surrounding the hips but not involving the hip joints (Figure 2). Results of a 3-phase bone scan produced a large area of abnormally increased activity around each proximal thigh extending toward the buttocks. Results of serum laboratory testing revealed a creatinine level of 0.4 mg/dL, blood urea nitrogen level of 5 mg/dL, calcium level of 8.0 mg/dL, alkaline phosphatase level of 81 U/L, and phosphorus level of 5.1 mg/dL. Overall findings were consistent with hyperphosphatemic tumoral calcinosis.

Palliative surgical decompression of the right thigh was attempted with the knowledge that incomplete excision would not be curative but might reduce the patient's pain. The pain was such that the patient waived a preoperative trial of phosphate-wasting medication. Phosphate-wasting medication and a low-phosphate diet were started immediately after surgery. Surgery revealed multiple pockets of the white, chalky fluid, plus calcified, necrotic muscle with very little normal muscle in the quadriceps, abductors, and hamstrings. As the tumoral calcinosis extended into nearly all the muscles surrounding the hip, complete removal of the masses was not attempted. Several areas of ossified

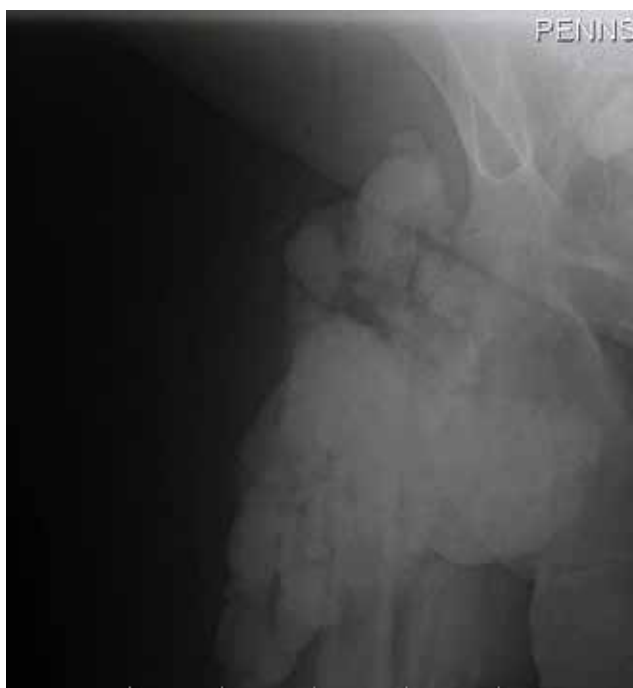

Figure 3. Plain radiograph of right hip shows soft-tissue calcifications preventing optimal visualization of cortical borders of proximal femur.

subcutaneous fat were excised. After all reachable fluid collections were evacuated, the field was irrigated, and 2 Hemovac drains were placed, anteriorly and posteriorly. Estimated blood loss (EBL) for the procedure was 1300 mL. Two units of packed red blood cells were transfused during surgery, and 2 more units were given on postoperative day 1.

On postoperative day 11, the patient was discharged with 1 drain in place and she continued to take oral cefazolin. She remained on a low-phosphate diet, was followed by a nutritionist, and was prescribed sevelamer 1600 mg 3 times daily. Two and a half weeks after surgery, the drain and skin staples were removed; there was no evidence of drainage or wound dehiscence. Seven weeks after surgery, part of the incision site was found opened, draining milky fluid similar to that encountered during the operation. Three months later, a copious amount of cloudy, serous fluid was expressed from the incision site. The patient underwent elective irrigation and drainage of the right hip and replacement of a drain. EBL for this procedure was 150 mL; no blood was given to the patient.

The wound continued to drain intermittently and was draining at last follow-up, 17 months after initial surgery. The patient was placed on antibiotics during wound draining. She had discontinued her modified diet 3 months after surgery and was taking the phosphate-sequestering medication sevelamer but not consistently. Pain relief was significant after the initial decompression operation and continued throughout the postoperative course. The patient asked if her other leg could

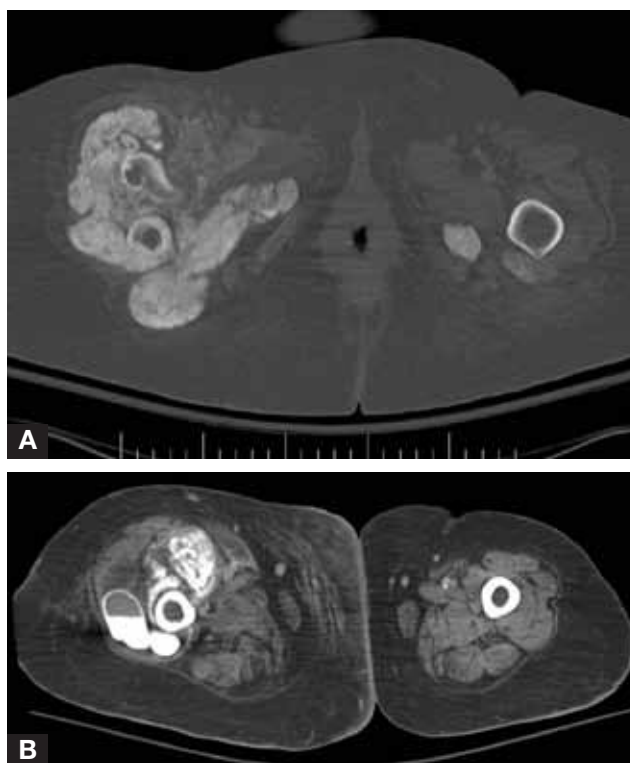


Figure 4. (A) Bone-window computed tomographic image shows fracture of proximal femur with surrounding calcified lesions within soft tissues. (B) Similar computed tomographic image shows fluid-calcium level within one of these lesions.

be treated in the same fashion, but decompression was not performed because of concern about her persistent wound problems and chronic anemia.

Case 2

A 51-year-old morbidly obese woman in her early 50s was transferred from an outside hospital to our intensive care unit 1 week after sustaining a right subtrochanteric fracture in a fall. Past medical history included end-stage renal disease, vascular disease, insulin-dependent diabetes mellitus, hyperparathyroidism, hypothyroidism, and septicemia. The patient was septic on admission, with Gram-positive cocci found at the outside hospital. She was started on vancomycin, with blood cultures later confirming *Staphylococcus epidermidis*. The source of bacteremia was thought to be the Port-a-Cath or her forearm loop graft, both of which were removed over the next 4 days. Results of Port-a-Cath cultures were positive for coagulase-negative *Staphylococcus*. Initial serum laboratory tests revealed a creatinine level of 8.0 mg/dL, blood urea nitrogen level of 67 mg/dL, calcium level of 7.4 mg/dL, phosphorus level of 7.0 mg/dL, and alkaline phosphatase level of 104 U/L. Plain radiographs showed exuberant calcification of soft tissue adjacent to the right hip and proximal femur without adequate visualization of the proximal femur (Figure 3). CT identified the right subtrochanteric fracture and demonstrated the nodular areas in the posteromedial thigh containing calcific fluid,

consistent with tumoral calcinosis (Figures 4A, 4B). Two weeks later, after the sepsis had resolved, open reduction and internal fixation of the right subtrochanteric femur fracture were performed.

Given the extent of the tumoral calcinosis, only the femoral head could be adequately visualized with plain radiography before surgery. Therefore, the right proximal femur was directly exposed to facilitate placement of a femoral reconstruction nail. Extensive tumoral calcinosis involving the soft tissues was excised with difficulty to expose the proximal femur, revealing an oblique fracture with evidence of partial healing. An effort was made to remove as much of the tumoral calcinosis as possible, but excision of all involved areas was not possible because of the massive extent of disease throughout all muscle compartments. During placement of the femoral reconstruction nail, the proximal lateral femoral cortex fractured, but it did not require additional treatment. EBL for the procedure was 1500 mL, and 4 units of packed red blood cells were given during surgery. Gram stains of the tumoral calcinosis lesions were negative, but tissue cultures of the lesions were positive for *S epidermidis*. Antibiotic treatment was continued.

After surgery, the wound continued to drain serosanguinous fluid. On postoperative day 8, a small dehiscence occurred, eliciting a cloudy, granular discharge. Wound cultures on postoperative day 10 were positive for *Klebsiella*, and the patient was given cefepime and levofloxacin. Over the next several weeks, the wound was treated with packing. Three and a half weeks after surgery, with the drainage failing to resolve, the wound was irrigated and débrided, revealing healthy granulation tissue. However, serosanguinous wound drainage persisted, prompting treatment with vacuum-assisted dressings. CT showed good fixation of the femoral nail, which was difficult to see on plain radiography. The patient's course was complicated by poorly controlled blood glucose levels and ileus. Six weeks after débridement, blood cultures were positive for *Candida*, and caspofungin was started. Two days later, the patient, now with hypotension and lower gastrointestinal bleeding, was transferred to the intensive care unit. She died 43 days later, 3 months after hospital admission.

DISCUSSION

Surgical excision of tumoral calcinosis is the primary treatment described in the literature for masses that cause discomfort, limit function, or affect cosmesis.^{1,4,20,40} However, the frequency of complications and recurrence^{2,15,40,41} implies that surgical indications should be limited to patients with significant disability or deformity. In patients without metabolic abnormalities, reported recurrence rates range from 0% to 33%.^{4,7,10,12,25,28,29,40} Some authors have reported that the recurrence rate is lower after complete excision than after incomplete excision.^{4,10,28} In cases with metabolic abnormalities, the lesions tend to recur, especially after incomplete excision.^{2,4}

Treatment of patients with metabolic abnormalities can be more challenging and often requires medical management along with surgery.² Occasionally, correction of metabolic abnormalities can stop the growth of these lesions and lead to regression, particularly for lesions associated with hyperparathyroidism.^{4,42-44} In cases of primary tumoral calcinosis, significant regression or complete resolution has been reported with medical management alone, usually with a restriction of phosphorus intake, absorption, or both.^{27,45-48} There also have been reports of sustained regression of tumoral calcinosis using bisphosphonate therapy.^{49,50} The mechanism behind this phenomenon is not entirely clear. Ultrastructural evaluation of tumoral calcinosis lesions has shown the presence of osteoclast-like giant cells lining intralesional cystic cavities, containing intracytoplasmic membrane-bound vesicles filled with hydroxyapatite crystals and noncrystalline calcific deposits. As these features are comparable to the cell types and intracellular morphology found in bone formation, it has been surmised that bisphosphonates, with their primary effect of osteoclast suppression, inhibit these osteoclast-like cells and prevent calcification of soft tissue.⁵¹ Given this evidence, some experts advocate a combination of surgical excision, medical management, and strict dietary control.^{8,52,53} Radiation therapy and cortisone have not been shown to be effective against tumoral calcinosis.^{20,54}

The local extent of tumoral calcinosis determines the feasibility of complete surgical removal, as was the case with both patients described in this report. A lesion that is large^{4,55,56} or infiltrates tissue^{25,55-62} is difficult to completely excise without causing significant morbidity. In addition, even after a lesion is adequately treated, lesions can form in other locations.^{12,30,63} However, partial resection of a large, infiltrating lesion can provide significant pain relief,⁶⁴ as in case 1. Another case report in the literature described significant pain relief with aspiration of a lesion in the hand.⁶²

Tumoral calcinosis can also lead to postoperative complications, such as prolonged drainage. Prolonged drainage can cause delayed wound healing and even sinus tract formation,^{12,27,56,63,65,66} as evidenced in the 2 cases we have described. Other authors have reported secondary infections caused by chronic wound problems in patients with extensive disease or incomplete resection.^{28,55,63,65,67-69} To our knowledge, wound problems have not been reported in patients with small, isolated disease that was completely resected. Although sinus formation or ulceration before surgical intervention is uncommon, when it occurs it is associated with white, granular discharge.^{7,8,10,12,30,68-72} Spontaneous ulceration or sinus tract formation led to infection in 3 of 8 hemodialysis patients with tumoral calcinosis in one series.⁸ Case 2 in the present report also demonstrates that the comorbidities of patients with secondary tumoral calcinosis may contribute to the severity and duration of complications during the postoperative course.

Infection may even be an outcome because of the nature of the lesion. This lesion can cause problems in its promotion of bacterial growth and bacterial seeding. Tumoral calcinosis deposits act like foreign bodies within the tissues, and this may permit bacterial seeding, as in case 2. One author reported superinfection of a lesion that recurred 7 years after excision; the infection led to extensive abscess formation and subsequent sepsis.⁷³

Radiopaque soft-tissue calcification can pose problems in diagnostic imaging for tumoral calcinosis lesions and associated conditions. Boskey and colleagues⁷⁴ found larger mineral density per unit volume in tumoral calcinosis deposits removed from soft tissue than in normal cortical bone. In case 2, the inability of fluoroscopy to penetrate calcific deposits during fracture fixation necessitated use of a larger incision for direct visualization. The result was more disruption of soft tissues and then, despite appropriate precautions, development of discharge and wound problems. Extensive involvement of radiopaque, periarticular soft-tissue calcifications may render plain radiography useless for diagnosing other conditions, such as fracture or bone involvement. Up until now, the difficulty of fluoroscopic visualization during fracture reduction and fixation in such a case had not been described.

Surgical treatment of patients with extensive tumoral calcinosis may have significant complications. Complications are not well described in the literature, and our 2 cases highlight the challenges that can be encountered in treating patients with this syndrome. Fluoroscopic imaging problems, prolonged drainage, and infection are important complications of surgical intervention in these patients. Historically, chronic wound problems have not been reported in cases of complete excision. For extensive disease that cannot be completely resected, however, surgical intervention should be undertaken only when the benefits of the operation outweigh the risk for complications.

AUTHORS' DISCLOSURE STATEMENT

The authors report no actual or potential conflict of interest in relation to this article.

REFERENCES

- Enzinger FM, Weiss SW. Tumoral calcinosis. In: *Soft Tissue Tumors*. 3rd ed. St. Louis, MO: Mosby; 1995:1039-1045.
- Smack D, Norton SA, Fitzpatrick JE. Proposal for a pathogenesis-based classification of tumoral calcinosis. *Int J Dermatol*. 1996;35(4):265-271.
- Savaci N, Avunduk MC, Tosun Z, Hosnuter M. Hyperphosphatemic tumoral calcinosis. *Plast Reconstr Surg*. 2000;105(1):162-165.
- Tezelman S, Siperstein AE, Duh QY, Clark OH. Tumoral calcinosis. Controversies in the etiology and alternatives in the treatment. *Arch Surg*. 1993;128(7):737-744.
- Murthy DP. Tumoral calcinosis: a study of cases from Papua New Guinea. *J Trop Med Hyg*. 1990;93(6):403-407.
- Hawass Ne-D, Kolawole T, Ismail AH, Patel PJ. Tumoral calcinosis: case reports from Saudi Arabia with a review of the literature. *Trop Geogr Med*. 1988;40(1):58-63.
- Pakasa NM, Kalengayi RM. Tumoral calcinosis: a clinicopathological study of 111 cases with emphasis on the earliest changes. *Histopathology*. 1997;31(1):18-24.
- Hamada J, Tamai K, Ono W, Saotome K. Uremic tumoral calcinosis in hemodialysis patients: clinicopathological findings and identification of calcific deposits. *J Rheumatol*. 2006;33(1):119-126.
- Rodriguez-Peralto JL, Lopez-Barea F, Torres A, Rodriguez-Gonzalez JL, Diaz-Faes J. Tumoral calcinosis in two infants. *Clin Orthop*. 1989;(242):272-276.
- Noyez JF, Murphree SM, Chen K. Tumoral calcinosis, a clinical report of eleven cases. *Acta Orthop Belg*. 1993;59(3):249-254.
- Owor R. Tumoral calcinosis in Uganda. *Trop Geogr Med*. 1972;24(1):39-43.
- Harkness JW, Peters HJ. Tumoral calcinosis. A report of six cases. *J Bone Joint Surg Am*. 1967;49(4):721-731.
- Durant DM, Riley LH 3rd, Burger PC, McCarthy EF. Tumoral calcinosis of the spine: a study of 21 cases. *Spine*. 2001;26(15):1673-1679.
- Olsen KM, Chew FS. Tumoral calcinosis: pearls, polemics, and alternative possibilities. *Radiographics*. 2006;26(3):871-885.
- Steinbach LS, Johnston JO, Tepper EF, Honda GD, Martel W. Tumoral calcinosis: radiologic-pathologic correlation. *Skeletal Radiol*. 1995;24(8):573-578.
- Seeger LL, Butler DL, Eckardt JJ, Layfield L, Adams JS. Tumoral calcinosis-like lesion of the proximal linea aspera. *Skeletal Radiol*. 1990;19(8):579-583.
- Meltzer CC, Fishman EK, Scott WW Jr. Tumoral calcinosis causing bone erosion in a renal dialysis patient. *Clin Imaging*. 1992;16(1):49-51.
- Geirnaerd MJ, Kroon HM, van der Heul RO, Herfkens HF. Tumoral calcinosis. *Skeletal Radiol*. 1995;24(2):148-151.
- Krueger-Franke M, Siebert CH, Weiss M, Rosemeyer B, Gokel M. Tumoral calcinosis of the ischium. *Arch Orthop Trauma Surg*. 1992;111(5):284-286.
- Hruska KA, Lederer ED. Hyperphosphatemia and hypophosphatemia. In: Favus MJ, ed. *Primer on the Metabolic Bone Diseases and Disorders of Mineral Metabolism*. 4th ed. Philadelphia, PA: Lippincott Williams & Wilkins; 1999:246-253.
- Martinez S. Tumoral calcinosis: 12 years later. *Semin Musculoskelet Radiol*. 2002;6(4):331-339.
- Martinez S, Vogler JB 3rd, Harrelson JM, Lyles KW. Imaging of tumoral calcinosis: new observations. *Radiology*. 1990;174(1):215-222.
- Senol U, Karaal K, Cevikol C, Dincer A. MR imaging findings of recurrent tumoral calcinosis. *Clin Imaging*. 2000;24(3):154-156.
- Ovali GY, Tarhan S, Serter S, et al. A rare disorder: idiopathic tumoral calcinosis. *Clin Rheumatol*. 2007;26(7):1142-1144.
- Reed RJ, Hunt RW. Granulomatous (tumoral) calcinosis. *Clin Orthop*. 1965;43(2):233-240.
- McKee MD. Recombinant human bone morphogenic protein-7: applications for clinical trauma. *J Orthop Trauma*. 2005;19(suppl 10):S26-S28.
- Gregosiewicz A, Warda E. Tumoral calcinosis: successful medical treatment. A case report. *J Bone Joint Surg Am*. 1989;71(8):1244-1249.
- Kisembo H, Kiguli-Malwade E, Kawooya MG. Tumoral calcinosis: report of nine cases. *East Afr Med J*. 2000;77(10):574-575.
- Jain A, Fedarko NS, Collins MT, et al. Serum levels of matrix extracellular phosphoglycoprotein (MEPE) in normal humans correlate with serum phosphorus, parathyroid hormone and bone mineral density. *J Clin Endocrinol Metab*. 2004;89(8):4158-4161.
- Lomasney LM, Basu A, Demos TC, Laskin W. Fibrous dysplasia complicated by aneurysmal bone cyst formation affecting multiple cervical vertebrae. *Skeletal Radiol*. 2003;32(9):533-536.
- Prince MJ, Schaeffer PC, Goldsmith RS, Chausmer AB. Hyperphosphatemic tumoral calcinosis: association with elevation of serum 1,25-dihydroxycholecalciferol concentrations. *Ann Intern Med*. 1982;96(5):586-591.
- Topaz O, Shurman D, Bergman R. Mutations in GALNT3, encoding a protein involved in O-linked glycosylation, cause familial tumoral calcinosis. *Nat Genet*. 2004;36(6):579-581.
- Ichikawa S, Lyles KW, Econs MJ. A novel GALNT3 mutation in a pseudo-autosomal dominant form of tumoral calcinosis: evidence that the disorder is autosomal recessive. *J Clin Endocrinol Metab*. 2005;90(4):2420-2423.
- Specktor P, Cooper JG, Indelman M, Sprecher E. Hyperphosphatemic familial tumoral calcinosis caused by a mutation in GALNT3 in a European kindred. *J Hum Genet*. 2006;51(5):487-490.
- Campagnoli MF, Pucci A, Garelli E, et al. Familial tumoral calcinosis and testicular microlithiasis associated with a new mutation of GALNT3 in a white family. *J Clin Pathol*. 2006;59(4):440-442.
- Chefetz I, Heller R, Galli-Tsinopoulou A, et al. A novel homozygous missense mutation in FGF23 causes familial tumoral calcinosis associated with disseminated visceral calcification. *Hum Genet*. 2005;118(2):261-266.
- Larsson T, Yu X, Davis SI, et al. A novel recessive mutation in fibroblast growth factor-23 causes familial tumoral calcinosis. *J Clin Endocrinol Metab*. 2005;90(4):2424-2427.
- Benet-Pages A, Orlik P, Strom TM, Lorenz-Depiereux B. An FGF23 missense mutation causes familial tumoral calcinosis with hyperphosphatemia. *Hum Mol Genet*. 2005;14(3):385-390.
- Araya K, Fukumoto S, Backenroth R, et al. A novel mutation in fibroblast growth factor 23 gene as a cause of tumoral calcinosis. *J Clin Endocrinol Metab*. 2005;90(10):5523-5527.
- Kozlowski K, Barylak A, Campbell J, et al. Tumoral calcinosis in children (report of 13 cases). *Australas Radiol*. 1988;32(4):448-457.

41. Abraham Z, Rozner I, Rozenbaum M. Tumoral calcinosis: report of a case and brief review of the literature. *J Dermatol*. 1996;23(8):545-550.
42. Pecovnik-Balon B, Kramberger S. Tumoral calcinosis in patients on hemodialysis. Case report and review of the literature. *Am J Nephrol*. 1997;17(1):93-95.
43. Thakur A, Hines OJ, Thakur V, Gordon HE. Tumoral calcinosis regression after subtotal parathyroidectomy: a case presentation and review of the literature. *Surgery*. 1999;126(1):95-98.
44. Mockel G, Buttgereit F, Labs K, Perka C. Tumoral calcinosis revisited: pathophysiology and treatment. *Rheumatol Int*. 2005;25(1):55-59.
45. Mozaffarian G, Lafferty FW, Pearson OH. Treatment of tumoral calcinosis with phosphorus deprivation. *Ann Intern Med*. 1972;77(5):741-745.
46. Yamaguchi T, Sugimoto T, Imai Y, Fukase M, Fujita T, Chihara K. Successful treatment of hyperphosphatemic tumoral calcinosis with long-term acetazolamide. *Bone*. 1995;16(suppl 4):247S-250S.
47. Manaster BJ, Doyle AJ. Giant cell tumors of bone. *Radiol Clin North Am*. 1993;31(2):299-323.
48. Kirk TS, Simon MA. Tumoral calcinosis. report of a case with successful medical management. *J Bone Joint Surg Am*. 1981;63(7):1167-1169.
49. Mori H, Okada Y, Tanaka Y. Etidronate for the treatment of progressive tumoral calcinosis in hemodialysis patients. *Intern Med*. 2007;46(17):1485-1486.
50. Jacob JJ, Mathew K, Thomas N. Idiopathic sporadic tumoral calcinosis of the hip: successful oral bisphosphonate therapy. *Endocr Pract*. 2007;13(2):182-186.
51. McGregor DH, Mowry M, Cherian R, McAnaw M, Poole E. Nonfamilial tumoral calcinosis associated with chronic renal failure and secondary hyperparathyroidism: report of two cases with clinicopathological, immunohistochemical, and electron microscopic findings. *Hum Pathol*. 1995;26(6):607-613.
52. Walentynowicz JE, Mahoney MD, Saldana MJ. Tumoral calcinosis. Case report with treatment failure. *Orthop Rev*. 1989;18(6):687-690.
53. Calloway DM, Saldana MJ. Combined modality treatment for tumoral calcinosis. *Orthop Rev*. 1993;22(3):365-369.
54. Lafferty FW, Reynolds ES, Pearson OH. Tumoral calcinosis: a metabolic disease of obscure etiology. *Am J Med*. 1965;38:105-118.
55. Berg D. Tumoral calcinosis. *Br J Surg*. 1972;59(7):570-571.
56. Rambani R, Dhillon MS, Aggarwal R. Tumoral calcinosis with unusual presentation. A case report. *Acta Orthop Belg*. 2003;69(4):368-372.
57. Malik M, Acharya S. Tumoral calcinosis of the fingers. A report of two cases. *Int Orthop*. 1993;17(5):279-281.
58. Nath S, Desai G. Tumoral calcinosis: successful treatment by flap surgery. *Trop Doct*. 1994;24(3):126-127.
59. Slavin G, Klenerman L, Darby A, Bansal S. Tumoral calcinosis in England. *Br Med J*. 1973;1(5846):147-149.
60. Franceschi F, Loro A. Tumoural calcinosis. *Trop Doct*. 1997;27(4):247.
61. Sekine I, Kodama T, Yokose T, et al. Rare pulmonary tumors—a review of 32 cases. *Oncology*. 1998;55(5):431-434.
62. Asuncion GF, Tzamas CD. Uremic tumoral calcinosis: acute hand presentations mimicking infection. *J Hand Surg Am*. 1994;19(5):809-812.
63. Thompson JEM, Tanner FH. Tumoral calcinosis. *J Bone Joint Surg Am*. 1949;31(1):132-140.
64. Arikawa J, Higaki Y, Mizushima J, Nogita T, Kawashima M. Tumoral calcinosis: a case report with an electron microscopic study. *Eur J Dermatol*. 2000;10(1):52-54.
65. Baldursson H, Evans EB, Dodge WF, Jackson WT. Tumoral calcinosis with hyperphosphatemia. a report of a family with incidence in four siblings. *J Bone Joint Surg Am*. 1969;51(5):913-925.
66. Viegas SF, Evans EB, Calhoun J, Goodwiller SE. Tumoral calcinosis: a case report and review of the literature. *J Hand Surg Am*. 1985;10(5):744-748.
67. Barrière H, Welin J, Lenne Y, Visset J, Vigier P. Teutschlaender lipo-calcinogranulomatosis or tumoral calcinosis of Inclan (author's transl) [in French]. *Ann Dermatol Venereol*. 1977;104(2):136-140.
68. Smit GG, Schmaman A. Tumoral calcinosis. *J Bone Joint Surg Br*. 1967;49(4):698-703.
69. Hacıhanefioglu U. Tumoral calcinosis. A clinical and pathological study of eleven unreported cases in Turkey. *J Bone Joint Surg Am*. 1978;60(8):1131-1135.
70. McClatchie S, Bremner AD. Tumoral calcinosis—an unrecognized disease. *Br Med J*. 1969;1(6637):153-155.
71. Buch AC, Panicker NK, Gore CR. Tumoral calcinosis: a series of six cases with review of pathogenesis and histopathological diagnosis. *Indian J Pathol Microbiol*. 2006;49(2):182-187.
72. Veress B, Malik MO, El Hassan AM. Tumoural lipocalcinosis: a clinicopathological study of 20 cases. *J Pathol*. 1976;119(2):113-118.
73. Oeggerli P, Maurer R, Kistler H. Tumoral calcinosis with superinfection and sepsis [in German]. *Schweiz Med Wochenschr*. 1991;121(38):1387-1392.
74. Boskey AL, Vigorita VJ, Sencer O, Stuchin SA, Lane JM. Chemical, microscopic, and ultrastructural characterization of the mineral deposits in tumoral calcinosis. *Clin Orthop*. 1983;(178):258-269.

This paper will be judged for the Resident Writer's Award.

Advertiser Index

The American Journal of Orthopedics

2011 Resident Writer's Award Program 224, 225, 232

Chronic Pain Perspectives 246

American Orthopaedic Society for Sports Medicine

2011 Annual Meeting 217

Eli Lilly & Co

Cymbalta 233-240
Forteo Cov II, 209-212

Gebauer Company 215

NAS Recruitment Communications 215