

Tibial Plateau “Kissing Lesion” From a Proud Osteochondral Autograft

Michael R. Johnson, MD, and Robert F. LaPrade, MD, PhD

Abstract

Knee osteochondral lesions can be debilitating. Multiple procedures have been used to manage these defects. Osteochondral autograft transplantation is one such option. Reported complications include donor-site morbidity, failed osteointegration, size mismatch, and incongruity. In this article, we report a case of graft incongruity of the medial femoral condyle that resulted in a full-thickness “kissing lesion” groove on the opposing medial tibial plateau. In an osteochondral autograft transplantation procedure, proper surgical technique is paramount to prevent placement of a proud autograft and avoid the difficult complication of associated tibial chondral defects.

Isolated osteochondral defects in a symptomatic knee can be difficult to manage. Patients report knee pain with sports or walking, or difficulties in simple activities of daily living. Many types of treatments have been devised and implemented, with some modalities having better success than others. Management of both the articular cartilage and the subchondral defect is considered the mainstay of treatment. One such therapeutic option is an osteochondral autogenous transfer through an open or arthroscopic approach. The procedure is often successful in supporting and resurfacing the osteochondral lesion in either a single- or multiple-plug mosaic pattern. However, use of ipsilateral (and contralateral) knee osteochondral plugs is not without complications. Donor sites heal with fibrocartilage instead of normal hyaline cartilage.¹ Donor-site morbidity has been reported for pain related to fibrocartilage overgrowth or a lack of any fibrocartilage healing, with repeat surgery required to manage these donor-site complications.²

At the time this article was written, Dr. Johnson was Chief Resident, Orthopaedic Surgery, University of Minnesota, Minneapolis, Minnesota. He is now Staff Physician, Fairview Red Wing Hospital, Red Wing, Minnesota.

Dr. LaPrade is Chief Medical Research Officer, Steadman Philippon Research Institute and Surgeon, The Steadman Clinic, Vail, Colorado.

Address correspondence to: Robert F. LaPrade, MD, PhD, The Steadman Clinic, 181 West Meadow Drive, Suite 400, Vail, CO 81657 (tel, 970-476-1100; fax, 970-479-5813; e-mail, rlaprade@steadmanclinic.net).

Am J Orthop. 2011;40(7):359-361. Copyright Quadrant HealthCom Inc. 2011. All rights reserved.

Not only can there be complications with donor-site morbidity, but recipient-site morbidity is possible as well. Complications reported in the literature include failure of osteointegration, size mismatch, and recipient-site incongruity.³⁻⁵ To our knowledge, there are no reports of recipient-site “kissing lesion” from incongruous osteochondral plugs.

In this article, we report a case of a prominently placed osteochondral autograft plug resulting in a medial tibial plateau kissing lesion. The patient provided written informed consent for print and electronic publication of this case report.

CASE REPORT

A 23-year-old white woman presented with a 3-year history of left medial knee pain, locking, and catching that developed after 2 left knee surgical procedures. After left knee debridement of an unstable osteochondritis dissecans defect of the medial femoral condyle 9 years earlier, she underwent an osteochondral autograft transplantation procedure, with the donor site being the distal aspect of the trochlear groove. At presentation, her pain was most noticeable with walking stairs, kneeling, and squatting. She noted issues with locking and catching. Clinical examination revealed a left knee effusion as well as pain and crepitation along the medial joint line to valgus stressing at 30° of knee flexion. Repeat radiographs showed a prominent and obliquely oriented osteochondral transfer graft plug of the medial femoral condyle (Figure 1). Long-leg standing radiographs

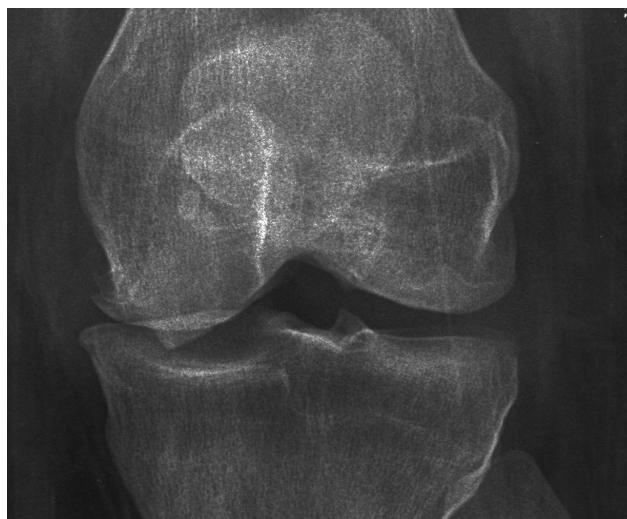

Figure 1. Preoperative anteroposterior radiograph of left knee shows bony irregularity at distal medial femoral condyle.

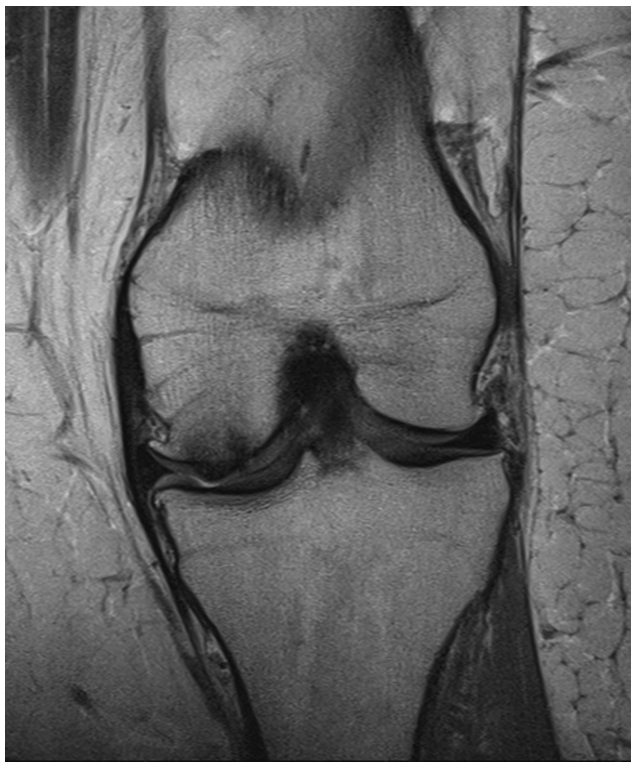

Figure 2. Preoperative coronal T₁-weighted magnetic resonance imaging shows prominence of osteochondral graft in distal left knee medial femoral condyle. Note adjacent tibial plateau chondral surface.

showed moderate varus alignment with a mechanical axis passing through the middle of the medial compartment of the left knee. Magnetic resonance imaging (MRI) of the involved knee showed a 2-mm step-off/prominence at the recipient site on the medial femoral condyle caused by incongruence of the osteochondral autograft transplantation plug (Figure 2). Given the debilitating pain, mechanical symptoms, and MRI findings, arthroscopy was performed to evaluate the patient's candidacy for proximal tibial osteotomy and a possible osteochondral allograft. During surgery, the lateral aspect of the notch (donor site) showed dense overgrowth of fibrous tissue that engaged the inferior pole of the patella past 90° of flexion. Evaluation of the medial compartment revealed a 2- to 3-mm bony prominence of the recipient autograft (Figure 3). The anterior aspect of the autograft had some cartilage delamination. The medial tibial plateau had a full-thickness kissing lesion in a linear groove, from posterior to anterior, corresponding to the prominence of the autograft (Figure 4). When the knee was taken through a range of motion in flexion and extension, the tibial plateau lesion from anterior to posterior engaged the proud osteochondral graft recipient site.

DISCUSSION

We have described a common problem in a young person's knee—an osteochondral defect. Our patient underwent

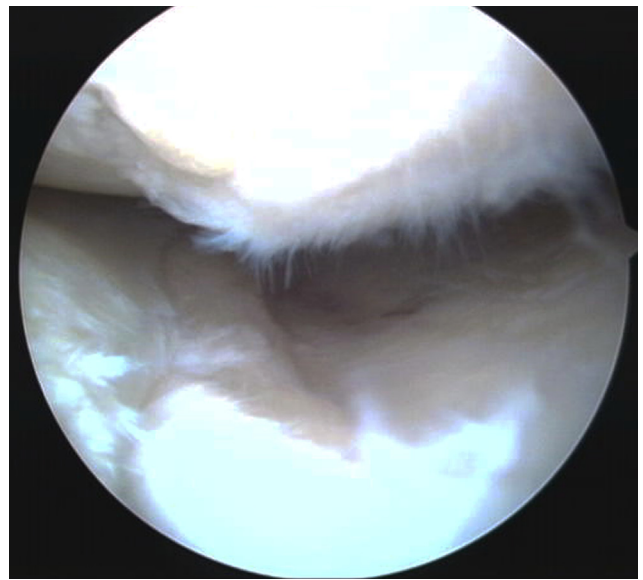


Figure 3. Proud osteoarticular autograft transplant recipient site and medial tibial plateau “kissing lesion” before debridement (left knee).

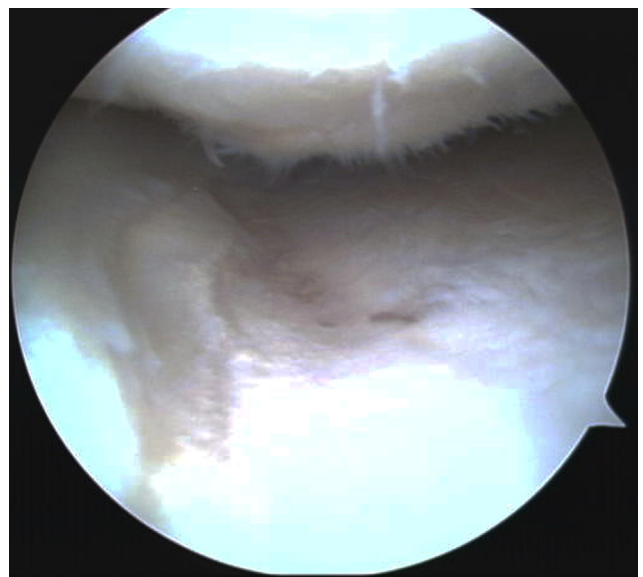


Figure 4. Osteoarticular autograft transplant recipient site and medial tibial plateau “kissing lesion” after debridement (left knee).

a common articular cartilage resurfacing procedure—an autogenous osteochondral autograft transfer procedure—to provide pain relief and to potentially slow progression of cartilage loss. However, this patient's case was unique because we recognized, and documented, iatrogenic progression of articular cartilage damage of the adjacent medial tibial plateau caused by prominence of the osteochondral autograft plug on the corresponding medial femoral condyle.

Osteochondral autograft procedures are commonly used to manage chondral or osteochondral defects of the knee. Transfer involves using cylindrical grafts of various sizes from areas of decreased weight-bearing

and transferring them to areas of osteochondral defect. These plugs are press-fit into the defect congruent to the stable, surrounding hyaline cartilage. One technical difficulty in arthroscopic osteochondral autograft transplantation is obtaining a perpendicular graft. This means the cartilage cap is oriented perpendicular to the longitudinal axis of the osteochondral plug. Proper graft harvest can minimize the potential for recipient mismatch or incongruity. Recent literature points to equivalent outcomes when an osteochondral autograft transfer system (OATS) is used to harvest and insert the cartilage through either a mini-open incision or an arthroscopic surgery.^{6,7}

Osteochondral autograft transplantation has been reported in the literature for the management of osteochondritis dissecans and osteochondral lesions. Investigators conducting multiple long-term studies have reported on the clinical outcomes of this procedure.^{8,9} Its success has been reported to depend on the appropriate matching of the lesion with donor-site plugs. Appropriate placement of plugs into the donor site is crucial for aligning the plugs with the native cartilage. Lastly, appropriate postoperative rehabilitation is needed to permit osteointegration of the osteochondral plugs.¹⁰ Studies have shown that, when patients are properly selected, up to 92% of them have good to excellent functional outcomes.⁸

Complications of this procedure have been reported and theorized to include donor-site pain, size mismatch, incongruity, and osteointegration failure. To our knowledge, there are no reports on proud, osteochondral autograft plugs producing a symptomatic kissing lesion groove on the opposing tibial plateau surface. Our patient also had fibrocartilage overgrowth at the donor site from the lateral intercondylar notch.

The literature supports use of osteochondral autograft transplantation for full-thickness articular cartilage or osteochondral lesions in the knee. When this technique is performed appropriately and correctly, most patients have symptomatic improvement and return to full activities. As documented in this report, however, when the autograft transplant is left proud in the knee, concomitant injury can be seen at the corresponding level of the corresponding tibial plateau.

AUTHORS' DISCLOSURE STATEMENT

The authors report no actual or potential conflict of interest in relation to this article.

REFERENCES

1. Ahmad CS, Guiney WB, Drinkwater CJ. Evaluation of donor site intrinsic healing response in autologous osteochondral grafting of the knee. *Arthroscopy*. 2002;18(1):95-98.
2. LaPrade RF, Botker JC. Donor-site morbidity after osteochondral autograft transfer procedures. *Arthroscopy*. 2004;20(7):e69-e73.
3. Gudas R, Kalesinkas RJ, Kimtys V, et al. A prospective randomized clinical study of mosaic osteochondral autologous transplant versus microfracture for the treatment of osteochondral defects in the knee joint in young athletes. *Arthroscopy*. 2005;21(9):1066-1075.
4. Hangody L, Fules P. Autologous osteochondral mosaicplasty for the treatment of full-thickness defects of weight-bearing joints: ten years of experimental and clinical experience. *J Bone Joint Surg Am*. 2003;85(suppl 2):25-32.
5. Marcacci M, Kon E, Delcogliano M, Filardo G, Busacca M, Zaffagnini S. Arthroscopic autologous osteochondral grafting for cartilage defects of the knee: prospective study results at a minimum 7-year follow-up. *Am J Sports Med*. 2007;35(12):2014-2021.
6. Diduch DR, Chhabra A, Blessey P, Miller MD. Osteochondral autograft plug transfer: achieving perpendicularity. *J Knee Surg*. 2003;16(1):17-20.
7. Keeling JJ, Gwinn DE, McGuigan FX. A comparison of open versus arthroscopic harvesting of osteochondral autografts. *Knee*. 2009;16(6):458-462.
8. Hangody L, Vásárhelyi G, Hangody LR, et al. Autologous osteochondral grafting—technique and long-term results. *Injury*. 2008;39(suppl 1):S32-S39.
9. Magnussen RA, Dunn WR, Carey JL, Spindler KP. Treatment of focal articular cartilage defects in the knee: a systematic review. *Clin Orthop*. 2008;(466):952-962.
10. Hangody L, Rathonyi GK, Duska Z, Vásárhelyi G, Fules P, Modis L. Autologous osteochondral mosaicplasty. Surgical technique. *J Bone Joint Surg Am*. 2004;86(suppl 1):65-72.

This paper will be judged for the Resident Writer's Award.

Electronic Publications

As of June 2011, all electronically published articles will require registration for full-text access. Registration is free at www.amjorthopedics.com and does not require a print subscription.

How to Register:

- Visit www.amjorthopedics.com
- Click on "Register" at top right
- Follow on-screen instructions
- Activate your account