

Subscapularis Tendon Rupture in an 8-Year-Old Boy: A Case Report

Amandeep Bhalla, MD, Kevin Higashigawa, MD, and David McAllister, MD

Abstract

Since falling off a motorcycle 2 years earlier, an 8-year-old, right-hand-dominant boy reported anterior shoulder pain and weakness. After being evaluated by his family physician and completing a course of physical therapy with no symptomatic improvement, he was seen at our institution.

Physical examination was remarkable for diminished strength with internal rotation (4/5). In addition, belly-press and lift-off tests were positive, suggesting a lesion of the subscapularis. Magnetic resonance imaging of the shoulder showed a full-thickness subscapularis tendon tear and a supraspinatus tendon signal that could have represented a partial-thickness tear vs supraspinatus tendinosis.

The patient underwent right shoulder diagnostic arthroscopy with debridement of a partial-thickness articular-sided tear of the supraspinatus tendon followed by open repair of the subscapularis tendon rupture.

This case illustrates a traumatic subscapularis tendon injury that is rare in this age group. A few other traumatic subscapularis injuries have been reported in children, but they all demonstrated bony avulsion of the lesser tuberosity.

Pathology of the subscapularis tendon is not commonly considered a major source of shoulder pain and dysfunction, particularly in young patients. Subscapularis tendon tears can be partial or complete, and can occur in isolation or coupled with tears involving the supraspinatus tendon. Subscapularis tendon tears also may involve the rotator interval and the biceps pulley system. In these cases, instability of the long head of the biceps tendon may dominate the clinical presentation.¹ Isolated subscapularis rupture is typically caused by trauma. A few authors have described isolated avulsion fractures of the subscapularis insertion into the lesser tuberosity in children.^{2,3} The parents of the patient

Dr. Bhalla is Orthopaedic Surgery Resident, Harbor-UCLA Medical Center, Torrance, California. Dr. Higashigawa is Sports Fellow and Dr. McAllister is Professor, Department of Orthopaedic Surgery, David Geffen School of Medicine, University of California Los Angeles, Los Angeles, California.

Address correspondence to: David McAllister, MD, Professor, Department of Orthopaedic Surgery, University of California Los Angeles, CHS, Box 956902, Los Angeles, CA 90095-6902 (tel, 310-206-5250; fax, 310-825-1311; e-mail, dmcallister@mednet.ucla.edu).

Am J Orthop. 2011;40(9):471-474. Copyright Quadrant HealthCom Inc. 2011. All rights reserved.

we describe provided written informed consent for print and electronic publication of this case report.

CASE REPORT

An 8-year-old, right-hand-dominant boy with a 2-year history of right shoulder pain presented to our orthopedic outpatient clinic. The patient's shoulder problem began after he crashed on a motorcycle and fell on his outstretched upper extremity. Since the crash, there had been multiple episodes of the shoulder "giving out," but no frank dislocation. He reported anterolateral shoulder pain and weakness with overhead activities and difficulty with motorcycle riding, basketball, and swimming.

On examination, there was some tenderness to palpation at the lesser tuberosity. Both shoulders had full active range of motion (ROM). However, active external rotation at the side was 90° on the right and 45° on the left. In addition, the right subscapularis was weaker than the left (belly-press and lift-off tests were positive). Magnetic resonance imaging (MRI) showed a complete rupture of the subscapularis tendon (Figure 1) and supraspinatus tendinosis vs a partial-thickness tear (Figure 2).

Diagnostic arthroscopy revealed an intact biceps tendon and an intact tendon anchor. The anterior, inferior, and posterior aspects of the labrum were intact and appeared normal. There was a partial-thickness

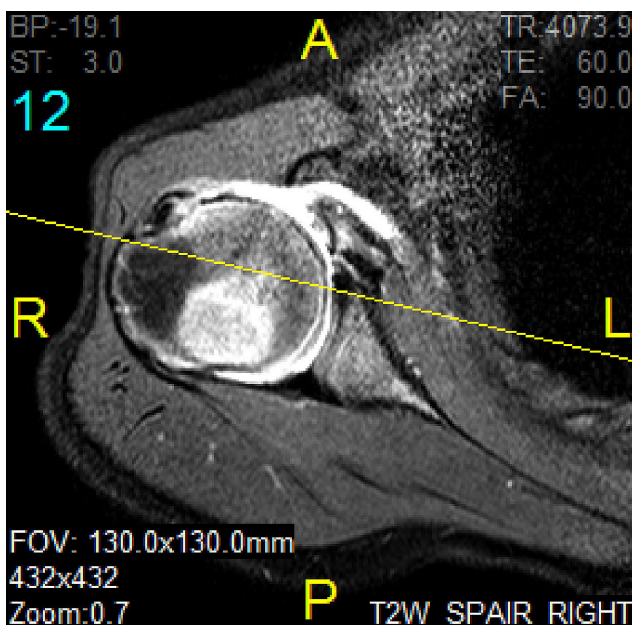


Figure 1. T₂-weighted axial magnetic resonance imaging shows complete subscapularis rupture.

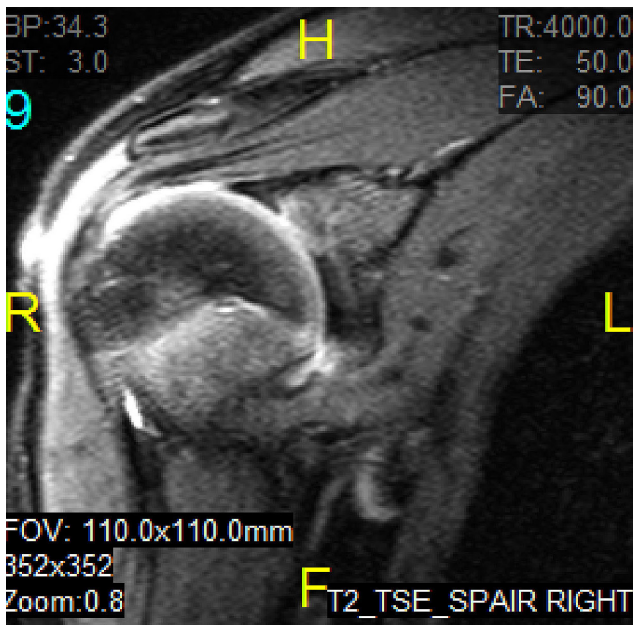


Figure 2. T₂-weighted coronal magnetic resonance imaging shows partial supraspinatus tear.

articular-sided tear of the supraspinatus tendon involving approximately 10% to 15% of the tendon thickness (Figure 3). Complete rupture of the subscapularis tendon was also noted (Figure 4). The partial-thickness supraspinatus tear was debrided with a handheld motorized shaver.

Next, an anterior approach was performed through a deltopectoral approach. The torn subscapularis tendon was readily identified, with minimal retraction. The tendon was carefully separated from an intact anterior capsule and was easily mobilized laterally. A remnant of tendon was found attached to the lesser tuberosity, and the torn tendon ends were repaired directly with interrupted No. 2 Ethibond sutures. Gentle external rotation of the shoulder demonstrated integrity of the repair site. After surgery, the patient received a shoulder sling, and the

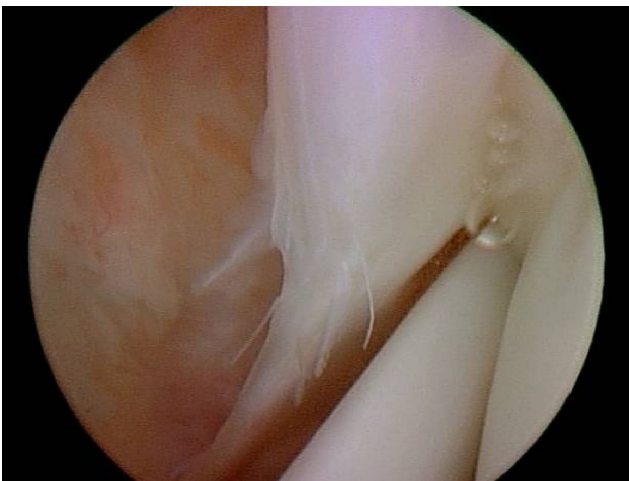


Figure 3. Intra-articular arthroscopic image of partial tear of supraspinatus tendon.

shoulder was immobilized for 3 weeks, after which the sling could be removed intermittently for active ROM exercises consisting of external rotation with the elbow at the side to 30° and forward elevation to 90°. After 6 weeks, the sling was discontinued and gentle rotator cuff strengthening exercises and unrestricted mobilization exercises were prescribed. Three months after surgery, ROM and strength were full and symmetrical, and the patient described resolution of preoperative symptoms. He was advised to refrain from contact sports and motorcycle riding for at least 2 more months.

DISCUSSION

The subscapularis has 4 to 6 tendon slips arising from deep within the muscle belly. These slips converge superiorly and laterally to form a main tendon that lies within the upper third of the muscle and inserts along the superior aspect of the lesser tuberosity. These bands provide additional surface area for muscle fiber attachment and concentrate the vector of the muscle pull. Some fibers of the subscapularis tendon interdigitate with the anterior fibers of the supraspinatus tendon to contribute to the structure of the rotator cuff interval. The subscapularis participates in glenohumeral stability both directly, through concavity compression into the glenoid, and indirectly, through muscle contraction that causes tightening of the tendon and the anterior capsular structures.¹

In the general population, tears of the subscapularis tendon are predominantly the result of a degenerative process and often occur in conjunction with supraspinatus tears.⁴ In the older athletic population, chronic degenerative tearing of the tendon may precede sports-related rupture, particularly after a shoulder dislocation.⁵ Less commonly, as in our patient's case, traumatic injury can cause acute, isolated subscapularis tears; this injury tends to occur in a relatively younger age group. The most common mechanisms of injury are forced hyperextension and external rotation of the shoulder.^{6,7}

Gerber and Krushell⁷ reported on 16 patients who

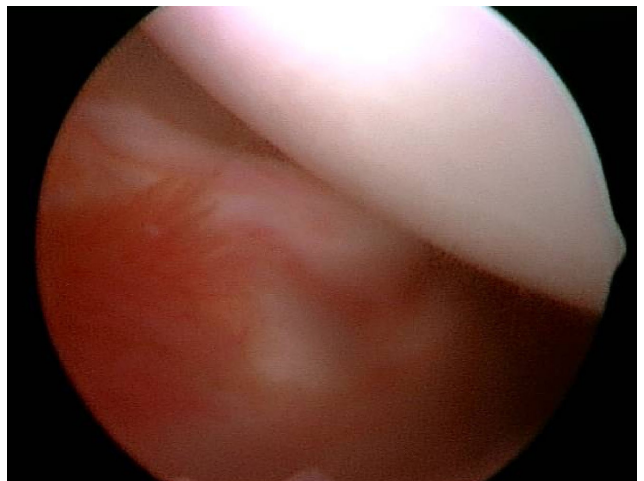


Figure 4. Intra-articular arthroscopic image of complete subscapularis rupture.

sustained isolated complete subscapularis tears caused by forced external rotation with the arm at the side (7 patients), forced hyperextension (6), motor vehicle accident (2), or traumatic anterior dislocation (1). Three of the patients (between the ages of 25-32 years) previously underwent anterior shoulder surgery with division and repair of the subscapularis and sustained early postoperative trauma resulting in rupture of the repair; the other 13 patients (mean age, 51 years; range, 35-64 years) had no history of shoulder surgery. All patients presented with pain and weakness without instability. All the tendons avulsed from the lesser tuberosity without fracture. In the majority of cases, a thin layer of scar remained on the lesser tuberosity and could have been mistaken for a remnant of tendon, but was easily elevated and found to be contiguous with the ruptured end. Of the 16 patients, 11 had biceps pathology: 9 dislocations and 2 ruptures in the bicipital groove. All the subscapularis tendons were repaired through bone tunnels in the lesser tuberosity.

In a retrospective analysis of 350 rotator cuff surgeries performed at the Hospital for Special Surgery between 1991 and 1993, Deutsch and colleagues⁶ found that 14 shoulders in 13 patients had isolated tears of the subscapularis tendon. Seven of the 13 patients also had a pathologic condition of the biceps tendon, such as subluxation, dislocation, or rupture. Mean age was 39 years (range, 18-64 years). The predominant mechanism of injury (10/13 patients) was traumatic hyperextension or external rotation of the abducted arm. Seven of the 14 injuries occurred during sporting events. All patients reported pain and weakness; only 1 patient, who had a history of prior anterior dislocation, reported instability. In the majority of cases, the subscapularis tendon avulsed from the lesser tuberosity without fracture and was repaired with suture anchors. In only 2 cases, the tendon ruptured in the midsubstance or at the musculotendinous junction, and was repaired to the existing stump of tendon, which remained attached to the lesser tuberosity.

There are only a few published cases of isolated subscapularis injuries in children. White and Riley² were the first to report on this unusual injury in a child. The 12-year-old in the case sustained an external rotation-abduction injury without dislocation and presented with anterior shoulder pain and diminished active internal rotation. Radiographs showed an avulsion fracture of the lesser tuberosity, and primary surgical reattachment was performed. The patient recovered full and painless ROM and returned to full athletic activity. Sikka and colleagues³ described an avulsion of the subscapularis in a 14-year-old boy who sustained an external rotation-abduction injury without dislocation while wrestling. The patient was initially misdiagnosed with shoulder strain and underwent 3 months of physical therapy with no subjective improvement while continually reporting activity-related pain, weakness, and instability. At 9 months, MRI showed an avulsion fracture of the lesser tuberosity

with the subscapularis attached. Open repair with transosseous sutures was successful, and at 1 year, the patient returned to wrestling without clinical symptomatology.

In the skeletally immature patient, the bony or physal interface is often weaker than the tendon or ligament itself. Our case report is unique in that it describes an isolated subscapularis tendon rupture in a child and without bony avulsion of the lesser tuberosity. We successfully repaired the torn tendon primarily, without need for suture anchors or transosseous tunnels.

Regardless of age and absent anterior dislocation, the most common mechanism for an isolated subscapularis tear appears to be violent and forced external rotation or hyperextension of the shoulder.^{2,3,6-8} Eccentric contraction of the subscapularis muscle can then lead to injury. Although our patient described episodes of instability, the classic presentation of subscapularis tendon tears is mainly that of pain and weakness.¹ The 14-year-old boy described by Sikka and colleagues³ also presented with instability, which may be attributed to a lateral capsular avulsion and a subsequent humeral avulsion of glenohumeral ligament lesion discovered at surgery. Instability associated with isolated subscapularis tendon tears, however, is unusual and seems to occur mainly after traumatic anterior dislocation.^{6,9}

Isolated subscapularis tendon tears are uncommon even in the older patient. Delays in diagnosis are therefore a recurrent theme in the literature.^{3,6-8} In the review by Gerber and Krushell,⁷ correct diagnosis was made acutely in only 2 of 13 patients, and treatment was delayed a mean of 18 months in the other 11 patients. Similarly, in the review by Deutsch and colleagues of 14 isolated subscapularis tendon ruptures in 13 patients, including one patient with bilateral injury,⁶ the correct diagnosis was made acutely in only 2 of the 14 injuries, with treatment delayed a mean of 9 months for the others. Isolated subscapularis tears are rare in children, with the present case being one of only a few described in the literature. Our patient initially presented to his family physician, and correct diagnosis was delayed approximately 2 years. Gerber and colleagues¹⁰ found that clinical results for patients who underwent subscapularis repair more than 36 months after injury were significantly inferior to those for patients who underwent repair less than 20 months after injury. This suggests that more timely diagnosis leading to earlier operative repair can lead to more successful results.

In conclusion, high clinical suspicion should be maintained for a subscapularis tear in any patient who presents with acute anterior shoulder pain and weakness after forced external rotation or hyperextension, regardless of age. On physical examination, the patient typically has weakness in internal rotation and may have increased passive external rotation at the side. Positive belly-press and lift-off tests also can be useful in diagnosing isolated subscapularis tendon tears. MRI is usually diagnostic of this problem. A thorough history and

a focused physical examination, coupled with appropriate imaging, often lead to correct diagnosis and expeditious, appropriate treatment. Earlier operative repair has been associated with more successful results.^{3,10}

AUTHORS' DISCLOSURE STATEMENT

The authors report no actual or potential conflict of interest in relation to this article.

REFERENCES

1. Lyons RP, Green A. Subscapularis tendon tears. *J Am Acad Orthop Surg.* 2005;13(5):353-363.
2. White GM, Riley LH Jr. Isolated avulsion of the subscapularis insertion in a child. *J Bone Joint Surg Am.* 1990;67(4):635-636.
3. Sikka RS, Neault M, Guancho CA. An avulsion of the subscapularis in a skeletally immature patient. *Am J Sports Med.* 2004;32(1):246-249.
4. Sakurai G, Ozaki J, Tomita Y, Kondo T, Tamai S. Incomplete tears of the subscapularis tendon associated with tears of the supraspinatus tendon: cadaveric and clinical studies. *J Shoulder Elbow Surg.* 1998;7(5):510-515.
5. Piasecki DP, Nicholson GP. Tears of the subscapularis tendon in athletes—diagnosis and repair techniques. *Clin Sports Med.* 2008;27(4):731-745.
6. Deutsch A, Alitchek DW, Veltri DM, Potter HG, Warren RF. Traumatic tears of the subscapularis tendon. Clinical diagnosis, magnetic resonance imaging findings, and operative treatment. *Am J Sports Med.* 1997;25(1):13-22.
7. Gerber C, Krushell RJ. Isolated rupture of the tendon of the subscapularis muscle. Clinical features in 16 cases. *J Bone Joint Surg Br.* 1991;73(3):389-394.
8. Edwards TB, Walch G, Sirveaux F, et al. Repair of tears of the subscapularis. Surgical technique. *J Bone Joint Surg Am.* 2006;88(suppl 1, pt 1):1-10.
9. Neviasser RJ, Neviasser TJ, Neviasser JS. Concurrent rupture of the rotator cuff and anterior dislocation of the shoulder in the older patient. *J Bone Joint Surg Am.* 1988;70(9):1308-1311.
10. Gerber C, Hersche O, Farron A. Isolated rupture of the subscapularis tendon. *J Bone Joint Surg Am.* 1996;78(7):1015-1023.

This paper will be judged for the Resident Writer's Award.

2011 Resident Writer's Award

The 2011 Resident Writer's Award competition is sponsored through a restricted grant provided by DePuy. Orthopedic residents are invited to submit original studies, reviews, or case studies for publication. Papers published in 2011 will be judged by *The American Journal of Orthopedics* Editorial Board. Honoraria will be presented to the winners at the 2012 AAOS annual meeting.

\$1,500 for the First-Place Award
\$1,000 for the Second-Place Award
\$500 for the Third-Place Award

To qualify for consideration, papers must have the resident as the first-listed author and must be accepted through the journal's standard blinded-review process.

Papers submitted in 2011 but not published until 2012 will automatically qualify for the 2012 competition.

Manuscripts should be prepared according to our Information for Authors and submitted via our online submission system, Editorial Manager®, at www.editorialmanager.com/AmJOrthop.

Through a restricted grant provided by

