

From Wall Graft to Roof Graft: Reassessment of Femoral Posterior Cruciate Ligament Positioning

Bradley S. Raphael, MD, Travis Maak, MD, Michael B. Cross, MD, Christopher Plaskos, PhD,
Thomas Wickiewicz, MD, Andrew Amis, DSc(Eng), and Andrew Pearle, MD

ABSTRACT

In many technique guides for posterior cruciate ligament (PCL) reconstruction, the PCL is depicted on the wall of the medial femoral condyle (MFC). We hypothesized that most of the anterolateral (AL) bundle originates on the roof of the intercondylar notch (ICN), not on the wall.

Using a surgical navigation system, we delineated and morphed in the computer the entire PCL footprint—the AL bundle, the posteromedial (PM) bundle, and the Humphrey ligament (HL)—of 7 fresh-frozen cadaveric specimens. A clock face was defined in the en face view, with the 12-o'clock axis pointing anteriorly through the top of the notch and the roof being the region between 10 o'clock and 2 o'clock. The AL-bundle, PM-bundle, and HL

positions were calculated in terms of this clock-face definition.

Mean centroids (o'clock position) over all specimens of AL bundle, PM bundle, and HL were, respectively, 10:49, 9:43, and 9:00 on the left knee and 1:11, 2:17, and 3:00 on the right knee. Mean areas were 63 mm² (AL bundle), 63 mm² (PM bundle), and 45 mm² (HL). In 5 of the 7 specimens tested, 100% of the AL bundle originated on the roof of the ICN. Conversely, 66% of the PM bundle and 100% of the HL inserted on the wall of the MFC rather than on the intercondylar roof.

Using computer navigation software, we determined that most of the AL bundle originates on the roof of the ICN and that the PM bundle is centered near the transition between the roof and the wall of the MFC. These findings contradict the depiction in most technique guides for PCL reconstruction. Implant companies and surgeons should modify their techniques to shift PCL graft tunnels from the wall of the MFC to the roof of the ICN.

The posterior cruciate ligament (PCL) is the primary restraint to posterior tibial drawer and is stronger and larger than the anterior cruciate ligament.¹ However, treatment of PCL injuries remains a controversial topic, in some measure because of the inability to control posterior laxity with current reconstruction techniques. The PCL consists of 2 bundles: posteromedial (PM) and anterolateral (AL). There is debate as to whether one or both of these bundles need to be reconstructed to

recreate necessary constraint.²⁻⁴ The AL bundle is stronger, has a larger cross-sectional area, and occupies most of the insertion site of the PCL,⁵ which has led many investigators to focus on this bundle in reconstructive surgery.⁶ Studies have shown that the Humphrey ligament (HL) has unique biomechanical properties and failure rates, adding stability to the knee.⁷ Other studies have described the biomechanical importance of both bundles in reconstruction by showing their co-dominance through knee flexion.⁸⁻¹⁰

It is clear that femoral tunnel positioning in PCL reconstruction has important biomechanical consequences.⁴ However, a consistent interpretation of PCL femoral insertion site anatomy remains elusive. Recently, Apsingi and colleagues¹¹ identified 50 papers that describe PCL insertion site anatomy. They found that only 20 of the papers describe the femoral insertional anatomy with 2 axes, such that the position could be defined, and they identified a wide range of PCL femoral positions.

A challenging issue in describing PCL insertional anatomy is the complex 3-dimensional (3-D) shape of the femoral notch. It remains dogma that the PCL femoral insertion site is located on the medial femoral condyle (MFC). However, recent anatomical studies have determined that the PCL inserts on the roof of the intercondylar notch (ICN; in some cases extending to the lateral portion of the notch) and on the MFC.^{1,8,12} Surgeons have described techniques for reconstructing the ligament in

Dr. Raphael is Orthopedic Fellow, Kerlan Jobe Orthopedic Clinic, Los Angeles, California.

Dr. Maak and Dr. Cross are Orthopedic Residents, Hospital for Special Surgery, New York, New York.

Dr. Plaskos is Chief Technology Officer, Praxim, East Taunton, Massachusetts.

Dr. Wickiewicz is Attending Orthopedic Surgeon, Hospital for Special Surgery.

Dr. Amis is Professor of Orthopaedic Biomechanics, Imperial College, London, England.

Dr. Pearle is Associate Attending Orthopedic Surgeon, Hospital for Special Surgery.

Address correspondence to: Andrew Pearle, MD, Hospital for Special Surgery, 535 E 70th St, New York, NY 10021 (tel, 212-774-2378; fax, 212-774-2798; e-mail, pearlea@hss.edu).

Am J Orthop. 2011;40(8):479-484.
Copyright Quadrant HealthCom Inc. 2011.
All rights reserved.

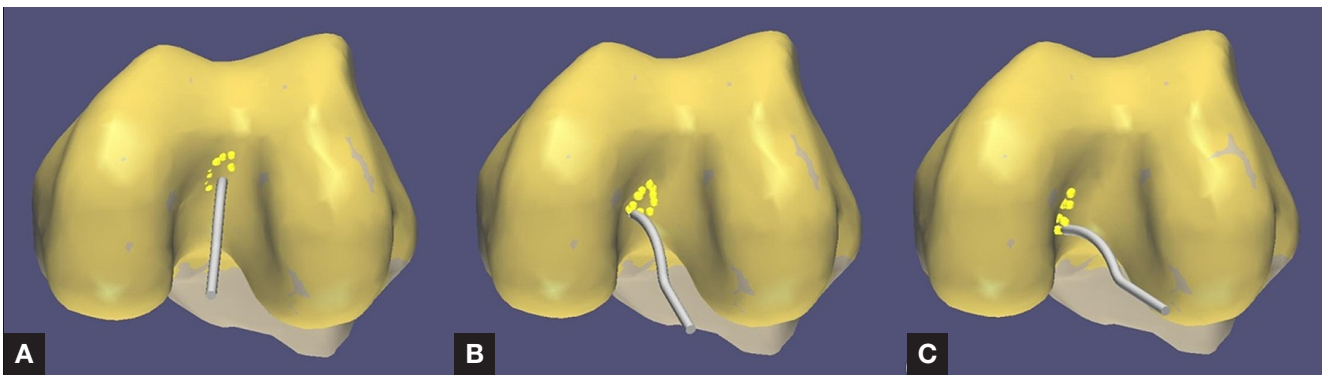


Figure 1. Three-dimensional morphology of distal femur and proximal tibia was reconstructed with Praxim (Grenoble, France) statistical bone-morphing algorithms (shown for left knee). Navigation system probe was then used to identify and carefully delineate insertion sites of anterolateral bundle (A), posteromedial bundle (B), and Humphrey ligament (C).

this anatomical position. Clancy and colleagues¹³ reported good results with anatomical reconstruction using patella tendon graft.

The roof attachment of the PCL insertion is suggested by most anatomical studies that report an o'clock position in the coronal plane as well as a depth position in the sagittal plane through measurement off the distal articular cartilage of the MFC. For example, in their review of femoral positioning recommendations, Apsingi and colleagues¹¹ determined that the AL bundle was a mean of 7 mm from the edge of the articular cartilage at the 1-o'clock position and that the PM bundle was a mean of 8 mm from the edge of the articular cartilage at the 3-o'clock position.

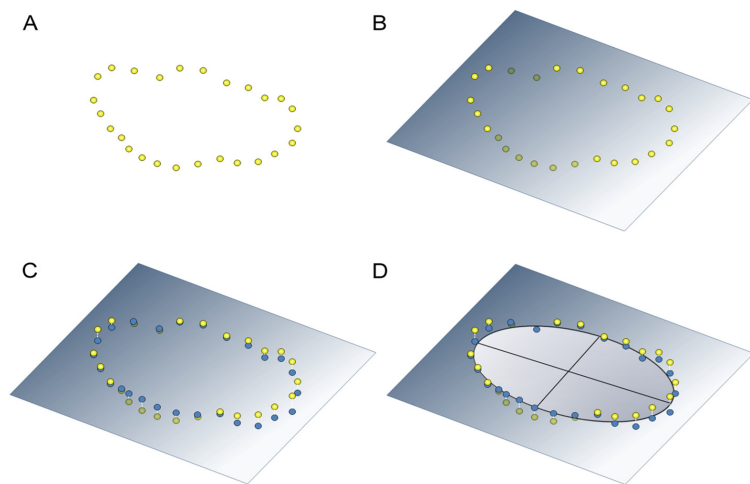


Figure 2. Algorithm used to calculate insertion areas for each bundle. (A) Points along insertion site border were carefully digitized in 3 dimensions, (B) plane of best fit to 3-D data points was calculated, (C) 3-D points were projected onto best fit plane, and (D) 2-D ellipse was fit to projected points. Area of 2-D ellipse was calculated as insertion area.

Table I. Summary of Femoral Attachment Data for Left Knee (N=7)

Parameter	Anterolateral Bundle	Posteromedial Bundle	Humphrey Ligament
Clock position of insertion site center, h:min			
Mean	10:49	9:43	9:00
SD	0:20	0:21	0:19
Minimum	10:19	9:05	8:42
Maximum	11:21	10:08	9:31
3-D distance from cartilage border, mm			
Mean	9.2	8.9	5.4
SD	1.7	2.8	1.6
Minimum	7.1	5.3	3.5
Maximum	12.0	13.3	7.5
2-D distance from cartilage border, mm			
Mean	8.3	8.5	5.0
SD	1.6	2.8	1.5
Minimum	6.1	5.0	3.0
Maximum	11.0	13.1	7.1
Attachment area, mm ²			
Mean	62.7	62.9	44.6
SD	26.3	18.0	16.3
Minimum	25.6	41.9	17.3
Maximum	102.2	96.3	62.6

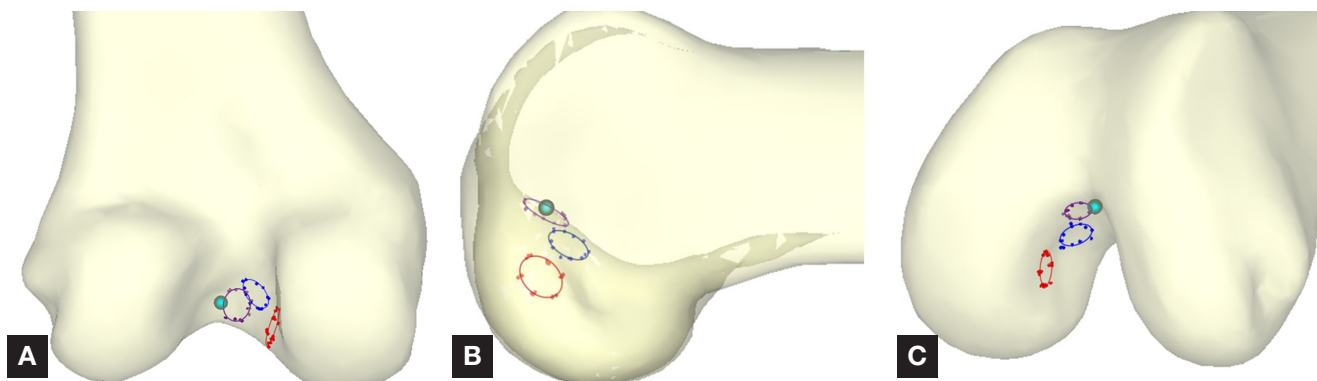


Figure 3. Posterior (A), sagittal (B), and oblique (C) views of left femur show relative positions of delineated posterior cruciate ligament insertion sites: anterolateral bundle (purple), posteromedial bundle (red), Humphrey ligament (blue). Light blue point indicates origin of coordinate system used to quantify relative centroids and spans of each insertion site in the 3 directions.

This 1-o'clock position placed the AL-bundle insertion off the wall of the MFC and onto the roof with the knee in 90° of flexion.

Adding to the confusion are the common 2-D depictions of the notch in anatomical studies and technique guides. Typically, a sagittal section displaying the MFC is shown to visually identify the femoral insertion site. The 2-D projection of these sagittal sections gives the impression of looking at the wall of the MFC. The result is that, on these commonly displayed projections, the AL-bundle and PM-bundle insertion sites appear on the wall of the MFC, not on the roof of the femoral ICN. Furthermore, this sagittal view of the wall of the condyle is typically encountered arthroscopically, which may lead surgeons to place the grafts more on the wall of the MFC than on the roof of the notch.

Computer navigation allows surgeons to view complex structures, such as the ICN, as a 3-D model from multiple perspectives. Furthermore, images obtained with computer navigation software can help surgeons gain a more lucid understanding of PCL insertional anatomy. We hypothesized that, using this software, we would find most of the PCL femoral insertion, specifically the AL bundle of the PCL, on the roof of the ICN, not on the wall of the MFC.

METHODS

In this study, 7 fresh-frozen cadavers without PCL injury or arthritis

were used. Exclusion criteria included previous surgery, gross malalignment, and ligamentous pathology. Specimens were bench-mounted, secured with a vise around the proximal femur, and positioned to allow for a free flexion cycle from 0° to 120°.

The Praxim ACL Surgetics Surgical Navigation System (Praxim Medivision, Grenoble, France) was used for morphologic data acquisition. This imageless technology provides a 3-D reconstruction of articular anatomy by acquiring points directly on the bone surface and then deforming a statistical model to fit these points. This system is accurate to 1° or 1 mm and is highly reliable in comparison with an industrial robotic sensor.¹⁴ Steinmann pins were mounted with reflective mark-

ers in the distal femur and the proximal tibia. Surface landmarks were recorded, intra-articular surface geometry was mapped, and the 3-D model was created. A medial parapatellar arthrotomy with posterior dissection was performed to identify the insertion points of the AL bundle, the PM bundle, and the HL on tibia and femur. The AL bundle, PM bundle, and HL were identified by a combination of their different tension patterns (which occur during knee range of motion) and bundle directionality. A probe was used for blunt dissection to help distinguish the bundles, and they were tagged with sutures. Then, traction was applied, and the bundles were removed from their insertions and labeled with acrylic outlines to identify indi-

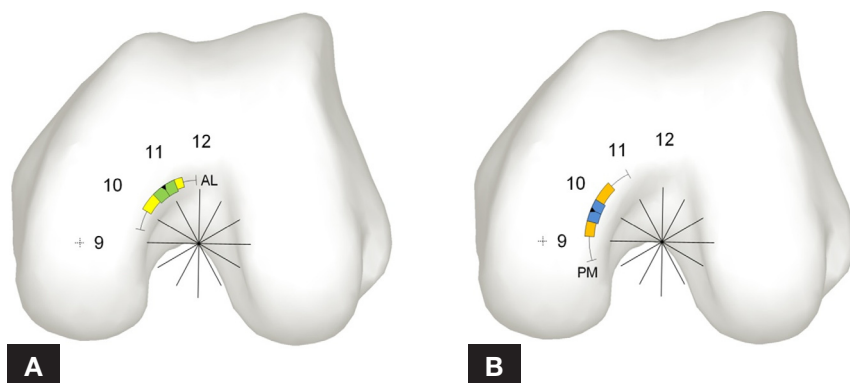


Figure 4. (A) Distribution (center, span) of insertion of bundles for left femur between 10 o'clock and 12 o'clock for anterolateral bundle (in roof of notch). Green zone, mean center (arrowhead) ± 1 SD: 10:50 \pm 0:20. Yellow zone, mean span width, minimum to maximum: 10:00 to 11:25. Error bars, range: 9:20 to 11:55. (B) Distribution (center, span) of insertion of bundles for left femur between 9 o'clock and 10:30 for posteromedial bundle. Orange zone, mean center (arrowhead) ± 1 SD: 9:45 \pm 0:20. Blue zone, mean span width, minimum to maximum: 9:00 to 10:30. Error bars, range: 8:30 to 11:00.

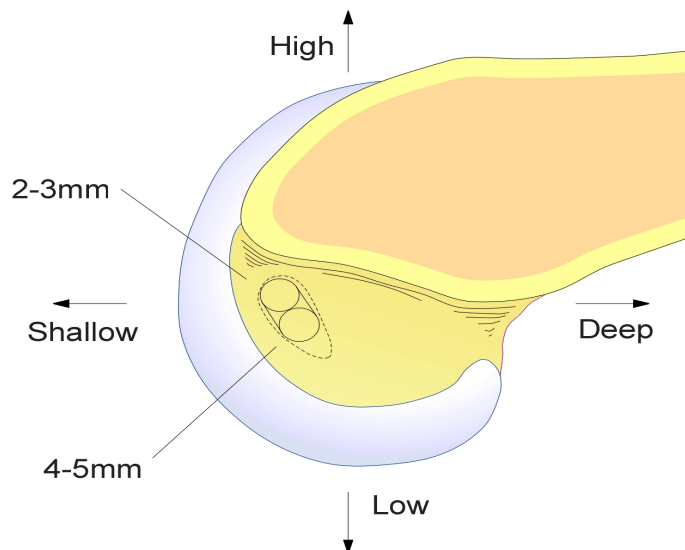


Figure 5. Authors' rendition of typical 2-dimensional sagittal image appearing in publications and technique guides shows location of posterior cruciate ligament insertion on left femur.

vidual insertion sites on tibia and femur. The entire PCL insertion was then carefully morphed with use of the navigation system digitization probe, and the borders of the bundle insertion sites were delineated (Figure 1). The centroids of the insertion sites were identified and used to create the virtual grafts.

Insertion Site Morphology

A custom algorithm was developed to calculate the insertion areas of each bundle (Figure 2). The orthogonal distance regression plane (the plane best fitting the acquired points of each bundle) was found with singular value decomposition. Acquired points were then projected on the best fit plane in the direction perpendicular to the plane. A 2-D ellipse was fit to the projected points using a least squares criterion, and the surface area of the best fit ellipse was calculated as the insertion area. Mean position of each bundle insertion was computed as the centroid of the acquired 3-D point cloud and averaged over all specimens. Maximum width (span) of each bundle was calculated in all 3 directions and averaged over all specimens. All modeling was done with Matlab (MathWorks, Natick, Massachusetts).

Distinction Between Roof and Wall

A clock face was defined in the en face view, looking from distal to proximal, with the 12-o'clock axis pointing anteriorly through the top of the notch and the 3- to 9-o'clock axis running parallel to the posterior condylar axis and through the posterior condyle circle center. The posterior condyle circle center was found by projecting the femoral bone morphing model onto the sagittal plane and fitting a circle in a least squares sense to the contour of the MFC. The clock face was fit to the notch with the knee in 90° of flexion. The roof of the ICN was defined as the region between 10 o'clock and 2 o'clock on the clock face, and the wall of the MFC was defined as the region below (low or posterior to) the 10 o'clock or 2 o'clock position for a left or right knee, respectively.

Cartilage Border

The distance from the center of each insertion to the cartilage border was

calculated. The cartilage border was identified on the bone models by delineating points along the ridge formed between the MFC and the notch wall. A polynomial curve was fit to the points, and the distance between the centroid of each ligament bundle and the cartilage border curve was computed in 2 directions: (1) along the proximodistal direction in the sagittal view (1-D distance) and (2) along the mediolateral and proximodistal directions (2-D distance) in the coronal plane containing the insertion centroid.

Three-Dimensional Obliquity

The navigation system was used to simulate virtual graft reconstructions, and a cylindrical software tool was used to generate virtual fibers to create grafts with the center of the AL bundle, the PM bundle, and the HL. The software allows straight-line virtual grafts of various diameters to be created in different anatomical positions. These rigid virtual grafts extend from the aperture of the tibial insertion site to that of the femoral insertion site. The previously defined centroids were used to create the centroids of the virtual grafts. A virtual graft 9 mm in diameter was used for the bundle simulation for all reconstructions. The 3-D obliquity of the virtual grafts was determined with the knee in full extension and at 90° of flexion. The coordinate system used to compute the obliquity was determined using the references acquired by the navigation system. Specifically, the obliquity angle of each bundle was calculated in the coronal plane with respect to the mediolateral axis of the tibia, which was defined to be orthogonal to the tibial mechanical axis. The obliquity angles were then

Table II. Summary of Tibial Attachment Data (N=7)

Attachment Area, mm ²	Anterolateral Bundle	Posteromedial Bundle	Humphrey Ligament
Mean	57.5	73.2	38.2
SD	9.0	16.6	17.3
Minimum	42.1	44.7	21.7
Maximum	69.5	97.9	70.9

determined referencing these planes rather than anatomical reference points on the proximal tibia.

RESULTS

Insertion Site Morphology

Mean insertion site areas on the femur were 63 mm² (AL bundle), 63 mm² (PM bundle), and 45 mm² (HL) (Table I), and mean insertion site areas on the tibia were 57.4 mm² (AL bundle), 73.2 mm² (PM bundle), and 38.2 mm² (HL) (Table II).

Insertion Site Location

Femoral attachment data are summarized in Table I. Mean centroids (o'clock position) over all specimens of AL bundle, PM bundle, and HL were, respectively, 10:49, 9:43, and 9:00 on the left knee and 1:11, 2:17, and 3:00 on the right knee. Mean (SD) centroid positions for the AL and PM bundles are depicted in Figure 3. In 5 of the 7 specimens tested, 100% of the AL bundle originated on the roof of the ICN. In the other 2 specimens, 85% of the AL bundle originated on the roof (mean, 95% across all specimens). Four of the 7 specimens tested had 40% to 60% of the PM bundle originating on the roof of the notch (mean, 34% across all specimens), whereas in all specimens the HL originated on the wall of the MFC.

Angle of Inclination of PCL in Coronal Plane

For the AL bundle, mean (SD) angle of inclination in the coronal plane was 78° (12.6°) in full extension and 87° (7°) in 90° of flexion. This suggests that the AL bundle of the PCL runs almost directly in the sagittal plane in 90° of flexion. For the PM bundle, the mean (SD) angle was 71° (10°) in full extension and 80° (12°) in 90° of flexion. For the HL, the mean (SD) angle was 46° (23°) in full extension and 62° (23°) in 90° of flexion.

DISCUSSION

Using computer navigation software, we have demonstrated that

most of the insertion of the AL bundle of the PCL is on the roof of the ICN rather than on the wall of the MFC.^{1,8,12} Furthermore, the PM bundle was centered near the transition area between the roof and the wall of the MFC. On the other hand, the HL typically inserted on the wall of the MFC (Figure 4).

We have also demonstrated that the coronal plane angle of inclination of the AL bundle is almost 90°. This further supports the concept that the stout AL bundle runs directly posterior to anterior in the sagittal plane. For this to be true, the fibers must attach on the roof of the notch rather than slant across the knee to the wall of the MFC. We suggest that this sagittal orientation of the bulk of the AL fibers results in the excellent "in-plane" PCL visualization that is common on sagittal magnetic resonance imaging.

The HL reliably inserted on the side wall of the MFC. This, along with the more lateral position of its insertion site on the posterior horn of the lateral meniscus, gave it a slanting appearance compared with the direct posterior-to-anterior angle of inclination of the PCL. Placing a PCL tunnel on the side wall of the MFC may reproduce this nonanatomical slanting orientation of the meniscofemoral ligament.

PCL reconstruction can be a technically difficult procedure. Many investigators have described techniques, including use of osseous landmarks and distance from the articular cartilage border, that aid with tunnel placement.¹⁵⁻¹⁷ We believe that the common animations and classic anatomical pictures featuring a 2-D sagittal view of the MFC misleadingly suggest a predominant side-wall position for the femoral insertion of the PCL (Figure 5), as the femoral insertion site extends in 3-D into the notch and lateral to what is suggested in 2-D. Although the descriptions of proper tunnel placement in these technique guides are accurate—the

bundles are described from the articular cartilage in the o'clock position—the 2-D images in these guides fail to highlight the large roof insertion of the footprint. We believe these images may mislead orthopedic surgeons and potentially lead to an error in tunnel placement. We believe the anatomy is best represented by looking "up" at the notch, from posterior to anterior (Figures 1, 4). Therefore, arthroscopic visualization of the PCL should likely be directed toward the roof of the notch as well as the wall of the MFC.

Commonly used "rear-entry" PCL femoral guides are designed such that the tunnel is drilled from the cortex of the MFC into the PCL insertion site. When surgeons drill the outside-in tunnel with rear-entry guides and a limited exposure, they may be encouraged to place the tunnel on the larger, more distal region of the MFC cortex. This relative distal position on the MFC may bias surgeons to place the femoral tunnel on the wall rather than on the roof of the notch. Drilling through a lateral portal, or outside-in drilling with a proximal starting point on the MFC—proximal and anterior to the medial epicondyle, approaching the medial aspect of the patellofemoral joint—may facilitate creating a femoral tunnel in the roof of the ICN.

This study has several limitations. First, as this is the first computer-navigated description of the PCL insertion site, we have defined a relatively arbitrary delineation between the wall of the MFC and the roof of the notch. However, currently there is no definition as to where the roof ends and the side wall begins; there is only subjective judgment. We standardized the definition by establishing precise coordinates for a clock face to quantify the transition between the 2 bony regions. In retrospectively reviewing the data, we found that the transition between the AL and PM bundles of the PCL femo-

ral insertion sites may be a reasonable means of identifying this transition. In addition, we used a limited number of cadaver knees. Nonetheless, our o'clock data and the data concerning distance from the cartilage border are similar to data from other studies.¹¹

Recently, there has been a movement in anterior cruciate ligament surgery toward a more "anatomical" approach—bringing the anterior cruciate ligament femoral tunnel position from the roof of the notch to the side wall of the lateral femoral condyle. Ironically, an opposite movement may be necessary in anatomical PCL surgery—from a side-wall-based femoral PCL tunnel to a more anatomical roof tunnel. Furthermore, we believe that distinguishing the roof of the notch from the wall of the MFC is feasible arthroscopically and may simplify PCL femoral tunnel positioning.

AUTHORS' DISCLOSURE STATEMENT

The authors would like to disclose that Christopher Plaskos, PhD, is an employee of Praxim, East Taunton, Massachusetts, and par-

ticipated in the study design, manuscript preparation, and review of the manuscript prior to submission. The other authors report no actual or potential conflict of interest in relation to this article.

REFERENCES

1. Amis AA, Gupte CM, Bull AM, Edwards A. Anatomy of the posterior cruciate ligament and the menisofemoral ligaments. *Knee Surg Sports Traumatol Arthrosc.* 2006;14(3):257-263.
2. Race A, Amis AA. PCL reconstruction. In vitro biomechanical comparison of 'isometric' versus single and double-bundled 'anatomic' grafts. *J Bone Joint Surg Br.* 1998;80(1):173-179.
3. Harner CD, Janaushek MA, Kanamori A, Yagi M, Vogrin TM, Woo SL. Biomechanical analysis of a double-bundle posterior cruciate ligament reconstruction. *Am J Sports Med.* 2000;28(2):144-151.
4. Mannor DA, Shearn JT, Grood ES, Noyes FR, Levy MS. Two-bundle posterior cruciate ligament reconstruction. An in vitro analysis of graft placement and tension. *Am J Sports Med.* 2000;28(6):833-845.
5. Race A, Amis AA. The mechanical properties of the two bundles of the human posterior cruciate ligament. *J Biomech.* 1994;27(1):13-24.
6. Race A, Amis AA. Loading of the two bundles of the posterior cruciate ligament: an analysis of bundle function in a-P drawer. *J Biomech.* 1996;29(7):873-879.
7. Kusayama T, Harner CD, Carlin GJ, Xerogeanes JW, Smith BA. Anatomical and biomechanical characteristics of human menisofemoral ligaments. *Knee Surg Sports Traumatol Arthrosc.* 1994;2(4):234-237.
8. Edwards A, Bull AM, Amis AA. The attachments of the fiber bundles of the posterior cruciate ligament: an anatomic study. *Arthroscopy.* 2007;23(3):284-290.
9. Mauro CS, Sekiya JK, Stabile KJ, Haemmerle MJ, Harner CD. Double-bundle PCL and posterolateral corner reconstruction components are codominant. *Clin Orthop.* 2008;466(9):2247-2254.
10. Ahmad CS, Cohen ZA, Levine WN, Gardner TR, Ateshian GA, Mow VC. Codominance of the individual posterior cruciate ligament bundles. An analysis of bundle lengths and orientation. *Am J Sports Med.* 2003;31(2):221-225.
11. Apsingi S, Bull AM, Deehan DJ, Amis AA. Review: femoral tunnel placement for PCL reconstruction in relation to the PCL fibre bundle attachments. *Knee Surg Sports Traumatol Arthrosc.* 2009;17(6):652-659.
12. Amis AA. Anatomy and biomechanics of the posterior cruciate ligament. *Sports Med Arthrosc Rev.* 1999;7:225-234.
13. Clancy WG Jr, Shelbourne KD, Zoellner GB, Keene JS, Reider B, Rosenberg TD. Treatment of knee joint instability secondary to rupture of the posterior cruciate ligament. Report of a new procedure. *J Bone Joint Surg Am.* 1983;65(3):310-322.
14. Pearle AD, Solomon DJ, Wanich T, et al. Reliability of navigated knee stability examination: a cadaveric evaluation. *Am J Sports Med.* 2007;35(8):1315-1320.
15. Lopes OV Jr, Ferretti M, Shen W, Ekdahl M, Smolinski P, Fu FH. Topography of the femoral attachment of the posterior cruciate ligament. *J Bone Joint Surg Am.* 2008;90(2):249-255.
16. Takahashi M, Matsubara T, Doi M, Suzuki D, Nagano A. Anatomical study of the femoral and tibial insertions of the anterolateral and posteromedial bundles of human posterior cruciate ligament. *Knee Surg Sports Traumatol Arthrosc.* 2006;14(11):1055-1059.
17. Forsythe B, Harner C, Martins CA, Shen W, Lopes OV Jr, Fu FH. Topography of the femoral attachment of the posterior cruciate ligament. Surgical technique. *J Bone Joint Surg Am.* 2009;91(suppl 2, pt 1):89-100.

THIS MONTH'S AUDIOCAST



—Kevin D. Plancher, MD
Associate Clinical Professor,
Albert Einstein College of
Medicine
Fellowship Director
Plancher Orthopaedics &
Sports Medicine
New York, NY

Visit www.amjorthopedics.com to hear Editorial Review Board Member **Kevin Plancher, MD**, give details regarding the inaugural *Emerging Techniques in Orthopedics: Sports Medicine and Arthroscopic Surgery* conference he is chairing December 8-10 in Las Vegas.

What will *Emerging Techniques in Orthopedics* offer that other sports medicine meetings don't?

We want to raise the same questions that are raised at other events, except we believe we can answer these questions through our outstanding, all-star faculty. It's a "no holds barred" kind of conference. We are allowing the speakers to challenge each other, with moderators such as Russell Warren, MD, and Richard Hawkins, MD. As these honored professors have no fear to challenge the speakers as well, we can come up with really concise treatment plans. It also makes it very different from other sports medicine meetings—where sometimes we learn good information but walk away still confused about which way we should tackle a problem.