

# Mini-Open Versus Open Decompression and Fusion for Lumbar Degenerative Spondylolisthesis With Stenosis

Eric B. Harris, MD, Amirali Sayadipour, MD, Patrick Massey, MD, Neil Leon Duplantier, BS, and D. Greg Anderson, MD

## Abstract

The outcome of less invasive surgical techniques in comparison to traditional surgical techniques has been the source of debate. In this retrospective study, 51 patients who had undergone posterior lumbar fusion along with bilateral decompression were enrolled. Twenty-one patients underwent fusion using a standard, midline open technique (open group) and 30 patients underwent fusion using a mini-open technique, with a small, central incision for the decompression and bilateral paramedian incisions for the posterolateral fusion and placement of cannulated pedicle screws (mini-open group).

Surgical variables were compared between the 2 groups. Patients in both groups experienced significant improvements in leg pain at 12 months, with a reduction in visual analog scale scores from 7.6 to 2.4 in the open group, and 7.8 to 2.3 in the mini-open group. There were no statistical differences between the groups in the magnitude of improvement of either the visual analog scale or Oswestry Disability Index scores. Operative times, blood loss, and length of hospitalization failed to show statistically significant differences between the groups, although there was a trend toward less blood loss and shorter hospitalization in the mini-open group. Fusion results and complications were similar between the 2 groups. Both techniques resulted in similarly statistically significant improvements in pain and clinical function.

Dr. Harris is Staff Orthopaedic Surgeon, Department of Orthopaedics, Naval Medical Center San Diego, San Diego, California.

Dr. Sayadipour is Research Fellow, Section of Minimally Invasive Spine Surgery, Thomas Jefferson University and Rothman Institute, Philadelphia, Pennsylvania.

Dr. Massey is Orthopaedic Resident, Department of Orthopaedics, and Mr. Duplantier is Orthopaedic Resident, School of Medicine, Louisiana State University Health Sciences Center, Shreveport, Louisiana.

Dr. Anderson is Associate Professor, Department of Orthopaedic Surgery, Thomas Jefferson University and Rothman Institute.

Address correspondence to: D. Greg Anderson, MD, Department of Orthopaedic Surgery, Thomas Jefferson University and Rothman Institute, 925 Chestnut St, 5th Floor, Philadelphia, PA 19107 (tel, 267-339-3620; fax, 215-503-0580; e-mail, davidgreganderson@comcast.net).

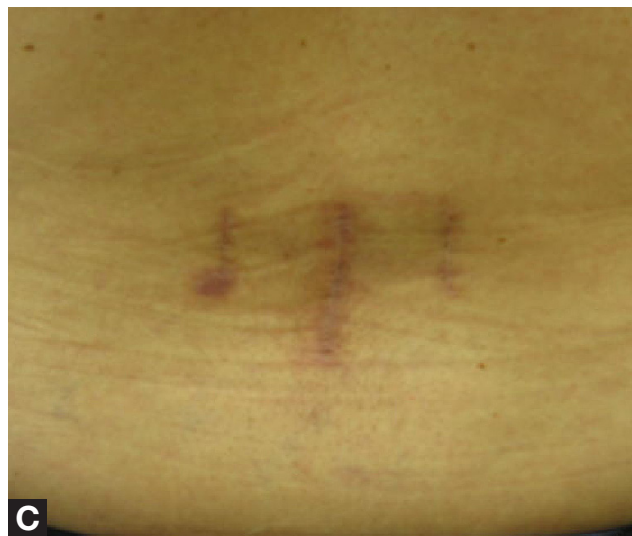
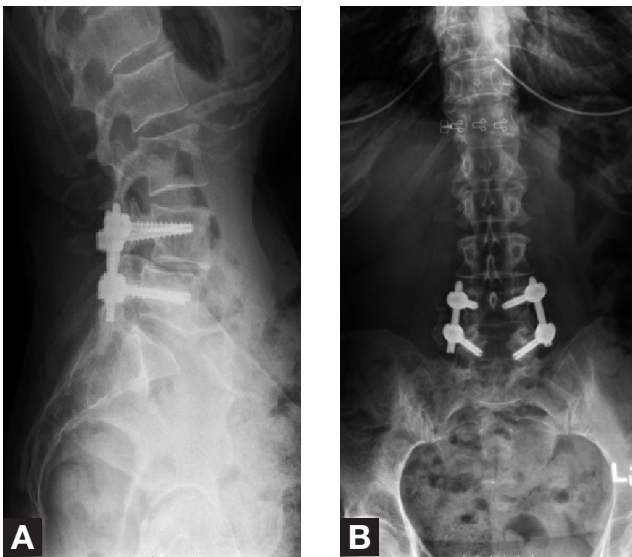
*Am J Orthop.* 2011;40(12):E257-E261. Copyright Quadrant HealthCom Inc. 2011. All rights reserved.

Decompression and posterior fusion constitute a well-accepted treatment approach in cases in which lumbar degenerative spondylolisthesis with stenosis has been unresponsive to nonsurgical measures.<sup>1</sup> This operation traditionally is performed through an open midline approach. Although that approach is effective in managing the primary symptoms of the spinal disorder,<sup>2</sup> it has the drawback of requiring moderately invasive posterior dissection of the paraspinal musculature. Since the recent introduction of cannulated pedicle screws for percutaneous instrumentation, surgeons have been able to use small paramedian incisions for posterior fusion and insertion of pedicle screw instrumentation. This approach is thought by some to be less invasive than the traditional, midline approach.<sup>3-5</sup> Up until now, no one has compared the techniques using patient-based outcome measures.

In the study reported here, we compared surgical variables and preoperative and postoperative visual analog scale (VAS) and Oswestry Disability Index (ODI) scores for 2 groups of patients surgically treated for degenerative spondylolisthesis with stenosis. Both groups underwent decompression and instrumented posterolateral fusion. In the open group, a traditional midline approach was used; in the mini-open group, a small midline incision was used for decompression, and bilateral paramedian incisions were used for posterior fusion and insertion of instrumentation.

## MATERIALS AND METHODS

After obtaining institutional review board (IRB) approval, we retrospectively and systematically reviewed the patient charts in 51 consecutive cases of symptomatic single-level lumbar degenerative spondylolisthesis with stenosis managed with decompression and posterior lumbar fusion with instrumentation at the L4-L5 level using 2 different techniques, open and mini-open. In the open group (21 patients), the operation was performed through a standard midline incision. In the mini-open group (30 patients), a small midline incision was made for decompression, and posterior fusion was performed through small, bilateral paramedian incisions along with insertion of cannulated pedicle screw instrumentation. In each case, the surgical technique was chosen by the surgeon and the patient, and no randomization was performed.

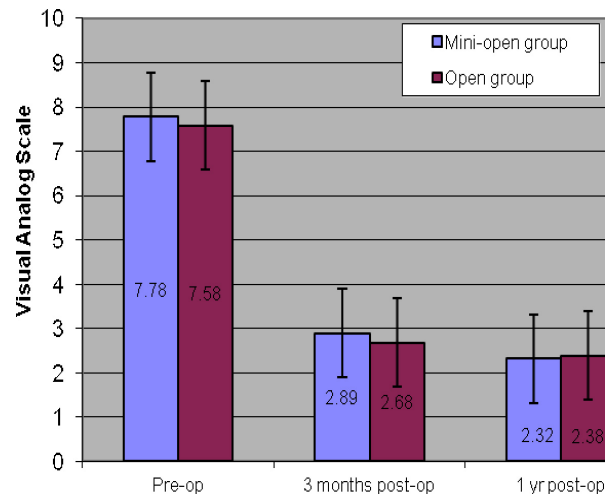


**Figure 1.** Anteroposterior (A) and lateral (B) radiographs of patient who underwent mini-open decompression and posterolateral fusion with percutaneous instrumentation. (C) Skin incisions for decompression (midline) and posterolateral fusion and instrumentation (2 paramedian incisions).

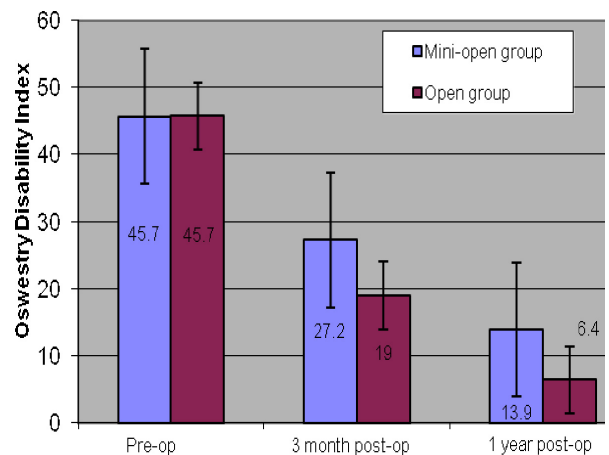
All surgeries were performed by the senior author (D.G.A.). Patients in both groups mainly reported symptoms of neurogenic claudication prior to surgery. In all cases, surgery was performed only after nonsurgical measures (physical therapy, nonsteroidal anti-inflammatory therapy, epidural steroid injections) had been unsuccessful over a period of 6 months or more.

### Open Technique

In the open group, a midline incision 4 inches to 6 inches long was made, and the paraspinal muscles were dissected away from the involved vertebrae to the tips of the transverse processes. Laminectomy and medial facetectomy were performed to decompress the neural elements. A freehand technique was used to insert pedicle screws into the pedicles of the cephalad and caudal vertebrae of the



**Figure 2.** Mean visual analog scale scores for open and mini-open groups before surgery (preop) and at 3-month and 1-year follow-ups.



**Figure 3.** Mean Oswestry Disability Index scores for open and mini-open groups before surgery (preop) and at 3-month and 1-year follow-ups.

spondylolisthesis, and autogenous bone graft was laid between the decorticated transverse processes for the posterolateral fusion.

### Mini-Open Technique

In the mini-open group, a 1.5-in to 2-in midline incision was made, and muscle dissection was carried out only to the medial portions of the facet joints, allowing laminectomy and medial facetectomy to be performed. Separate, bilateral paramedian incisions, approximately 1.5 inches long, were made 1 cm lateral to the pedicle shadow on a true anteroposterior (AP) fluoroscopic image of the cephalad vertebrae, and a muscle-splitting approach was used to expose the intertransverse interval. The transverse processes were decorticated and grafted with autogenous

**Table I. Mean Estimated Blood Loss, Duration of Surgery, and Length of Hospital Stay for Mini-Open and Open Groups**

Group	Blood Loss, mL	Duration of Surgery, min	Length of Stay, d
Mini-open	208	150	2.5
Open	335	156	3.2
<i>P</i> value	0.107	0.33	0.19

**Table II. Mean Scale Scores for Mini-Open and Open Groups**

Group	Visual Analog Scale Score (Range, 1-10)			Oswestry Disability Index Score (Range, 1-100)		
	Before Surgery	3-Month Follow-Up	1-Year Follow-Up	Before Surgery	3-Month Follow-Up	1-Year Follow-Up
Mini-open	7.78	2.89	2.32	45.7	27.2	13.9
Open	7.58	2.68	2.38	45.7	19.0	6.4
<i>P</i> value	0.74	0.85	0.95	0.92	0.26	0.19

bone graft. Next, the pedicles were cannulated with Jamshidi needles under fluoroscopic assistance, and guide wires were placed. Finally, cannulated pedicle screws and rods were implanted and secured (Figures 1A–1C).

#### Data Collection and Outcome Measures

Independent investigators (not the operating surgeon) collected all the data from patient medical records. Data included age, sex, diagnosis, amount of intraoperative blood loss, duration of surgery, length of hospital stay, and postoperative complications. All patients had provided preoperative and postoperative VAS scores (for leg pain) and ODI scores under an IRB-approved prospective spinal surgery database. Postoperative AP and lateral radiographs were evaluated for fusion at 12 months. Fusion was graded “solid” when both of 2 conditions were apparent: continuous posterolateral bone bridging between the transverse processes (as seen on AP radiograph) and absence of radiolucency at the bone–hardware interface. When the conditions were not apparent, the fusion was graded “failed.”

#### Statistical Methods

For statistical analysis, a 2-sample *t* test was used. The variables that were compared between the open and mini-open groups included blood loss, duration of surgery, length of hospital stay, and change in VAS and ODI scores. Statistical significance was set at  $P < .05$ .

## RESULTS

Mean age was 69.1 years in the open group and 66 years in the mini-open group. Of the 21 patients in the open group, 12 (57%) were females, and 9 (43%) were males. Of the 30 patients in the mini-open group, 20 (67%) were females, and 10 (33%) were males.

Mean blood loss was 335 mL in the open group and 208 mL in the mini-open group ( $P = .107$ ) (Table I). Mean duration of surgery (defined as time from skin

incision to placement of surgical dressing) was 156 minutes in the open group and 150 minutes in the mini-open group ( $P = .33$ ) (Table I). Mean length of hospital stay was 3.2 days in the open group and 2.5 days in the mini-open group ( $P = .19$ ) (Table I).

Clinical outcome was measured with VAS (leg pain) and ODI scores. Mean preoperative VAS score was 7.58 in the open group and 7.78 in the mini-open group ( $P = .74$ ). By 3-month follow-up, mean VAS score had improved to 2.68 in the open group and 2.89 in the mini-open group. By 1-year follow-up, this score had improved further, to 2.38 in the open group and 2.32 in the mini-open group. Thus, both groups' mean VAS score showed statistically significant improvement from before surgery to 3 months and 1 year after surgery ( $P < .05$ ). However, there were no statistically significant differences in improvement between the groups at either follow-up ( $P = .95$ ) (Table II, Figure 2).

Each group's mean preoperative ODI score was 45.7 (consistent with severe disability). By 3-month follow-up, mean ODI score had improved to 27.2 (moderate disability) in the mini-open group and 19.0 (minimal disability) in the open group. By 1-year follow-up, mean ODI score had improved further, to 6.4 (minimal disability) in the open group and 13.9 (minimal disability) in the mini-open group. Thus, both groups' mean ODI score showed statistically significant improvement from before surgery to 3 months and 1 year after surgery ( $P < .05$ ). However, there were no statistically significant differences in improvement between the groups at either follow-up ( $P = .19$ ) (Table II, Figure 3).

There were only 2 fusion failures. In the open group, 1 patient showed isolated radiolucency around 1 of the L4 pedicle screws, as well as lack of bridging posterolateral bone graft on the AP radiograph. In the mini-open group, 1 patient showed radiolucency around 1 of the L5 screws, as well as lack of bridging bone between the L4 and L5 transverse processes.

There were 5 complications: 1 dural tear (repaired primarily) and 1 deep wound infection (managed with irrigation, debridement, primary closure over drains, and a 6-week course of intravenous antibiotics) in the open group, plus 2 dural tears (repaired primarily) and 1 postoperative deep vein thrombosis (managed with warfarin) in the mini-open group.

## DISCUSSION

We retrospectively reviewed 51 cases of degenerative spondylolisthesis with stenosis managed with decompression and instrumented fusion through 2 different surgical approaches. One of these approaches, the mini-open, is thought by some to be less invasive and to require less muscle stripping from the posterior column of the spine. To our knowledge, the present study is the first to use validated patient-based outcome measures to compare these 2 techniques. Results showed that both techniques provided significant improvements in pain and function; however, the techniques were equivalent in their ability to produce these clinical improvements at 3-month and 1-year follow-ups.

Other authors have evaluated the effectiveness of minimally invasive surgery in managing degenerative spondylolisthesis with stenosis. In a study of 37 patients who underwent microendoscopic decompression without fusion, Ikuta and colleagues<sup>6</sup> found that outcomes at a mean follow-up of 2 years were excellent in 20 patients (54%) and good in 7 patients (19%). However, the remaining 7 patients (19%) showed signs of progressive slippage of the spondylolisthesis, and 1 of these underwent fusion within the study follow-up period. Although this technique warrants further study, many surgeons routinely use fusion for patients with degenerative spondylolisthesis with stenosis because of the potential for progressive slippage and poorer outcomes, as reported by Herkowitz and Kurz<sup>1</sup> in a prospective randomized trial.

Researchers have evaluated other fusion techniques in this patient population. These techniques include posterior lumbar interbody fusion (PLIF), transforaminal lumbar interbody fusion (TLIF), and anterior/posterior fusion. In a recently reported study, prospectively collected Spine Patient Outcomes Research Trial data were used to evaluate various fusion techniques for managing degenerative spondylolisthesis; these techniques showed no consistent differences in outcome.<sup>7</sup> Use of less invasive interbody fusion techniques has been studied in small clinical reports. Tsutsumimoto and colleagues<sup>8</sup> compared outcomes in 10 patients who underwent either standard midline PLIF or mini-open PLIF performed through bilateral Wiltse incisions. The 2 groups' outcomes, as measured by Japanese Orthopaedic Association scores and radiographic parameters, were not statistically different. However, magnetic resonance imaging showed less muscle atrophy after mini-open PLIF. Dhall and colleagues<sup>9</sup> compared use of mini-open

TLIF and traditional TLIF in managing spondylolisthesis. Mean blood loss and length of hospital stay were statistically better in the mini-open group, though the clinical outcomes as measured by Prolo Scale scores were not statistically different between the 2 techniques. Our results are similar to those of these studies, in that the outcomes of surgical approaches were not statistically different.

One variable that was not specifically measured, but must be considered, is patient and surgical team exposure to ionizing radiation. In our study, C-arm fluoroscopy was used for pedicle cannulation in the mini-open group, but fluoroscopy was not used in the open group. In the open group, 2 lateral radiographs were obtained, 1 for localization of spinal levels and 1 for evaluation of instrumentation position. Although radiation levels were not specifically measured, patient exposure with the open and mini-open techniques is likely similar. However, the surgical team received more radiation during the mini-open procedure (from use of C-arm fluoroscopy) than during the open procedure because the surgical team members repositioned themselves behind a lead shield during plain radiography. In future studies, the amount of radiation exposure should be measured and compared when considering the pros and cons of a fluoroscopically based technique.

Our study has several limitations. First, it was retrospective, though the patient-based outcome data were collected prospectively as part of an established spinal surgery database. Second, there was no randomization, though the groups showed a similar distribution of age, sex, diagnosis, and degree of disability and pain, and all operations were performed by the same surgeon. Third, very early clinical outcome data were not collected; it is possible that there are early advantages with the less invasive treatment and that these advantages were not evident given the number of patients in this study at the 3-month and 1-year follow-ups. Last, radiation exposure was not measured; therefore, the techniques cannot be compared with respect to this factor.

## CONCLUSION

Our study results suggest that open exposure (traditional midline incision) and mini-open exposure (3 small incisions) are effective treatment options for patients with symptomatic degenerative spondylolisthesis with stenosis. These techniques are equally effective in providing statistically significant improvement in leg pain (VAS scores) and function (ODI scores) at 3-month and 1-year follow-ups. Therefore, the approach chosen to manage this condition remains a matter of surgeon and patient preference.

## AUTHORS' DISCLOSURE STATEMENT

The authors report no actual or potential conflict of interest in relation to this article.

## REFERENCES

1. Herkowitz HN, Kurz LT. Degenerative lumbar spondylolisthesis with spinal stenosis. A prospective study comparing decompression with decompression and intertransverse process arthrodesis. *J Bone Joint Surg Am*. 1991;73(6):802-808.
2. Weinstein JN, Lurie JD, Tosteson TD, et al. Surgical compared with non-operative treatment for lumbar degenerative spondylolisthesis. Four-year results in the Spine Patient Outcomes Research Trial (SPORT) randomized and observational cohorts. *J Bone Joint Surg Am*. 2009;91(6):1295-1304.
3. Foley KT, Holly LT, Schwender JD. Minimally invasive lumbar fusion. *Spine*. 2003;28(15 suppl):S26-S35.
4. Park Y, Ha JH. Comparison of one-level posterior lumbar interbody fusion performed with a minimally invasive approach or a traditional open approach. *Spine*. 2007;32(5):537-543.
5. Thomsen K, Christensen FB, Eiskjaer SP, Hansen ES, Fruensgaard S, Bünger CE. 1997 Volvo Award winner in clinical studies. The effect of pedicle screw instrumentation on functional outcome and fusion rates in posterolateral lumbar spinal fusion: a prospective, randomized clinical study. *Spine*. 1997;22(24):2813-2822.
6. Ikuta K, Tono O, Oga M. Clinical outcome of microendoscopic posterior decompression for spinal stenosis associated with degenerative spondylolisthesis—minimum 2-year outcome of 37 patients. *Minim Invasive Neurosurg*. 2008;51(5):267-271.
7. Abdu WA, Lurie JD, Spratt KF, et al. Degenerative spondylolisthesis: does fusion method influence outcome? Four-year results of the Spine Patient Outcomes Research Trial. *Spine*. 2009;34(21):2351-2360.
8. Tsutsumimoto T, Shimogata M, Ohta H, Misawa H. Mini-open versus conventional open posterior lumbar interbody fusion for the treatment of lumbar degenerative spondylolisthesis: comparison of paraspinal muscle damage and slip reduction. *Spine*. 2009;34(18):1923-1928.
9. Dhall SS, Wang MY, Mummaneni PV. Clinical and radiographic comparison of mini-open transforaminal lumbar interbody fusion with open transforaminal lumbar interbody fusion in 42 patients with long-term follow-up. *J Neurosurg Spine*. 2008;9(6):560-565.