

Orthopedic Surgery Is Possible in Hemophilic Patients With Inhibitors

E. Carlos Rodríguez-Merchán, MD, PhD

Abstract

Hemophilia is an inherited recessive sex-linked bleeding disorder. An insufficiency of coagulation factor VIII produces hemophilia A, and lack of factor IX causes hemophilia B. Prevention and management of the disease require intravenous infusion of the deficient factor. Worldwide, hemophilia affects approximately 600,000 people, 20% of whom develop antibodies against the deficient coagulation factor. Hemophilic patients with inhibitors present with multiarticular joint degeneration (hemophilic arthropathy) secondary to recurrent hemarthroses. The availability of activated prothrombin complex concentrates and activated recombinant factor VII allows hemophilic patients with high inhibitor titers to undergo elective orthopedic surgery with a high expectation of success, and thorough individual case analysis by a multidisciplinary team allows surgeons to obtain satisfactory results. However, the rate of potential complications must not be underestimated.

Development of an inhibitor against factor VIII (FVIII) or factor IX (FIX) is the most common and most serious complication of replacement therapy in patients with hemophilia A or B. The rate of inhibitor development is approximately 20%.

Two approaches to treating patients with inhibitors have been proposed. Immune tolerance induction using high-dose FVIII or FIX daily or twice daily for a period ranging from a few months to several years may completely eliminate the inhibitor and allow the patient to be treated efficiently with FVIII or FIX again.^{1,2} However, immune tolerance induction fails in approximately 20% of cases and is not recommended for all patients because of the high probability of failure or adverse events. Furthermore, this procedure is costly. The other proposed approach to treating patients with inhibitors is to manage bleeding episodes with activated prothrombin complex concentrates (APCCs), such as “factor eight inhibitor bypassing activity” (FEIBA),³⁻⁵

or with activated recombinant factor VII (rFVIIa; NovoSeven, Novo Nordisk A/S, Bagsværd, Denmark).⁶⁻⁹ Should APCCs or rFVIIa fail to manage life- or limb-threatening bleeds, or fail as first-line management for major bleeds, surgeons can consider high-dose human¹⁰ or porcine¹¹ FVIII or human FIX, which may be efficacious when the inhibitor is low or is lowered using plasmapheresis¹² or protein A immunoabsorption.¹³ However, the anamnestic rise of the inhibitor renders management with FVIII or FIX ineffective within a few days, making the patient resistant to rescue with FVIII or FIX for months or even years.

For acute hemarthrosis in patients with inhibitors, hematologic management must be maintained until bleeding goes into full remission and the patients have recovered as much of their preoperative range of motion and muscular strength as possible. Such a regimen, which can take up to 3 months, has come to be known as *enhanced on-demand treatment*. In this connection, ultrasonography is a reliable, economical, and easy-to-use method for diagnosing hemarthrosis and following up on its evolution.¹⁴

ORTHOPEDIC SURGERY IN HEMOPHILIC PATIENTS WITH INHIBITORS

Between the second and fourth decades of life, many hemophilic patients develop arthropathy. At this stage, possible treatments include alignment osteotomy,

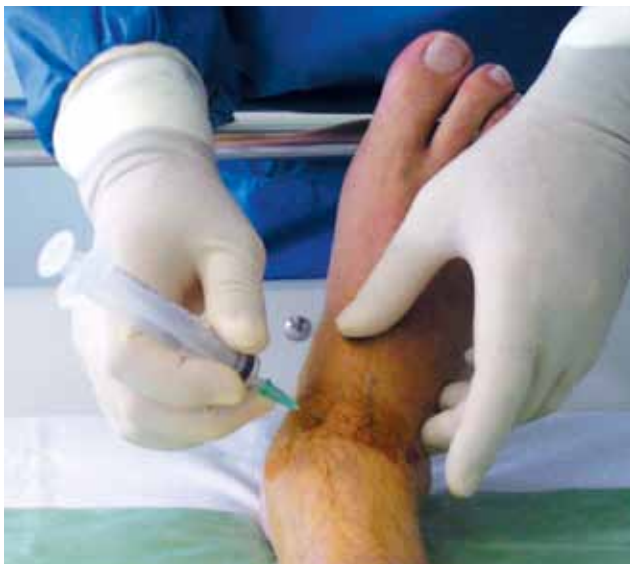

Figure 1. Radiosynovectomy (rhenium-186) of ankle in patient with inhibitor and chronic hemophilic synovitis.

Dr. Rodríguez-Merchán is Consultant Orthopaedic Surgeon, Associate Professor of Orthopaedic Surgery, Department of Orthopaedic Surgery, La Paz University Hospital, Madrid, Spain.

Address correspondence to: Prof. E. C. Rodríguez-Merchán, Department of Orthopaedic Surgery, La Paz University Hospital, Paseo de la Castellana 261, 28046-Madrid, Spain (tel, +34-606712724; fax, +34-91-5712871; e-mail, ecmerchan@gmx.es).

Am J Orthop. 2012;41(12):570-574. Copyright Frontline Medical Communications Inc. 2012. All rights reserved.

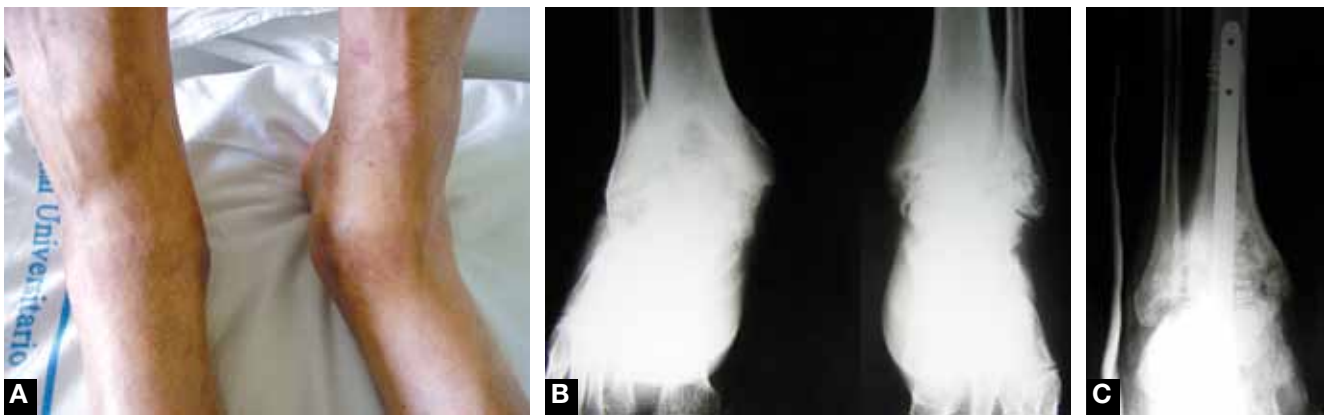


Figure 2. Patient with inhibitor underwent right ankle arthrodesis with locked retrograde intramedullary nail. (A) Preoperative clinical view shows severe arthropathy. (B) Radiographs confirm intense hemophilic arthropathy of ankles (more severe in right ankle). (C) Postoperative anteroposterior view shows satisfactory result.

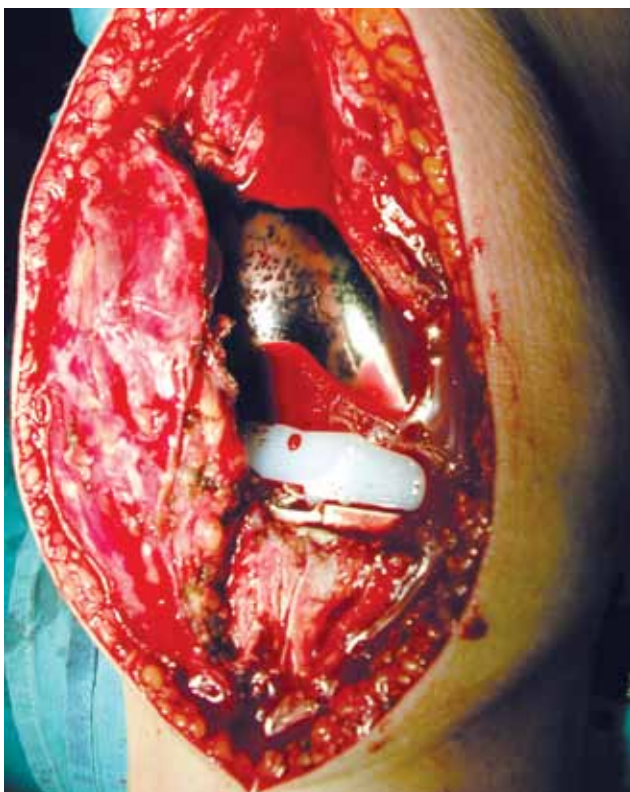

Figure 3. Patient with inhibitor underwent left total knee arthroplasty. Note normal bleeding after tourniquet release and implantation of prosthetic components.

arthroscopic joint débridement, arthrodesis, and total joint arthroplasty.¹⁵ For the hip, cemented or press-fit uncemented components can be used; for the knee, a posterior-stabilized cemented design is advised. In hemophilia, muscular problems must not be underestimated, given the risk for developing compartment syndrome, which requires surgical decompression, and pseudotumors, which require surgical removal or percutaneous management.

The surgical techniques that can be performed in hemophilic patients include joint aspiration, radiosyn-

vectomy (RS) (Figure 1), arthroscopic synovectomy, arthroscopic joint débridement, alignment osteotomy, tendon lengthening, ankle arthrodesis (Figure 2), ankle arthroplasty, total knee arthroplasty (TKA) (Figure 3), placement of external fixators for progressive extension of joints with flexion contracture, neurolysis of entrapped nerves, arthrotomy for septic arthritis, drainage of infected hematomas, removal or percutaneous management of pseudotumors, fasciotomy for decompression of compartment syndrome, and various types of osteosynthesis for bone fractures.^{16,17}

In some cases, a double or triple surgical procedure can be performed in a single session to solve the functional problem in a comprehensive way. This tactic undoubtedly increases anesthesia and bleeding risks, but it also saves coagulation factor and avoids additional surgical sessions.¹⁸ Surgery must be performed with intravenous antibiotic prophylaxis for 24 to 48 hours. For patients with hemophilia, treatment must be individualized. Surgery must be performed in collaboration with the hematologist, who is responsible for maintaining adequate hemostasis during all phases of treatment (bolus or continuous infusion). The hematologic treatments most commonly used for patients with inhibitors are rFVIIa and APCCs.¹⁹ Several publications have indicated that, with appropriate hemostasis, a high degree of safety can be maintained during surgical treatment of patients with inhibitors.²⁰⁻²³ According to these publications, most authors use rFVIIa for major surgery, though others obtain satisfactory results with APCCs.

In an international study involving 8 hospitals, 108 patients with inhibitors were treated.²¹ RS was performed in 88 of these patients (47 with APCCs, 31 with rFVIIa, 10 with other methods) and major surgery in the other 20 (17 with rFVIIa, 3 with APCCs).

In 2010, we described 35 orthopedic surgeries in hemophilic patients with inhibitors.²⁴ Both rFVIIa and APCCs appeared to be effective, though bibliographic data showed that hematologists have a predilection for using

Table I. Recommended Dosage of Activated Prothrombin Complex Concentrate for Orthopedic Surgery²²

Surgery	Dosage ^a		
	Preoperative	Days 1–5	Days 6–14
Minor	50-75 U/kg	50-75 U/kg every 12-24 h, 1 or 2 doses	—
Major	75-100 U/kg	75-100 U/kg every 8-12 h	75-100 U/kg every 12 h

^aMaximum, 250 U/kg/d.

Table II. Recommended Dosage of Recombinant Activated Factor VII for Orthopedic Surgery²²

Surgery	Infusion	Dosage		
		Preoperative	Days 1–5	Days 6–14
Minor/major	Bolus	90-120 µg/kg (ped. 120-150 µg/kg)	90-120 µg/kg every 2 h, up to 4 doses, every 3-6 h for 24 h	—
	Continuous infusion	15-50 µg/kg/h	15-50 µg/kg/h	15-50 µg/kg/h

Abbreviation: Ped, pediatrics.

rFVIIa in major surgery. With respect to minor orthopedic surgery (RS), we injected 27 joints (27 patients) with either yttrium (⁹⁰Y), for knees, or rhenium (¹⁸⁶Rh), for ankles and elbows. In 20 of these 27 cases, APCCs were used; in the other 7, rFVIIa was used. With respect to major orthopedic surgery, we performed 8 orthopedic procedures (6 patients): 3 TKAs, 1 total hip arthroplasty, 1 fixation of bone fracture, 1 ankle arthrodesis, 1 removal of hardware from ankle fusion, and 1 knee arthrodesis. Of these 8 procedures, 6 were performed with rFVIIa and 2 with APCCs. Of the 35 orthopedic procedures total, 22 were performed with APCCs and 13 with rFVIIa.²⁴ There was 1 complication, a pseudoaneurysm of a geniculate artery after a TKA. The pseudoaneurysm was eventually occluded by arterial embolization (vascular stent), and the outcome was excellent.

Regarding appropriate hematologic perioperative treatment, it has been reported that rFVIIa infusion at 50 µg/kg/h provides adequate hemostatic control for patients with inhibitors during major orthopedic surgery.²⁵ Habermann and colleagues²⁶ stated that a safe and economical therapy for guaranteeing hemostasis in major elective orthopedic surgery consists of immuno-adsorbent therapy to reduce inhibitors before surgery, perioperative substitution of FVIII, and switching to rFVIIa when inhibitors are increased. On the other hand, monotherapy with rFVIIa allows immediate surgical intervention, without a long hospital stay before surgery and the need for laboratory monitoring of inhibitor titers and FVIII levels. Bolus infusion and continuous infusion of rFVIIa appear to be comparable in their hemostatic efficacy in surgical management of hemophilic patients with inhibitors.²⁷ Giangrande and colleagues²⁸ described a new rFVIIa protocol for elective orthopedic surgery. In this protocol, which is based

on a review of published data as well as the personal experience of a group of expert physicians, an initial bolus dose of rFVIIa, in the range of 120 to 180 µg/kg⁻¹, is used to cover surgery. In all cases, there was good control of hemostasis during surgery, and the final outcome was rated *excellent* or *extremely satisfactory* by the reporting clinicians. Although the initial cost of the product to cover surgery, such as arthroplasty, is high, this cost may be offset in subsequent years by savings resulting from fewer bleeding episodes in the affected joint. Takedani and colleagues²⁹ reported that the combination of bolus and continuous infusion of rFVIIa is safe and effective, and its administration is more convenient than simple bolus infusion therapy is in achieving hemostasis during the perioperative period. According to Caviglia and colleagues,³⁰ bypassing agents can be used to achieve good control of hemostasis in hemophilic patients with inhibitors who undergo minor and major elective orthopedic surgery. Our recommended hematologic treatment is outlined in Tables I and II.²²

MINOR ORTHOPEDIC SURGERY

When continuous prophylaxis is not feasible because of expense or lack of venous access, we must aggressively manage major hemarthroses and perform arthrocentesis to prevent progression to synovitis, recurrent joint bleeds, and, ultimately, end-stage osteoarthritis (hemophilic arthropathy).⁵ When chronic hemophilic synovitis is being managed, RS should always be performed first (Figure 1). Should RS fail 3 times (6-month intervals), arthroscopic synovectomy is indicated. RS consists of the intra-articular injection of radioactive material (yttrium-90, rhenium-186, phosphorus-32) capable of reducing the degree of synovial hypertrophy, and therefore the number and frequency of hemarthroses.

RS is commonly used in the management of recurrent intra-articular bleeds and secondary chronic synovitis in hemophilic patients. The administered agent induces fibrosis in the inflamed synovium and reduces the bleeding tendency. Whichever agent is used, care must be taken to avoid the extra-articular complications (eg, radiation burn, inflammatory reaction) that can result from extravasation or needle-track contamination. In hemophilia, the joints that are most often affected are the elbows, knees, ankles, and, to a lesser extent, the shoulders and hips.

Elbows, knees, and ankles may be injected on an outpatient basis and under local anesthesia. However, it is advisable to inject shoulders and hips under radiographic guidance to ensure accurate placement. Very young children may require either sedation or general anesthesia. Strict asepsis is naturally a paramount requirement. In general, the efficacy of RS is 75% to 80%, and RS can be performed in patients of any age. RS is performed to reduce the number and intensity of hemarthroses and the amount of cartilage damage caused by intra-articular blood in the joint over the medium and long term.³¹

MAJOR ORTHOPEDIC SURGERY

The most common interventions performed in hemophilic adults are TKAs (Figure 3). The joint pain and functional disability caused by severe hemophilic arthropathy impairment are so intense that most patients require total joint arthroplasty. Hip arthropathy may cause characteristic pain in the groin as well as pain radiating to the ipsilateral knee.

As already mentioned, it is sometimes advisable to operate 2 or 3 joints simultaneously (2 knees, or hip and knee) to obtain proper functioning of the lower limbs. In some cases, it is preferable to operate the more painful joint first and the less painful joint 3 to 6 months later. Prostheses of other joints (hips, shoulders, elbows, ankles) are rarely mentioned in the world literature on hemophilia.

TKA is typically performed with limb ischemia by a straight longitudinal incision and a medial parapatellar route inside. In hemophilia cases, many surgeons use antibiotic-loaded bone cement.^{16,17,32} The indication for a hip prosthesis is intense groin pain, sometimes radiating to the ipsilateral knee, with associated functional disability.^{16,17,33}

A local fibrin seal is not always needed to achieve hemostasis during surgery in patients with hemophilia. However, using a fibrin seal can be good adjunct therapy, mainly in cases in which the surgical field may bleed more than expected, such as in patients with inhibitors, but also in some orthopedic procedures, mainly surgical removal of pseudotumors.

DISCUSSION

Orthopedic surgery for hemophilic patients with inhibitors often is complex and poses risks for bleeding

(when hematologic control fails) and infection (when human immunodeficiency virus causes severe immunodeficiency). However, current hematologic management allows surgeons to control hemostasis in these cases. APCCs and rFVIIa have made major orthopedic surgery possible. Hemophilic patients with inhibitors can go into required orthopedic surgery with a high expectation of success.

Over the next 5 years, hematologic management of hemophilic patients with inhibitors should improve as a result of common use of enhanced on-demand treatment of acute joint bleeds in these patients and better control of hemostasis during the perioperative period of orthopedic procedures. In other words, the orthopedic status and quality of life of these patients are expected to improve.

Enhanced on-demand treatment of acute hemarthrosis is paramount in hemophilic patients with inhibitors. The aim of this treatment is to reduce the intensity of the chronic synovitis and cartilage damage caused by intra-articular blood in the joint over the medium and long term.

For acute hemarthrosis in patients with inhibitors, hematologic management must be maintained until bleeding goes into full remission and the patients have recovered as much of their preoperative range of motion and muscular strength as possible. Such a regimen (enhanced on-demand treatment) can take up to 3 months. In this connection, ultrasonography is a reliable, economical, and easy-to-use method for diagnosing hemarthrosis and following up on its evolution.

When chronic hemophilic synovitis is being managed, RS should always be performed first (Figure 1). Should RS fail 3 times (6-month intervals), arthroscopic synovectomy is indicated.

In hemophilia, muscular problems must not be underestimated, given the risk for developing compartment syndrome, which requires surgical decompression, and pseudotumors, which require surgical removal or percutaneous management.

A local fibrin seal is not always needed to achieve hemostasis during surgery in patients with hemophilia. However, using a fibrin seal can be good adjunct therapy, mainly in cases in which the surgical field may bleed more than expected, such as in patients with inhibitors, but also in some orthopedic procedures, mainly surgical removal of pseudotumors.

AUTHOR'S DISCLOSURE STATEMENT AND ACKNOWLEDGMENTS

The author reports no actual or potential conflict of interest in relation to this article. The author owes a debt of gratitude to hematologists Victor Jimenez-Yuste, MD, PhD, Maria Teresa Alvarez-Roman, MD, and Monica Martin-Salces, MD, for their paramount role in controlling hemostasis during the surgical procedures the author performs on hemophilic patients.

REFERENCES

1. Brackmann HH, Oldenburg J, Schwaab R. Immune tolerance for the treatment of factor VIII inhibitors—twenty years' 'Bonn protocol.' *Vox Sang.* 1996;70(suppl 1):30-35.
2. Abildgaard CF, Penner JA, Watson-Williams EJ. Anti-inhibitor coagulant complex (Autoplex) for treatment of factor VIII inhibitors in hemophilia. *Blood.* 1980;56(6):978-984.
3. Hilgartner MW, Knatterud GL. The use of factor eight inhibitor by-passing activity (FEIBA immuno) product for treatment of bleeding episodes in hemophiliacs with inhibitors. *Blood.* 1983;61(1):36-40.
4. Hilgartner M, Aledort L, Andes A, Gill J. Efficacy and safety of vapor-heat-activated anti-inhibitor coagulant complex in hemophilia patients. *Transfusion.* 1990;30(7):626-630.
5. Hedner U, Glazer S, Pingel K, et al. Successful use of recombinant factor VIIa in patient with severe haemophilia A during synovectomy. *Lancet.* 1988;2(8621):1193.
6. Hedner U, Glazer S, Falch J. Recombinant activated factor VII in the treatment of bleeding episodes in patients with inherited and acquired bleeding disorders. *Transfus Med Rev.* 1993;7(2):78-83.
7. Hedner U, Ingerslev J. Clinical use of recombinant FVIIa (rFVIIa). *Transfus Sci.* 1998;19(2):163-176.
8. Roberts HR. Clinical experience with activated factor VII: focus on safety aspects. *Blood Coagul Fibrinolysis.* 1998;9(suppl 1):S115-S118.
9. White GC 2nd, Taylor RE, Blatt PM, Roberts HR. Treatment with a high titer anti-factor-VIII antibody by continuous factor VIII administration: report of a case. *Blood.* 1983;62(1):141-145.
10. Brettler DB, Forsberg AD, Levine PH, et al. The use of porcine factor VIII concentrate (Hyate:C) in the treatment of patients with inhibitor antibodies to factor VIII. A multicenter US experience. *Arch Intern Med.* 1989;149(6):1381-1385.
11. Bona RD, Pasquale DN, Kalish RI, Witter BA. Porcine factor VIII and plasmapheresis in the management of hemophilic patients with inhibitors. *Am J Hematol.* 1986;21(2):201-207.
12. Lozier JN, Santagostino E, Kasper CK, Teitel JM, Hay CR. Use of porcine factor VIII for surgical procedures in haemophilia A patients with inhibitors. *Semin Hematol.* 1993;30(2 suppl 1):10-21.
13. Heisel MA, Gomperts ED, McComb JG, Hilgartner M. Use of activated prothrombin complex concentrate over multiple surgical episodes in a hemophilic child with an inhibitor. *J Pediatr.* 1983;102(6):951-954.
14. Rodríguez-Merchán EC, Jimenez-Yuste V, Aznar JA, et al. Joint protection in haemophilia. *Haemophilia.* 2011;17(suppl 2):1-23.
15. Rodríguez-Merchán EC. Aspects of current management: orthopaedic surgery in haemophilia. *Haemophilia.* 2012;18(1):8-16.
16. Rodríguez-Merchán EC, Goddard NJ, Lee CA. *Musculoskeletal Aspects of Haemophilia.* Oxford, England: Blackwell Science; 2000.
17. Rodríguez-Merchán EC. Management of the orthopaedic complications of haemophilia. *J Bone Joint Surg Br.* 1998;80(2):191-196.
18. Horoszowski H, Heim M, Schulman S, Varon D, Martinowitz U. Multiple joint procedures in a single operative session on hemophilic patients. *Clin Orthop Relat Res.* 1996;(328):60-64.
19. Rodríguez-Merchán EC, Lee CA. *Inhibitors in Patients With Haemophilia.* Oxford, England: Blackwell Scientific; 2002.
20. Rodríguez-Merchán EC, Wiedel JD, Wallyn T, et al. Elective orthopaedic surgery for inhibitor patients. *Haemophilia.* 2003;9(5):625-631.
21. Rodríguez-Merchán EC, Wiedel JD, Wallyn T, et al. Elective orthopaedic surgery for hemophilia patients with inhibitors: new opportunities. *Semin Hematol.* 2004;41(1 suppl 1):109-116.
22. Rodríguez-Merchán EC, Rocino A, Ewenstein B, et al. Consensus perspectives on surgery in haemophilia patients with inhibitors: summary statement. *Haemophilia.* 2004;10(suppl 2):50-52.
23. Quintana-Molina M, Martínez-Bahamonde F, González-García E, et al. Surgery in haemophilic patients with inhibitor: 20 years of experience. *Haemophilia.* 2004;10(suppl 2):30-40.
24. Rodríguez-Merchán EC, Jimenez-Yuste V, Gomez-Cardero P, Alvarez-Roman MT, Martin-Salces M, Rodriguez de la Rúa A. Surgery in haemophilia patients with inhibitors, with special emphasis on orthopaedics: Madrid experience. *Haemophilia.* 2010;16(102):84-88.
25. Ludlam CA, Smith MP, Morfini M, Gringeri A, Santagostino E, Savidge GF. A prospective study of recombinant activated factor VII administered by continuous infusion to inhibitor patients undergoing elective major orthopaedic surgery: a pharmacokinetic and efficacy evaluation. *Br J Haematol.* 2003;120(5):808-813.
26. Habermann B, Hochmuth K, Hovy L, Scharrer I, Kurth AH. Management of haemophilic patients with inhibitors in major orthopaedic surgery by immunoadsorption, substitution of factor VIII and recombinant factor VIIa (NovoSeven): a single centre experience. *Haemophilia.* 2004;10(6):705-712.
27. Pruthi RK, Mathew P, Valentino LA, et al. Haemostatic efficacy and safety of bolus and continuous infusion of recombinant factor VIIa are comparable in haemophilia patients with inhibitors undergoing major surgery. Results from an open-label, randomized, multicenter trial. *Thromb Haemost.* 2007;98(4):726-732.
28. Giangrande PL, Wilde JT, Madan B, et al. Consensus protocol for the use of recombinant activated factor VII [eptacog alfa (activated); NovoSeven] in elective orthopaedic surgery in haemophilic patients with inhibitors. *Haemophilia.* 2009;15(2):501-508.
29. Takedani H, Kawahara H, Kajiwara M. Major orthopaedic surgeries for haemophilia with inhibitors using rFVIIa. *Haemophilia.* 2010;16(2):290-295.
30. Caviglia H, Candela M, Galatro G, Neme D, Moretti N, Bianco RP. Elective orthopaedic surgery for haemophilia patients with inhibitors: single centre experience of 40 procedures and review of the literature. *Haemophilia.* 2011;17(6):910-919.
31. Rodríguez-Merchán EC, Quintana M, De la Corte-Rodríguez H, Coya J. Radioactive synoviorthesis for the treatment of haemophilic synovitis. *Haemophilia.* 2007;13(suppl 3):32-37.
32. Cohen I, Heim M, Martinowitz U, Chechick A. Orthopaedic outcome of total knee replacement in haemophilia A. *Haemophilia.* 2000;6(2):104-109.
33. Löfqvist T, Sanzén L, Petersson C, Nilsson IM. Total hip replacement in patients with hemophilia. 13 hips in 11 patients followed for 1-16 years. *Acta Orthop Scand.* 1996;67(4):321-324.