

Articular Shear of the Anterior-Inferior Quadrant of the Glenoid: A Glenolabral Articular Disruption Lesion Variant

Gregory J. Galano, MD, Benjamin M. Weisenthal, BA, and David W. Altchek, MD

ABSTRACT

Traumatic cartilage lesions of the shoulder, such as glenolabral articular disruption (GLAD), have previously been recognized in patients with shoulder instability. We describe a new lesion in which the entire anteroinferior quadrant of the glenoid articular cartilage is sheared off in association with an adjacent labral tear. Both patients were teenage athletes who were being treated arthroscopically for shoulder instability. Preoperative imaging showed some evidence of an articular cartilage lesion. One patient was treated with removal of an irreparable fragment and microfracture, while in the other case the cartilage flap was reattached to the glenoid with a chondral fixation device. This GLAD lesion variant is a serious cartilage injury to the shoulder in young athletes that may be subtle, but needs to be recognized for proper arthroscopic treatment.

In addition to the Bankart lesion of the labrum, multiple other concurrent injuries have been observed with anterior glenohumeral instability. The GLAD (glenolabral articular disruption) lesion was first described by Neviasser¹ in 1993 as an articular lesion of the anteroinferior glenoid in association with labral tear. Although it is noted as a concomitant lesion in anterior instability,² relatively little has been written in terms of characterization and treatment. We present 2 cases of extensive glenoid chondral lesions in association with labral tears along with their arthroscopic treatment.

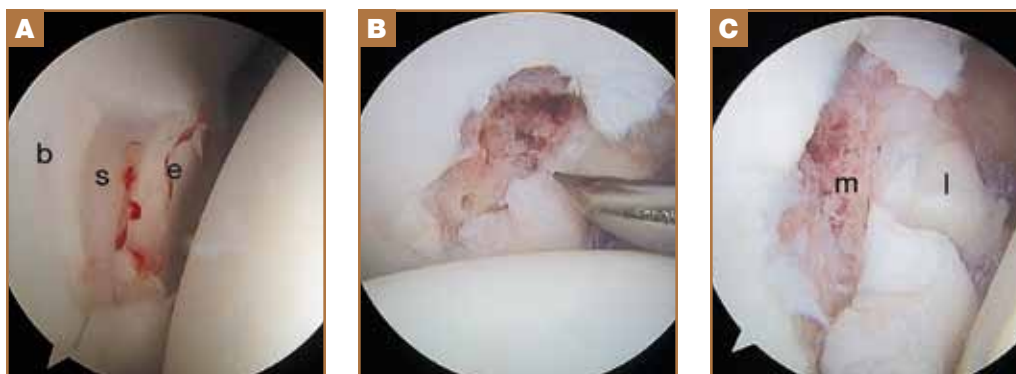
Patient provided written informed consent for print and electronic publication of this case report.

CASE 1

The patient was a 15-year-old girl who injured her right shoulder while shot putting. She experienced a giving way of the shoulder as she cocked to throw. Her physical examination was significant for anterior apprehension of the right shoulder and a positive anterior load-and-shift maneuver. A magnetic resonance imaging (MRI) of the right shoulder showed disruption of the glenoid articular cartilage as well as an anterior labral tear. She was diagnosed preliminarily with anterior shoulder instability. After discussion of treatment options, she and her family elected for operative management.

A diagnostic arthroscopy revealed a displaced, unstable osteochondral flap of the anteroinferior glenoid with rounded edges and macerated substance in association with an anterior Bankart labral lesion which extended from the 2- to 5-o'clock position (Figure 1A). The anteroinferior labrum was repaired to the edge of the glenoid face in standard fashion with 3 suture anchors

Figure 1. Right shoulder, viewing from: (A) the posterior portal, chondral degloving of the anteroinferior glenoid (b: bare area, s: exposed subchondral bone, e: edge of glenoid face); (B) the anterolateral portal, microfracturing of the glenoid chondral lesion; (C) the posterior portal: final repair of labrum and after microfracture of the glenoid (m: microfractured glenoid, l: labral repair).



Authors' Disclosure Statement: The authors have no actual or potential conflict of interest in relation to this article.

(PEEK SutureTak, Arthrex Inc, Naples, Florida). The chondral flap was closely examined and deemed unstable, removed, and a microfracture was performed on the underlying subchondral bone by previously described techniques (Figures 1B, 1C).³ In addition, a superior labrum anterior to posterior (SLAP) lesion was observed extending immediately anteriorly and posteriorly to the biceps, and this too was repaired using 2 suture anchors (PEEK SutureTak, Arthrex). At 3 months postoperatively, the patient was able to return fully to sports, including shot put, at pre-injury level of play, and she had full, painless, range-of-motion of the shoulder without recurrence of instability.

CASE 2

The patient was a 15-year-old boy who experienced multiple episodes of right shoulder subluxation without frank dislocation over the prior 2 months while wrestling. An MRI of the right shoulder revealed a Bankart lesion of the anterior labrum, a SLAP lesion of the superior labrum, and a focal chondral lesion of the glenoid with a hint of fluid dissection into the subchondral layer (Figures 2A, 2B). The patient’s shoulder examination was significant for right shoulder anterior apprehension/relocation, and a positive anterior load-and-shift

maneuver. The preliminary diagnosis was anterior shoulder instability. The patient and his family elected for operative management.

A standard diagnostic arthroscopy was performed which revealed posterior-superior SLAP and anteroinferior Bankart lesions of the labrum. There was also degloving of the anteroinferior glenoid articular cartilage beginning at the bare area and extending to the anterior edge of the glenoid face (Figure 3A). The superior most extent was the equator of the glenoid and it extended down to the inferior glenoid edge, thus encompassing one quarter of the overall glenoid surface. The edge of the cartilage flap, though unstable, remained loosely attached to the glenoid and the underlying subchondral bone was visible.

This major articular fragment of the glenoid appeared viable, so the underlying subchondral bone was abraded and the fragment was reattached using a cartilage fixation device (SmartNail PLA 1.5 mm x 25 mm, ConMed Linvatec, Largo, Florida). The Bankart lesion was repaired in standard fashion with 2 suture anchors (PEEK Suturetak, Arthrex) (Figure 3B) and the SLAP lesion with 1 anchor (BioComposite PushLock, Arthrex Inc, Naples, Florida).

At last follow-up, 4 months postoperatively, the operative shoulder was asymptomatic and displayed full range-of-motion. The patient did not return to his sport of wrestling due to a labral tear in the contralateral shoulder.

DISCUSSION

These 2 cases illustrate an extensive shear lesion of the glenoid cartilage in combination with a labral tear and anterior shoulder instability seen in teenage athletes. The original description of the GLAD lesion postulates that the mechanism of injury is forced shoulder adduction and impaction from an abducted and externally rotated position.¹ The resulting injury is a superficial anteroinferior labral tear with an adjacent articular cartilage injury. This mechanism seems plausible in both of our cases. Case 1 involved a shot putter who sustained the injury while preparing to throw, where the shot could have provided impaction to the glenohumeral joint. In Case 2, the injury occurred while wrestling where the patient’s own bodyweight may have provided the compressive force. The pattern of injury suggests that these lesions were acute and traumatic in nature, and not the result of compromised underlying subchondral bone, as postulated in cases of osteochondritis dissecans that occur in patients at or before skeletal maturity. Both athletes were advised about the possibility of glenohumeral arthrosis in the future. It is also interesting to note the significant degree of labral injury observed in both of these cases; both had combined SLAP and Bankart lesions.

GLAD lesions have been cited as one possible cause of chronic shoulder pain that may be overlooked.^{4,5} The lesion

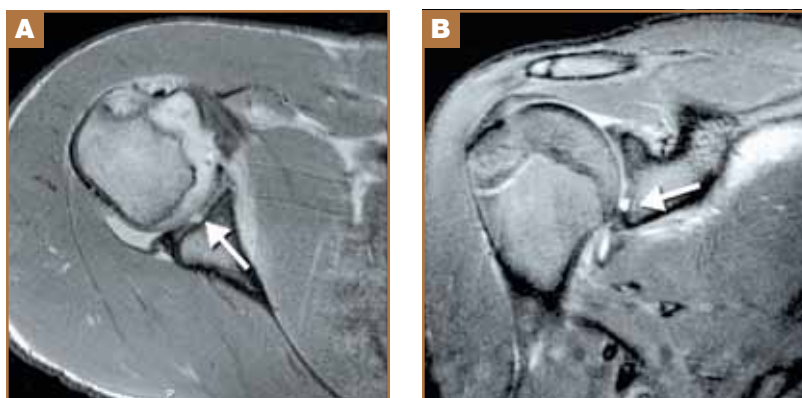


Figure 2. Right shoulder. (A) Axial MRI image of the right shoulder demonstrating anterior glenoid chondral injury (arrow) and labral tear. (B) Coronal MRI image of the right shoulder demonstrating inferior glenoid chondral injury (arrow).

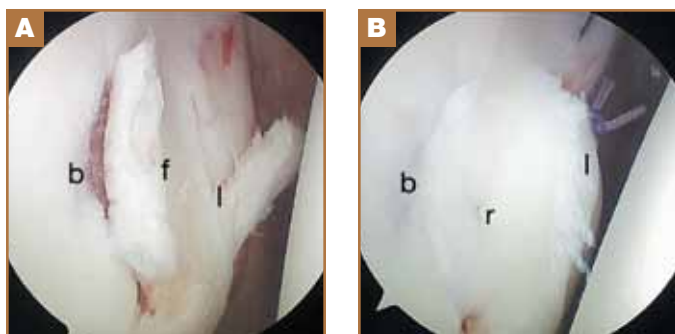


Figure 3. Right shoulder. (A) Viewing from the posterior portal: chondral degloving of the anteroinferior glenoid with labral tear (b: bare area, f: chondral flap, l: labral tear). (B) Viewing from the posterior portal: final labral and glenoid chondral repair (b: bare area, r: chondral repair, l: labral repair).

observed in the current study differs from the GLAD which is traditionally described as an articular disruption at the edge of the glenoid. This matters in terms of what treatment method is appropriate. Many standard GLAD lesions can be debrided and the torn labrum advanced up onto the glenoid face to fill the chondral void. This was not possible in either of our cases as the void would be much too large. In Case 1, the large chondral flap was severely damaged, so we felt that retention of the flap would have a high risk for failure, hence excision and microfracture was performed. In Case 2, the flap was in better condition and had a stable attachment at one end, so a repair was performed.

Microfracture of full-thickness articular defects in the glenoid has been described previously. Frank and colleagues⁶ found significant improvements in validated shoulder scores in their case series of 15 shoulders that underwent glenoid and/or humerus microfracture at 27.8 months, with 92.3% reporting they would undergo the same procedure again. Millet and colleagues⁷ reported on 31 shoulders that underwent microfracture at 47 months and found a failure rate of 19%; smaller lesions of the humerus showed the greatest improvements, they also observed. Microfracture has also been employed successfully in treatment of osteochondritis dissecans of the glenoid.⁸

To our knowledge, there was only 1 case report of articular cartilage repair involving the glenoid to date. Page and Bhatia⁹ recently described a similar lesion in association with an anterior glenohumeral dislocation in a teenage football player which they termed *glenoid labral tear and articular flap* (GLAF) lesion. The lesion that they observed was a chondral flap, which was stable at the center of the glenoid adjacent to a Bankart lesion and reattached with a meniscal repair device. The lesions we observed were undermined and unstable throughout, which necessitated removal in one case and reattachment with a headless dart in another.

In conclusion, this GLAD lesion variant represents a severe

glenoid chondral injury, which has been associated with anterior glenohumeral instability in athletes around the age of skeletal maturity. Caution should be taken, as it may appear relatively innocuous on advanced imaging, but requires more extensive arthroscopic work, either repair or microfracture, than a standard labral repair.

Dr. Galano is Attending Orthopaedic Surgeon, Lenox Hill Hospital, New York, New York. Mr. Weisenthal is Medical Student, University of Rochester, New York. Dr. Altchek is Attending Orthopaedic Surgeon, Hospital for Special Surgery, New York, NY.

Address correspondence to: Gregory J. Galano, 130 E 77th St, 8th Fl, New York, NY 10075 (tel, 212-861-2300; e-mail, galano7@gmail.com).

Am J Orthop. 2013;42(1):41-43. Copyright Frontline Medical Communications Inc. 2013. All rights reserved.

REFERENCES

1. Neviasser TJ. The GLAD lesion: another cause of anterior shoulder pain. *Arthroscopy.* 1993;9(1):22-23.
2. Antonio GE, Griffith JF, Yu AB, Yung PS, Chan KM, Ahuja AT. First-time shoulder dislocation: High prevalence of labral injury and age-related differences revealed by MR arthrography. *J Magn Reson Imaging.* 2007;26(4):983-991.
3. Steadman JR, Rodkey WG, Rodrigo JJ. Microfracture: surgical technique and rehabilitation to treat chondral defects. *Clin Orthop Relat Res.* 2001(391 suppl):S362-S369.
4. Amrami KK, Sperling JW, Bartholmai BJ, Sundaram M. Radiologic case study. Glenolabral articular disruption (GLAD) lesion. *Orthopedics.* 2002;25(1):29, 95-96.
5. Sanders TG, Tirman PF, Linares R, Feller JF, Richardson R. The glenolabral articular disruption lesion: MR arthrography with arthroscopic correlation. *AJR Am J Roentgenol.* 1999;172(1):171-175.
6. Frank RM, Van Thiel GS, Slabaugh MA, Romeo AA, Cole BJ, Verma NN. Clinical outcomes after microfracture of the glenohumeral joint. *Am J Sports Med.* 2010;38(4):772-781.
7. Millett PJ, Huffard BH, Horan MP, Hawkins RJ, Steadman JR. Outcomes of full-thickness articular cartilage injuries of the shoulder treated with microfracture. *Arthroscopy.* 2009;25(8):856-863.
8. Gogus A, Ozturk C. Osteochondritis dissecans of the glenoid cavity: a case report. *Arch Orthop Trauma Surg.* 2008;128(5):457-460.
9. Page R, Bhatia DN. Arthroscopic repair of a chondrolabral lesion associated with anterior glenohumeral dislocation. *Knee Surg Sports Traumatol Arthrosc.* 2010;18(12):1748-1751.