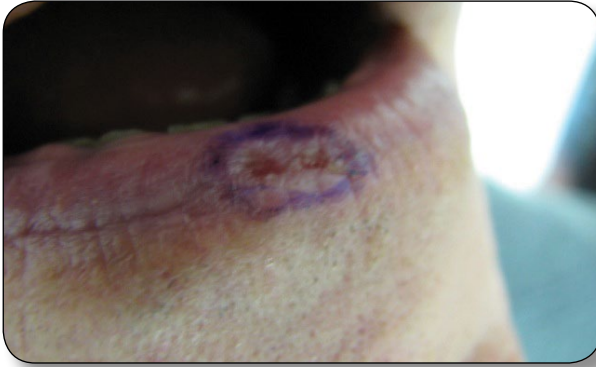


>> DIAGNOSIS AT A GLANCE

Stephen M. Schleicher, MD
Jessica Frawley, PA-C

CASE 1

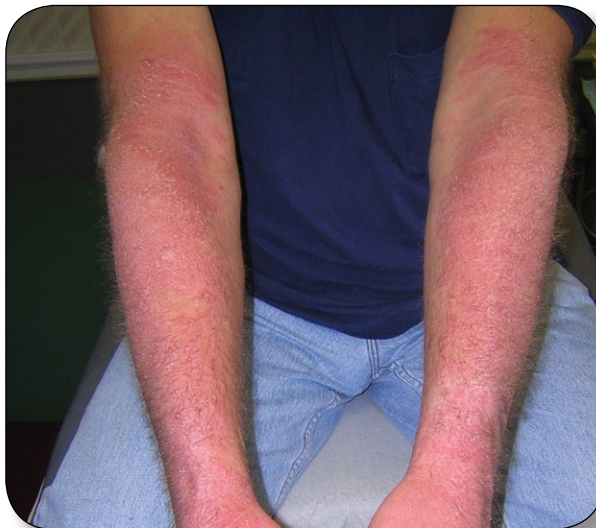

Case submitted by Dr. Schleicher and Ms. Frawley.

A 63-year-old fair-skinned man presents with a persistent sore on his lower lip that has been present for at least the past 2 months. His medical history is positive for treatment of actinic keratoses of the face and scalp. The patient has spent ample time outdoors and resides part-time in Hawaii. He was a heavy smoker but quit smoking nearly a decade ago. On examination, the patient's skin has stigmata of sun damage, including lentigos and telangiectasias. A crusted plaque with a central depression is noted on his lower lip. Submandibular and cervical lymph nodes are nonpalpable.

What is your diagnosis?

CASE 2



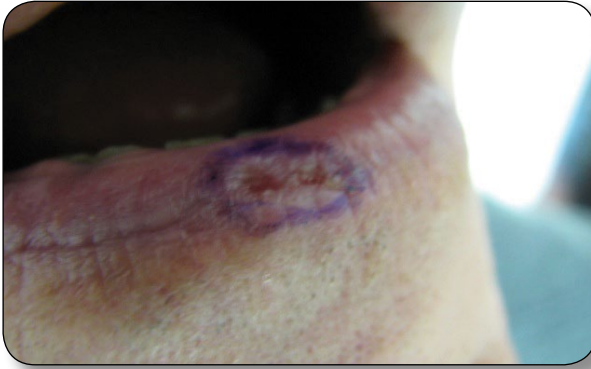
Case submitted by Dr. Schleicher.

A 65-year-old man is evaluated for an acute eruption on his hands, arms, face, and neck that is quite pruritic and occasionally burns. The rash began soon after he returned from a daytime fishing trip. His medical history is positive for mild hypertension, for which he recently began taking hydrochlorothiazide, and negative for collagen vascular disease or any prior episode of a similar rash. Examination reveals well-demarcated zones of erythema of the affected areas.

What is your diagnosis?

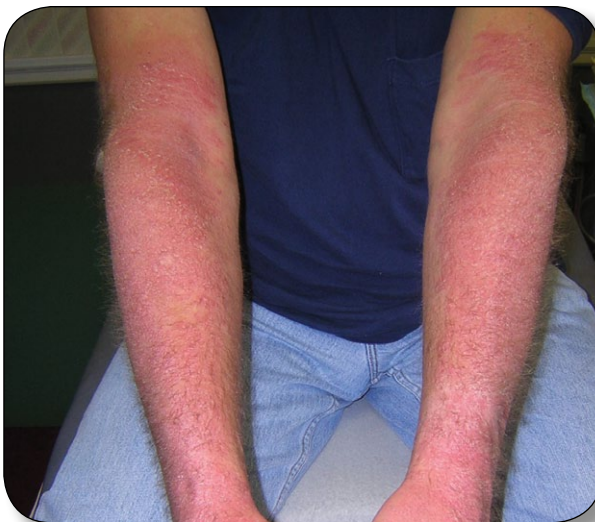Turn page for answers >>

CASE 1



This patient has actinic cheilitis. Actinic, or solar, cheilitis is a precancerous condition related to cumulative lifetime sun exposure. It is also known as “farmer’s lip” and “sailor’s lip.” Squamous cell carcinoma develops in approximately 6% to 10% of cases. Sun avoidance is recommended as prophylaxis, and when this is not feasible, use of high-SPF lip balms and wide-brimmed hats is recommended. Treatment options include a lip shave procedure, laser ablation, electrodesiccation, dermabrasion, and topical therapy with fluorouracil or imiquimod creams.

CASE 2



Photosensitivity is a well-known side effect associated with thiazide diuretics. The mechanism of action is deemed phototoxic in nature: ultraviolet light induces changes within the drug residing in the skin, rendering it capable of damaging exposed tissue. Often, the reaction occurs following the patient’s first exposure to sunlight after initiation of the drug, and usually the condition resolves within a week of discontinuation. Severe symptomatic cases may warrant a short course of oral prednisone. Other drugs noted for inducing photosensitivity are NSAIDs and tetracyclines.

Dr. Schleicher is director of the DermDOX Center in Hazleton, Pennsylvania, a clinical instructor of dermatology at King’s College in Wilkes-Barre, Pennsylvania, an associate professor of medicine at the Commonwealth Medical School in Scranton, Pennsylvania, and an adjunct assistant professor of dermatology at the University of Pennsylvania in Philadelphia. He is also a member of the EMERGENCY MEDICINE editorial board. **Ms. Frawley** is a physician assistant at the DermDOX Center.