

Neck–Shoulder Crossover: How Often Do Neck and Shoulder Pathology Masquerade as Each Other?

Jonathan N. Sembrano, MD, Sharon C. Yson, MD, Okezika C. Kanu, MD, Jonathan P. Braman, MD, Edward Rainier G. Santos, MD, Alicia K. Harrison, MD, and David W. Polly Jr, MD

Abstract

Cases of consecutive new patients seen at orthopedic spine and shoulder clinics were reviewed. Four percent of spine patients had significant shoulder pathology, and 3.6% of shoulder patients had significant spine pathology.

Identification of the correct pain generator is a prerequisite for effective treatment in patients with neck and/or shoulder problems. However, distinguishing between the two can be difficult. Relative frequencies of how often one is mistaken for the other have not been well established.

Six hundred ninety-four new patients were seen at the orthopedic shoulder clinic ($n = 452$) or spine clinic ($n = 242$) at an academic institution during a 2-year period. One hundred seven patients had previous shoulder surgery, and 39 had previous neck surgery. The 548 patients (shoulder clinic, 345; spine clinic, 203) who had no previous surgery were reviewed with respect to workup performed, final diagnosis, subsequent operative procedures, and incidence of referral from the shoulder clinic to the spine clinic and vice versa.

Among the patients seen at the shoulder clinic, 325 (94.2%) had shoulder pathology, 6 (1.7%) had neck but no shoulder pathology, 6 (1.7%) had shoulder and neck pathology, and 8 (2.3%) had an unidentifiable cause of pain. Of the 12 patients with neck pathology, none underwent neck surgery.

Among the patients seen at the spine clinic, 182 (89.7%) had neck pathology, 5 (2.5%) had shoulder but no neck pathology, 3 (1.5%) had neck and shoulder pathology, and 13 (6.4%) had an unidentifiable cause of pain. Of the 8 patients with shoulder pathology, 1 (12.5%) underwent shoulder surgery.

Our analysis suggests that for patients who present to a shoulder surgeon's clinic for shoulder pain, 3.6% will turn out to have neck pathology. For patients who present to a spine surgeon's clinic for neck pain, 4% may turn out to have shoulder pathology. Thus, approximately 1 in 25 patients seen at a surgeon's clinic for a presumed shoulder or neck problem may exhibit neck–shoulder crossover, in which pathology in one may be mistaken for or coexist with the other.

Neck and shoulder pain are common presentations in the ambulatory care setting.^{1–4} Identification of the correct pain generator is a prerequisite to effective treatment in patients with neck and/or shoulder problems. However, distinguishing cervical spine pathology from primary shoulder disease can be difficult. Neck and shoulder symptoms may overlap and coexist because of their proximity in anatomical locations, common innervations, and overlying musculature.^{5,6} In addition, there are similar demographics for the patients with these 2 types of pathology.^{7,8} It is not

uncommon to diagnose and treat a case of cervical spine pathology that initially presented as a shoulder complaint, and vice versa.^{9–11}

A recent best evidence synthesis placed the 12-month incidence of neck pain between 30% and 50%.³ Another systematic review placed the 12-month incidence of shoulder pain between 5% and 47%.¹² The relative frequencies of how often one type of pain is mistaken for the other are not well established.

We conducted a study to determine the frequency of symptomatic neck pathology among patients seen at a shoul-

Authors' Disclosure Statement: Dr. Sembrano has ongoing research supported by NuVasive Inc. Dr. Santos has ongoing research supported by SI-Bone Inc. Dr. Polly was a consultant for Medtronic Inc and has received research support from Medtronic Inc and grants from the US Department of Defense, the Scoliosis Research Society, and The Pediatric Orthopaedic Society of North America. Drs. Yson, Kanu, Braman, and Harrison report no actual or potential conflict of interest in relation to this article.

Table I. Background Data on 548 Patients Who Presented at Shoulder and Spine Clinics With No Previous Surgery

Sex	No. of Patients	
	Shoulder Clinic	Spine Clinic
Females	162 (47%)	105 (52%)
Males	183 (53%)	98 (48%)
Age, y		
Mean (range)	53.0 (14-92)	48.2 (8-89)
Median	54	48
<21 y	9	6
21-40 y	71	46
41-60 y	150	122
61-80 y	99	27
>80 y	16	2
Duration of Symptoms		
<1 mo	29	16
1-6 mo	90	56
>6 mo	226	131
Inciting Event		
Work injury	18	18
Sports injury	38	7
Vehicular accident	37	39
Lifting	16	5
Fall	85	7
No injury	112	88
Unspecified	37	39
Others	2	—
Referral Source		
Primary care provider	159	126
Orthopedic specialist	46	20
Medical subspecialist	31	15
Surgical subspecialist	11	1
Self-referred	77	23
Unspecified	21	18
Symptoms		
Shoulder and/or arm	343 (99.4%)	33 (16.3%)
Neck	0 (0%)	94 (46.3%)
Neck and shoulder/arm	2 (0.6%)	76 (37.4%)

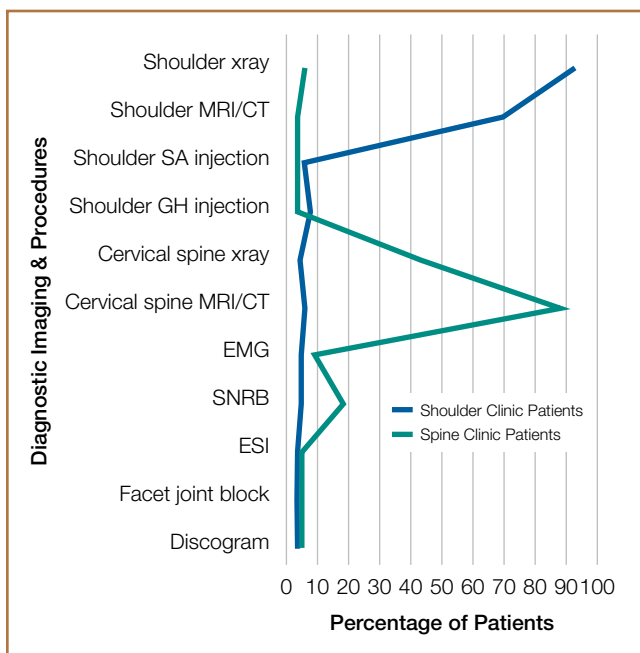


Figure 1. Summary of diagnostic imaging and procedures performed at each clinic.

der clinic for shoulder complaints and to determine the frequency of symptomatic shoulder pathology among patients seen at a spine clinic for neck complaints. This is the first epidemiologic study of the incidence of this neck–shoulder crossover phenomenon.

Materials and Methods

Medical records of initial consultations at the spine clinic (JNS, ERGS) and the shoulder clinic (JPB) between January 2008 and December 2009 were reviewed by 2 observers (SCY, OCK) not involved in patient care. Patients who presented with neck pain, shoulder and/or arm pain, or a combination of both were reviewed. We noted history, physical examination, imaging studies, and all diagnostic procedures performed to arrive at the final diagnosis. We excluded patients who had undergone previous neck or shoulder surgery from the final analysis for 2 reasons. First, they may have had pain related to previous surgery (eg, pseudarthrosis). Second, they may have had a more complex clinical presentation. Institutional review board approval was obtained before the start of the study.

The initial impression of pain etiology was based on information provided at the patient’s first clinic visit. This information included history, physical examination, and imaging studies. Further diagnostic workup in the form of additional imaging, injection, or specialized nerve tests was performed at the surgeon’s discretion (Figure 1). The final recommendation—surgery, nonoperative treatment, or referral to another clinic—was primarily determined by the treating surgeon.

Shoulder pathology was diagnosed on the basis of detailed history, physical examination, and confirmatory findings on radiographs and imaging studies (magnetic resonance imaging

[MRI], computed tomography [CT]). Occasionally, a subacromial or glenohumeral steroid injection was performed to assist in identifying the pain generator. If the shoulder surgeon deemed that the pain was not from the shoulder, or suspected a spine pathology contributing to the patient’s complaints, the patient was referred to the spine clinic. The final recommendation of the physician receiving the referral was also reviewed.

Spine pathology was similarly assessed. Standing radiographs were routinely evaluated, but additional studies (eg, dynamic radiographs, MRI, CT) were ordered when appropriate. In addition to epidural or selective nerve root blocks, tests such as electromyography (EMG), facet joint blocks, and discography were used by spine surgeons as ancillary diag-

Table II. Breakdown of Cases Seen at Shoulder Clinic

Diagnosis	No. of Patients
Shoulder	
Impingement syndrome	5
Rotator cuff tear/sprain	110
SLAP lesion/biceps	35
Adhesive capsulitis	23
Degenerative joint disease ^a	85
Instability	11
Osteonecrosis	4
Dislocation	7
Others	51
Spine	
Spondylosis	7
Herniated nucleus pulposus	3
Others	2
No Cause Identified	8

Abbreviation: SLAP, superior labral anterior-posterior.
^aGlenohumeral and acromioclavicular arthritis.

nostic procedures. Referral to the shoulder clinic was made as deemed necessary by the spine surgeon.

Results

Six hundred ninety-four new patients were seen at the orthopedic shoulder clinic (n = 452) or spine clinic (n = 242) at an academic institution during a 2-year period. The cases were seen by 2 orthopedic spine surgeons and 1 shoulder surgeon. One hundred seven patients had previous shoulder surgery, and 39 had previous neck surgery. Five hundred forty-eight (345 shoulder, 203 spine) patients had no previous surgery and were reviewed for workup performed, final diagnosis, subsequent operative procedures, and incidence of referral from the shoulder clinic to the spine clinic, and vice versa.

Of the 548 patients, 282 (51%) were male. Mean age was 51.2 years (range, 8-92 years). Nearly half of the patients (254/548, 46%) were 41 to 60 years old, most had symptoms for longer than the 6 months before their initial consultation, and most (285/548, 52%) were referred by primary care providers (Table I).

Among patients seen at the shoulder clinic, 325

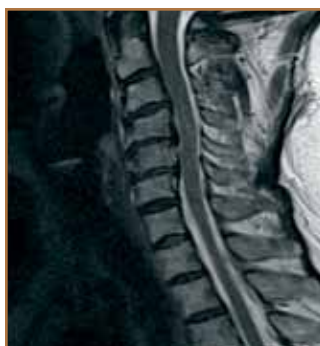

Figure 2. Sagittal T₂-weighted magnetic resonance imaging shows cervical spine of 51-year-old woman who presented with neck and shoulder pain. Multilevel disk degeneration was noted at C4–C5 and C5–C6 levels.

Table III. Breakdown of Cases Seen at Spine Clinic

Diagnosis	No. of Patients
Spine	
Spondylosis	107
Herniated nucleus pulposus	41
Cervical spine stenosis	14
Cervical spondylolisthesis/instability	1
Facet joint arthritis	2
Others	18
Shoulder	
Rotator cuff tear/sprain	2
SLAP lesion/biceps	1
Adhesive capsulitis	2
Degenerative joint disease ^a	3
No Cause Identified	13

Abbreviation: SLAP, superior labral anterior-posterior.
^aGlenohumeral and acromioclavicular arthritis.

(94.2%) had shoulder pathology, 6 (1.7%) had neck but no shoulder pathology, 6 (1.7%) had shoulder and neck pathology, and 8 (2.3%) had an unidentifiable cause of pain. The most common spine diagnosis in the shoulder clinic was spondylosis (7, 2%), followed by herniated nucleus pulposus (3, 0.9%) (Table II). All 3 patients diagnosed with a herniated disk responded well to steroid injections. Of the 12 patients with neck pathologies, none underwent neck surgery.

Among patients seen at the spine clinic, 182 (89.7%) had neck pathology, 5 (2.5%) had shoulder but no neck pathology, 3 (1.5%) had neck and shoulder pathology, and 13 (6.4%) had an unidentifiable cause of pain. The distribution of shoulder diagnoses in the spine clinic was fairly heterogeneous (Table III).

Of the 8 patients with shoulder pathology, 1 (12.5%) underwent shoulder surgery. This patient was a 51-year-old woman with chronic neck, shoulder, and arm pain. Cervical spine

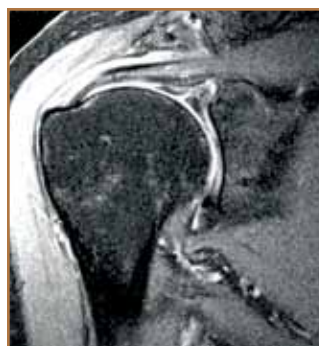

Figure 3. Coronal, fat-suppressed magnetic resonance imaging of right shoulder of same patient (51-year-old woman) shows superior labral anterior-posterior (SLAP) lesion.

MRI showed degenerative disks at C4–C5 and C5–C6 (Figure 2), and right shoulder MRI showed a superior labral anterior-posterior (SLAP) lesion (Figure 3). The patient was referred to the shoulder clinic, where she was diagnosed with right subacromial bursitis, acromioclavicular osteoarthritis, and a labral tear. Her neck and shoulder symptoms were managed nonoperatively at first, but she decided to have surgery after conservative treatment failed. Anterior cervical discectomy and fusion of C4–C5 and C5–C6 were

done first, and the shoulder stiffness was managed with continuous physical therapy. The patient reported that her neck pain improved significantly. Ten months after the cervical fusion, she underwent subacromial decompression, distal clavicle excision, and glenohumeral debridement, which improved her shoulder symptoms.

Discussion

The presenting symptoms of shoulder and neck pathologies overlap significantly.^{5,13,14} History, physical examination, and imaging studies are often nonspecific.^{15,16} On radiographs and MRI, absence of abnormalities in the area of the expected pain source can lead physicians to conclude a nonorganic etiology of symptoms. Likewise, presence of abnormal findings on shoulder and spine imaging is not tantamount to manifestation of pain.^{7,8,17-20} Therefore, we aimed in this study to identify how often shoulder pathology presented in the spine clinic, and how often spine pathology presented in the shoulder clinic.

Because of its retrospective nature, our study had several limitations. Foremost is that the treating surgeon determined the final diagnosis, and this diagnosis was not confirmed by other spine or shoulder surgeons. Second, the diagnostic workups were not standardized, such that not all patients underwent the same tests. Third, not all patients were assessed by both the spine surgeon and the shoulder surgeon. Although there is lack of a controlled clinical setting, the setup reflects the daily practice of a typical physician.

Frequently, a patient's localization of pain directs the clinician to the source of the pain. In our study, 99% of patients in the shoulder clinic presented with shoulder and/or arm pain. Ninety-four percent of these patients were indeed diagnosed with shoulder pathology. Patients who turned out to have neck or concomitant neck and shoulder pathology made up about 3.5% of the 345 patients reviewed, though none of these 12 patients needed to undergo spine surgery. None of these 12 patients presented with neck pain as their main symptom.

The presenting symptoms of patients seen in the spine clinic were relatively more heterogeneous than those seen in the shoulder clinic (Table I). Over the years, physicians have learned to pay attention to the qualities of a particular pain and not just its location. The shoulder is an often recognized area of pain resulting from pathology in the cervical spine.¹¹ For example, problems arising in the lower cervical facet joints have been shown to produce pain mainly concentrated in the shoulder region.^{5,21}

Gorski and Schwartz⁹ described a set of 34 patients who presented with chronic neck pain but were eventually diagnosed with shoulder impingement. The authors coined the term *referred shoulder impingement syndrome* to refer to the triad of positive "referred" impingement sign, abnormal shoulder radiograph, and relief with subacromial steroid injection in a patient who presents solely with neck pain. Treatments included cortisone injections (all patients) and shoulder decompression (5 patients). Subjective relief of neck pain after a mean follow-up of 7 years was reported. The authors speculated that the neck pain resulted as a protective mechanism resulting in ad-

acent muscle spasms. In our study, 4% of the 203 patients seen in the spine clinic turned out to have shoulder or concomitant neck and shoulder pathology. Of these 8 patients, 1 presented with neck pain only; the rest presented with both neck and shoulder/arm pain.

In patients with coexisting neck and shoulder problems, the question arises: Which problem should be addressed first, particularly if surgery is to be offered? Although there is likely general agreement that the cervical spine takes priority when a patient presents with advanced myelopathy from spinal cord compression, the order becomes less clear when pain is the main manifestation. Although there are no set guidelines or recommendations in dealing with pain coming equally from the shoulder and the cervical spine, earlier case series have shown good results when shoulder surgery was performed first. In 1990, Hawkins and colleagues¹⁰ reported the outcomes of intervention for concomitant neck and shoulder pain in 13 patients with dual pathology. Eight of these patients had pain coming equally from shoulder and spine. Six of these patients underwent shoulder surgery first. Shoulder surgery improved both symptoms, and these patients no longer needed cervical spine surgery. Two patients underwent cervical spine fusion, and both eventually required shoulder surgery. The same year, McCann and colleagues²² reported on 21 patients (23 shoulders) diagnosed with rotator cuff pathology and cervical radiculopathy. The authors reported improvement in neck pain after acromioplasty and rotator cuff repair in 20 of 23 shoulders (14 of 21 patients). Although the results of these studies would suggest treating shoulder problems first, Paterder and colleagues¹⁴ suggested that, if there is neurologic compromise, the spine pathology should be treated first.

Neck-shoulder syndromes are often difficult to evaluate. Various clinical tests are used to localize the pain source, but these have poor sensitivity and/or specificity.²³⁻²⁶ Several modifications of a single test may contribute to the poor diagnostic accuracy of these maneuvers. For instance, the Spurling test for cervical radiculopathy has been described at least 5 different ways.²⁷

In general, imaging studies are helpful adjuncts in patient workups. However, pathologic imaging findings often do not translate clinically. Twenty-three percent to 79% of asymptomatic shoulders have shown abnormalities on MRI.¹⁷⁻¹⁹ In the cervical spine, 19% to 90% of asymptomatic individuals have shown at least one abnormality on MRI.^{7,8,20} Furthermore, there is no statistically significant difference in incidence of imaging abnormalities between asymptomatic and symptomatic individuals.^{15,16,28} Correlation of patients' symptoms with diagnostic modalities is key in identifying the correct pain generator. At times, we have to consider other possible diagnoses and even be aggressive in pursuing these diagnoses.

Our results may be interpreted to show only a relatively low frequency of neck-shoulder crossover syndrome (3.6% in shoulder clinic, 4% in spine clinic). However, this may be more a reflection of our tertiary-care university-based practice, where patients are more likely to have already undergone extensive diagnostic tests and workups before referral, as

well as a reflection of the level of competence and efficiency of the practice referral patterns at our study site. It is unclear whether these numbers would hold true in other clinics and scenarios. A similar study should be conducted in patients who present with neck and/or shoulder problems to a primary-care or nonsurgical clinic.

In our practice, patients continue to be evaluated with a high index of suspicion that their presenting problem could be the result of an etiology outside the anatomical region represented by the subspecialty clinic. The discretion of the treating surgeon is used to further delineate when additional studies are needed. Finally, we have a low threshold for asking for additional consultation with our colleagues.

Conclusion

For patients who present to a shoulder surgeon's clinic for shoulder pain, our analysis suggests that 3.6% will turn out to have neck pathology. For patients who present to a spine surgeon's clinic for neck pain, 4% may turn out to have shoulder pathology. Thus, approximately 1 in 25 patients seen at a surgeon's clinic for a presumed shoulder or neck problem may exhibit neck–shoulder crossover, in which pathology in one may be mistaken for or coexist with the other.

Dr. Sembrano is Assistant Professor, Department of Orthopaedic Surgery, University of Minnesota, Minneapolis; and Staff Physician, Veterans Affairs Health Care System, Minneapolis, Minnesota. Dr. Yson is Spine Research Associate, Dr. Kanu is Orthopaedic Resident, Dr. Braman is Assistant Professor, Dr. Santos is Associate Professor, and Dr. Harrison is Assistant Professor, Department of Orthopaedic Surgery, and Dr. Polly is Professor and Chief of Spine Service, Departments of Orthopaedic Surgery and Neurosurgery, University of Minnesota, Minneapolis.

Address correspondence to: Jonathan N. Sembrano, MD, Department of Orthopaedic Surgery, University of Minnesota, 2450 Riverside Ave S, Suite R200, Minneapolis, MN 55454 (tel, 612-273-7991; fax, 612-273-7959; e-mail, sembr001@umn.edu).

Am J Orthop. 2013;42(9):E76-E80. Copyright Frontline Medical Communications Inc. 2013. All rights reserved.

References

- Riddle DL, Schappert SM. Volume and characteristics of inpatient and ambulatory medical care for neck pain in the United States: data from three national surveys. *Spine.* 2007;32(1):132-140.
- Côté P, Cassidy JD, Carroll L. The Saskatchewan Health and Back Pain Survey. The prevalence of neck pain and related disability in Saskatchewan adults. *Spine.* 1998;23(15):1689-1698.
- Hogg-Johnson S, van der Velde G, Carroll LJ, et al; Bone and Joint Decade 2000–2010 Task Force on Neck Pain and Its Associated Disorders. The burden and determinants of neck pain in the general population: results of the Bone and Joint Decade 2000–2010 Task Force on Neck Pain and Its Associated Disorders. *Spine.* 2008;33(4 suppl):S39-S51.
- Pope DP, Croft PR, Pritchard CM, Silman AJ. Prevalence of shoulder pain in the community: the influence of case definition. *Ann Rheum Dis.* 1997;56(5):308-312.
- Dwyer A, Aprill C, Bogduk N. Cervical zygapophyseal joint pain patterns. I: a study in normal volunteers. *Spine.* 1990;15(6):453-457.
- Grubb SA, Kelly CK. Cervical discography: clinical implications from 12 years of experience. *Spine.* 2000;25(11):1382-1389.
- Boden SD, McCowin PR, Davis DO, Dina TS, Mark AS, Wiesel S. Abnormal magnetic-resonance scans of the cervical spine in asymptomatic subjects. A prospective investigation. *J Bone Joint Surg Am.* 1990;72(8):1178-1184.
- Teresi LM, Lufkin RB, Reicher MA, et al. Asymptomatic degenerative disk disease and spondylosis of the cervical spine: MR imaging. *Radiology.* 1987;164(1):83-88.
- Gorski JM, Schwartz LH. Shoulder impingement presenting as neck pain. *J Bone Joint Surg Am.* 2003;85(4):635-638.
- Hawkins RJ, Bilco T, Bonutti P. Cervical spine and shoulder pain. *Clin Orthop.* 1990;(258):142-146.
- Bateman JE. Neurologic painful conditions affecting the shoulder. *Clin Orthop.* 1983;(173):44-54.
- Luime JJ, Koes BW, Hendriksen IJ, et al. Prevalence and incidence of shoulder pain in the general population; a systematic review. *Scand J Rheumatol.* 2004;33(2):73-81.
- Manifold SG, McCann PD. Cervical radiculitis and shoulder disorders. *Clin Orthop.* 1999;(368):105-113.
- Pateder DB, Berg JH, Thal R. Neck and shoulder pain: differentiating cervical spine pathology from shoulder pathology. *J Surg Orthop Adv.* 2009;18(4):170-174.
- Siivola SM, Levoska S, Tervonen O, Ilkko E, Vanharanta H, Keinänen-Kiukaanniemi S. MRI changes of cervical spine in asymptomatic and symptomatic young adults. *Eur Spine J.* 2002;11(4):358-363.
- Gore DR, Sepic SB, Gardner GM, Murray MP. Neck pain: a long-term follow-up of 205 patients. *Spine.* 1987;12(1):1-5.
- Sher JS, Uribe JW, Posada A, Murphy BJ, Zlatkin MB. Abnormal findings on magnetic resonance images of asymptomatic shoulders. *J Bone Joint Surg Am.* 1995;77(1):10-15.
- Miniaci A, Dowdy PA, Willits KR, Vellet AD. Magnetic resonance imaging evaluation of the rotator cuff tendons in the asymptomatic shoulder. *Am J Sports Med.* 1995;23(2):142-145.
- Miniaci A, Mascia AT, Salonen DC, Becker EJ. Magnetic resonance imaging of the shoulder in asymptomatic professional baseball pitchers. *Am J Sports Med.* 2002;30(1):66-73.
- Schellhas KP, Smith MD, Gundry CR, Pollei SR. Cervical discogenic pain. Prospective correlation of magnetic resonance imaging and discography in asymptomatic subjects and pain sufferers. *Spine.* 1996;21(3):300-311.
- Aprill C, Dwyer A, Bogduk N. Cervical zygapophyseal joint pain patterns. II: a clinical evaluation. *Spine.* 1990;15(6):458-461.
- McCann PD, Weiss RA, Bigliani LU. Results of anterior acromioplasty and rotator cuff repair in patients with impingement and cervical radiculopathy. In: Post M, Morrey BF, Hawkins RJ, ed. *Surgery of the Shoulder.* St. Louis, MO: Mosby-Yearbook; 1990:321-324.
- Hegedus EJ, Goode AP, Cook CE, et al. Which physical examination tests provide clinicians with the most value when examining the shoulder? Update of a systematic review with meta-analysis of individual tests. *Br J Sports Med.* 2012;46(14):964-978.
- Alquanae M, Galvin R, Fahey T. Diagnostic accuracy of clinical tests for subacromial impingement syndrome: a systematic review and meta-analysis. *Arch Phys Med Rehabil.* 2012;93(2):229-236.
- May S, Chance-Larsen K, Littlewood C, Lomas D, Saad M. Reliability of physical examination tests used in the assessment of patients with shoulder problems: a systematic review. *Physiotherapy.* 2010;96(3):179-190.
- Tong HC, Haig AJ, Yamakawa K. The Spurling test and cervical radiculopathy. *Spine.* 2002;27(2):156-159.
- Anekstein Y, Blecher R, Smorgick Y, Mirovsky Y. What is the best way to apply the Spurling test for cervical radiculopathy? *Clin Orthop.* 2012;470(9):2566-2572.
- Reuter RM, Hiller WD, Ainge GR, et al. Ironman triathletes: MRI assessment of the shoulder. *Skeletal Radiol.* 2008;37(8):737-741.