

Missed Locked Posterior Shoulder Dislocation With a Reverse Hill-Sachs Lesion and Subscapularis Rupture

Mohamed E. Moussa, MD, Robert E. Boykin, MD, and Brandon E. Earp, MD

Abstract

We report the case of a patient who sustained a missed locked posterior shoulder dislocation with a sizable anterior impression fracture and a concomitant acute rupture of the subscapularis tendon. Despite compromise of the tendon, a transfer of the lesser tuberosity into the humeral head defect along with suture anchor repair of the subscapularis was performed. Within 6 months, the patient regained near complete function of his shoulder with no episodes of instability. To our knowledge, this is the first reported case of an acute subscapularis rupture associated with a posterior shoulder dislocation and anterior humeral impression fracture, treated with the modified McLaughlin procedure and tendon repair with an excellent clinical result.

Posterior shoulder dislocations are an infrequently encountered entity, and despite advances in imaging, they are often missed, leading to a delay in diagnosis. Treatment of these injuries continues to pose a significant challenge to orthopedic surgeons, and there is a lack of consensus in the literature regarding the best option for management.

The majority of these dislocations are complicated by an associated anterior impression fracture of the humeral head, otherwise referred to as the reverse Hill-Sachs lesion.¹⁻⁹ The size of the defect typically dictates treatment, for which numerous interventions have been proposed. These can include structural bone graft to the humeral head, the modified McLaughlin procedure—involving transfer of the lesser tuberosity and subscapularis into the defect—and in some cases, arthroplasty.¹⁻⁹ Although the modified McLaughlin procedure has proven to be an effective means of treatment for many of these injuries, it is generally presumed that the lesser tuberosity fragment being transferred is attached to an intact subscapularis tendon.

Here, we present the case of a patient who sustained a missed locked posterior dislocation of the left shoulder, as-

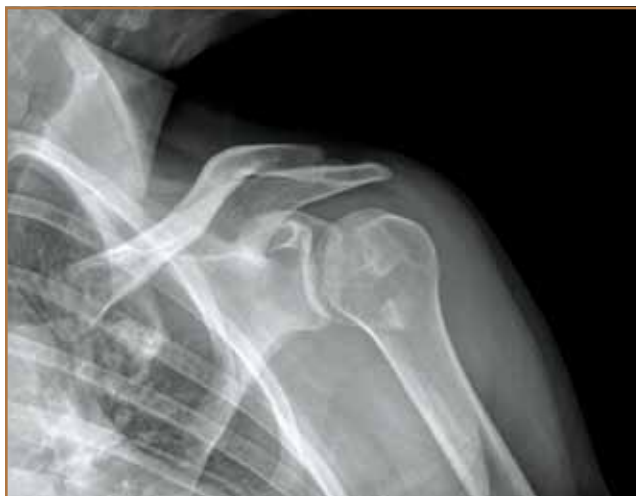sociated with a sizable anterior impression fracture of the humeral head, as well as a complete rupture of the subscapularis, who underwent a modified McLaughlin procedure and subscapularis repair with an excellent clinical result. The patient provided written informed consent for print and electronic publication of this case report.

Case Report

A healthy 42-year-old man presented 2 weeks after a skiing injury with persistent left shoulder pain and immobility. Eighteen years prior to presentation, the patient had a left shoulder subscapularis rupture from a wrestling injury, which was treated with open subscapularis repair. He stated that since his previous surgery, his shoulder has been normal, and he did not report any issues with instability in the interim.

When he presented to our institution, his arm was held in a position of internal rotation, and he had markedly painful and limited external rotation, both actively and passively. He remained in a sling since the injury. X-ray evaluation at the time of the recent injury was interpreted as normal at an out-

Figure 1. Anteroposterior radiograph of the left shoulder of the 42-year-old patient, presenting to our clinic 2 weeks post-skiing injury.



Authors' Disclosure Statement: The authors report no actual or potential conflict of interest in relation to this article.

side institution (Figure 1). However, upon our review of the anteroposterior radiograph, there was evidence of a dense ring of cortical bone in the humeral head, suggestive of the articular surface being seen end-on, as a result of internal rotation of the humerus. This radiographic sign has been classically referred to as the *light bulb sign*, and is highly suspicious for a posterior glenohumeral dislocation.^{2,10} He was then sent for a magnetic resonance imaging (MRI) arthrogram to further assess his injury. This confirmed a locked posterior glenohumeral dislocation with an associated large reverse Hill-Sachs lesion, and further revealed a complete tear of the subscapularis tendon with retraction to the subcoracoid region (Figure 2).

With these findings, the patient was taken to the operating room. The preexisting deltopectoral approach from his sub-

scapularis repair was used. The subscapularis was found to be completely torn, except for a few residual fibers at the distal aspect of the lesser tuberosity. The retracted tendon was identified and tagged. The humeral head was then gently reduced. There was a large reverse Hill-Sachs lesion, comprising approximately 25% of the articular humeral head surface. Given the risk of dislocation with this lesion, a modified McLaughlin procedure (ie, transfer of the lesser tuberosity with subscapularis) was selected to address this defect.

The edge of the bicipital groove was identified and an osteotome was used to osteotomize the lesser tuberosity. The osteotomized lesser tuberosity with the few residual fibers of the inferior subscapularis was transferred to the Hill-Sachs void, and provisionally held with K-wires. After fluoroscopic confirmation of acceptable placement, 2 cancellous 4-0 cannulated screws were then placed with washers, which provided excellent purchase. The choice of screws was based on an intraoperative assessment of the bone quality and size of the osteotomized tuberosity.

The patient's shoulder was taken through a full range of motion (ROM) and found to be stable throughout, including maximal internal rotation in adduction and 90° of abduction. Attention was then directed to the subscapularis repair. It was not practical to repair the subscapularis to the transferred lesser tuberosity fragment, as not only was there insufficient soft tissue to repair to, but placing a fixation device through this fragment could potentially compromise its fixation to the humerus. Two non-absorbable, braided polyester sutures were passed through the subscapularis tendon in a Mason-Allen technique. The subscapularis sutures were then passed through two 4.5 knotless suture anchors and tamped into place at the very lateral border of the transferred lesser tuberosity, which would correlate to the medial border of the native lesser tuberosity location. This provided excellent purchase and a robust subscapularis repair. The biceps was well located in the groove, and the interval was closed in routine fashion. The patient was placed in an external rotation immobilizer.

Postoperative rehabilitation included physical therapy starting 2 weeks after surgery, with abduction and forward flexion exercises in 20° of external rotation. By 6 weeks, his therapy

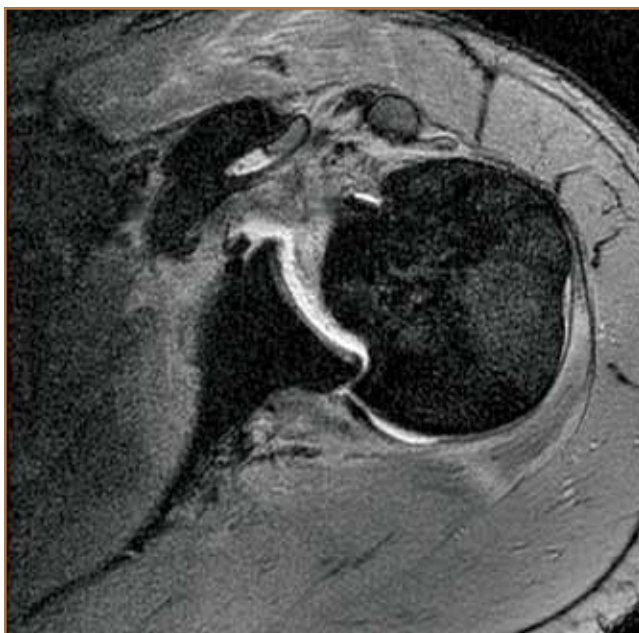

Figure 2. Axial T2-weighted MRI arthrogram of the left shoulder, taken 2 weeks postinjury, demonstrating a posterior glenohumeral dislocation, with large reverse Hill-Sachs lesion, and complete tear of the subscapularis.



Figure 3. Six-month postoperative clinic visit demonstrating near full forward flexion (A), external rotation (B), and internal rotation (C).

regimen included external rotation strengthening and assisted internal rotation ROM. At this point, he returned to work full-time and was very satisfied with his progress. Six-month postoperatively, his active ROM included 170° of forward flexion, 170° of abduction, 60° of external rotation, and internal rotation to the lumbar spine (Figures 3A-C). His rotator cuff strength was full, except for some mild weakness with belly press testing, which would be expected given his subscapularis transfer. Radiographs demonstrated a congruent glenohumeral joint without evidence of hardware complication (Figures 4A, 4B). At 1-year follow-up, he had achieved internal rotation to the lower thoracic spine. He did not experience any repeat episodes of instability of the shoulder.

Discussion

Traumatic posterior dislocations are rare, accounting for fewer than 3% of all shoulder dislocations.⁹ A recent study estimated the prevalence of posterior dislocation to be as low as 1.1 per 100,000 per year.¹¹ The mechanism of these injuries typically involves high-energy trauma, seizure, or electrocution.⁹ Given their infrequent presentation, these dislocations may often be missed, which leads to a delay in diagnosis and errors in management. It is well established that traumatic posterior dislocations are associated with anterior humeral impression fractures.⁸ This characteristic fracture pattern is thought to result from contraction of the deltoid and subscapularis muscles, which force the anterior humeral head against the posterior rim of the glenoid.⁷ When these defects involve 25%-50% of the humeral head, they commonly lead to posterior instability if not addressed.² The modified McLaughlin procedure, which involves transposition of the osteotomized lesser tuberosity with attached subscapularis tendon into the humeral head defect, is commonly used to re-establish stability, with good results.⁶ Although multiple treatment modalities have been advocated for locked posterior dislocations with associated an-

terior humeral impression fractures, the modified McLaughlin procedure has been shown to produce satisfactory results in multiple subsequent small series. Finklestein and colleagues⁵ reported on a series of patients treated with this method that were quickly able to return to activities of daily living.

Several other options were available to us to address this defect besides the modified McLaughlin procedure. The use of allograft to fill in the defect has been described with good results.⁴ We prefer the use of autologous tissue when possible, as we believe this provides quicker integration and healing, allowing for early physical therapy. Arthroplasty has also been described, but based on an intraoperative assessment of the size of the defect and patient age, we did not feel this was appropriate. Although not a concern when the subscapularis is intact, the use of a screw and washer construct in our treatment rendered fixation that was intra-articular. As such, consideration had been given to headless screws for fixation to avoid this. However, based on an intraoperative assessment of the bone quality and the osteotomized tuberosity, we felt a screw and washer construct would provide the best compression of the fragment. In follow-up, we have not noted any complications secondary to the hardware chosen and position. Another benefit to our technique was that transfer of the subscapularis lateral to the tuberosity graft most likely assisted in healing of the bone by creating compression against the tuberosity. By fixing the subscapularis lateral to the transferred graft, the muscle served to provide both a static—in neutral and external rotation—and dynamic compressive force to further stabilize the transferred bone graft.

The role of the subscapularis cannot be understated in shoulder stability. Subscapularis muscle contraction causes tensioning and contraction of the anterior capsular structures, and the muscle bulk provides a buttress effect.¹² This stabilizing role is clear with regards to anterior stability, though not as defined in posterior stability. In addition, subscapularis tears

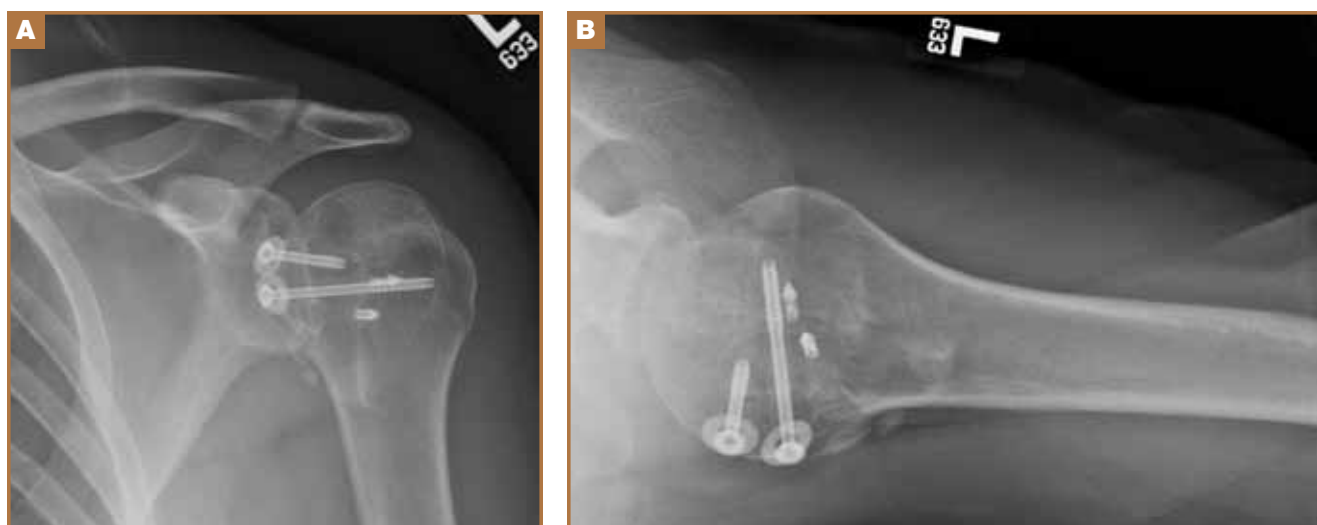


Figure 4. Anteroposterior (A) and axillary (B) radiographs of the left shoulder performed 6 months postoperatively, demonstrating that fragment fixation and glenohumeral reduction are maintained.

have been associated with anterior glenohumeral dislocations, though the same association has not been robustly reported with posterior dislocations.¹³ It is well-established that the rotator cuff is one of the key dynamic stabilizers of the glenohumeral joint, and it has been noted that of the 4 rotator cuff muscles, the subscapularis provides the greatest resistance to posterior translation.¹⁴

The patient presented in this case not only had an anterior humeral impression fracture after traumatic posterior dislocation, but also had an associated acute subscapularis rupture. It is likely that his previous subscapularis repair 18 years prior to presentation compromised the integrity of his tendon. A possible explanation is that his previous injury was a result of a prior posterior dislocation or subluxation, where the subscapularis was sheared off by the anterior rim of the glenoid. This mechanism has been described in adolescent hockey players.¹⁵ The combination made management of the patient's injury more challenging, as repair of the ruptured subscapularis needed to be addressed in addition to the lesser tuberosity transfer. Repairing the ruptured subscapularis tendon through suture anchors into the medial aspect of the original lesser tuberosity footprint provided a reliable repair. After adequate immobilization for tendon healing and compliance with physical therapy, the patient had a successful outcome, with near full ROM and return to activities within 6 months.

Conclusion

This case represents an instance where the modified McLaughlin procedure can be applied successfully to the treatment of a locked posterior dislocation with reverse Hill-Sachs lesion in spite of a concomitant ruptured subscapularis tendon. In this case, repair of the ruptured subscapularis was accomplished through suture anchors into the lesser tuberosity with an excellent clinical outcome.

.....

Dr. Moussa is Resident, Department of Orthopaedic Surgery, Brigham and Women's Hospital, Boston, Massachusetts; Harvard Combined Orthopaedic Residency Program, Massachusetts General Hospital, Boston, Massachusetts. Dr. Boykin is Sports Medicine Fellow, The Steadman Clinic, Vail, Colorado. Dr. Earp is Instructor of Orthopaedic Surgery, Harvard Medical School, Department of

Orthopaedic Surgery, Brigham and Women's Hospital, Boston, Massachusetts.

Address correspondence to: Mohamed E. Moussa, MD, Hospital for Special Surgery, 535 E 70th St, New York, NY 10021 (tel, 646-797-8226; fax, 212-774-2824; e-mail, moussam@hss.edu).

Am J Orthop. 2013;43(12):E121-E124. Copyright Frontline Medical Communications Inc. 2013. All rights reserved.

References

1. Cheng SL, Mackay MB, Richards RR. Treatment of locked posterior fracture-dislocations of the shoulder by total shoulder arthroplasty. *J Shoulder Elbow Surg.* 1997;6(1):11-17.
2. Cicak N. Posterior dislocation of the shoulder. *J Bone Joint Surg Br.* 2004;86(3):324-332.
3. Dervin GF, Brunet JA, Healey DC. A modification of the McLaughlin procedure as salvage for missed locked posterior fracture-dislocation of the humeral head: a case report. *J Bone Joint Surg Am.* 2002;84-A(5):804-807.
4. Diklic ID, Ganic ZD, Blagojevic ZD, Nho SJ, Romeo AA. Treatment of locked chronic posterior dislocation of the shoulder by reconstruction of the defect in the humeral head with an allograft. *J Bone Joint Surg Br.* 2010;92(1):71-76.
5. Finkelstein JA, Waddell JP, O'Driscoll SW, Vincent G. Acute posterior fracture dislocations of the shoulder treated with the Neer modification of the McLaughlin procedure. *J Orthop Trauma.* 1995;9(3):190-193.
6. Hawkins RJ, Neer CS 2nd, Pianta RM, Mendoza FX. Locked posterior dislocation of the shoulder. *J Bone Joint Surg Am.* 1987;69(1):9-18.
7. Keppler P, Holz U, Thielemann FW, Meinig R. Locked posterior dislocation of the shoulder: treatment using rotational osteotomy of the humerus. *J Orthop Trauma.* 1994;8(4):286-292.
8. McLaughlin HL. Posterior dislocation of the shoulder. *J Bone Joint Surg Am.* 1952;24-A-3:584-590.
9. Robinson CM, Aderinto J. Posterior shoulder dislocations and fracture-dislocations. *J Bone Joint Surg Am.* 2005; 87(3):639-650.
10. Bloom MH, Obata WG. Diagnosis of posterior dislocation of the shoulder with use of Velpeau axillary and angle-up roentgenographic views. *J Bone Joint Surg Am.* 1967;49(5):943-949.
11. Robinson CM, Seah M, Akhtar MA. The epidemiology, risk of recurrence, and functional outcome after an acute traumatic posterior dislocation of the shoulder. *J Bone Joint Surg Am.* 2011;93(17):1605-1613.
12. Lyons RP, Green A. Subscapularis tendon tears. *J Am Acad Orthop Surg.* 2005;13(5):353-363.
13. Neviasser RJ, Neviasser TJ. Recurrent instability of the shoulder after age 40. *J Shoulder Elbow Surg.* 1995;4(6):416-418.
14. Millett PJ, Clavert P, Hatch GF 3rd, Warner JJ. Recurrent posterior shoulder instability. *J Am Acad Orthop Surg.* 2006;14(8):464-476.
15. Echlin PS, Plomaritis ST, Peck DM, Skopelja, EN. Subscapularis avulsion fractures in 2 pediatric ice hockey players. *Am J Orthop (Belle Mead NJ).* 2006;35(6):281-284.

This paper will be judged for the Resident Writer's Award.
