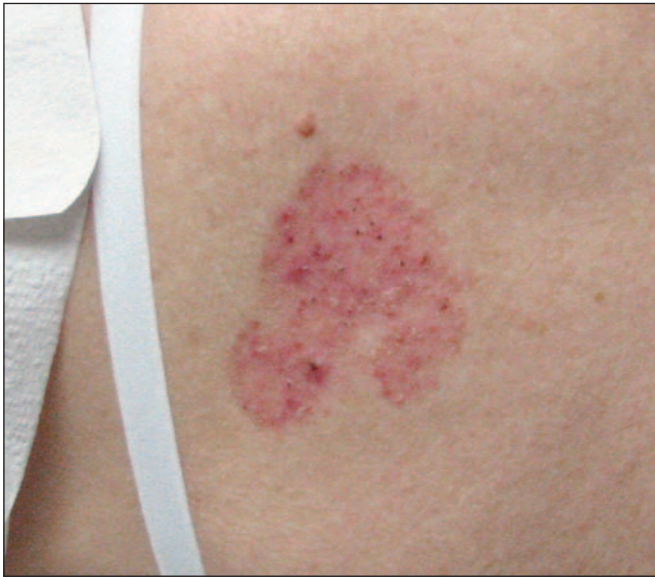

# Diagnosis at a Glance

Stephen M. Schleicher, MD, and A.J. Himmelsbach, MS, MSN, CRNP

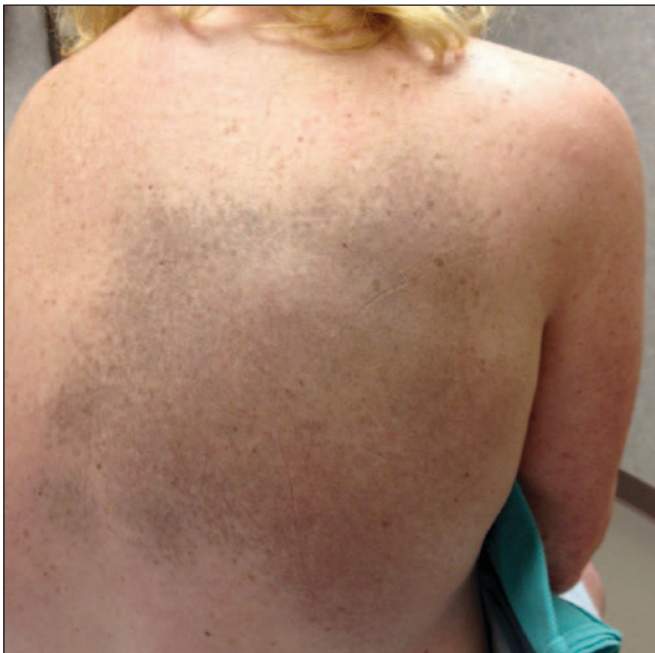


Case submitted by Dr. Schleicher.

## CASE 1

A 66-year-old woman presents with a rash on her back. She states that the dermatitis was first noted some 5 years ago and that it has been slowly extending in diameter. She denies pruritus or bleeding. The patient is a smoker and is taking a diuretic for hypertension. A family doctor diagnosed psoriasis, but a 2-month course of a potent topical steroid has had no effect. Examination reveals an erythematous, slightly atrophic patch with the greatest diameter measuring 3.5 cm. Scattered telangiectasias are apparent when the lesion is viewed under a magnifying glass.

**What is your diagnosis?**



Case submitted by Dr. Schleicher and Mr. Himmelsbach.

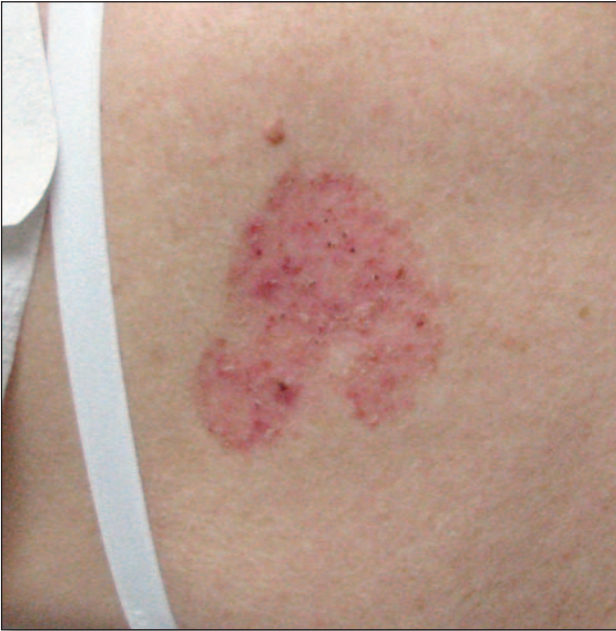## CASE 2

A 53-year-old fair-skinned woman seeks consultation for an irritant hand dermatitis. Given the patient's family history of skin cancer and personal history of severe sunburns, a full-body examination is performed. Examination of her back reveals a large zone of macular hyperpigmentation. The patient states that she has been aware of this finding since her early teens and that it has never been associated with any symptoms (eg, itching, tingling, or burning). She denies personal or family history of Addison disease and hemochromatosis, and states she has never taken medications associated with cutaneous pigmentation, such as minocycline and amiodarone.

**What is your diagnosis?**

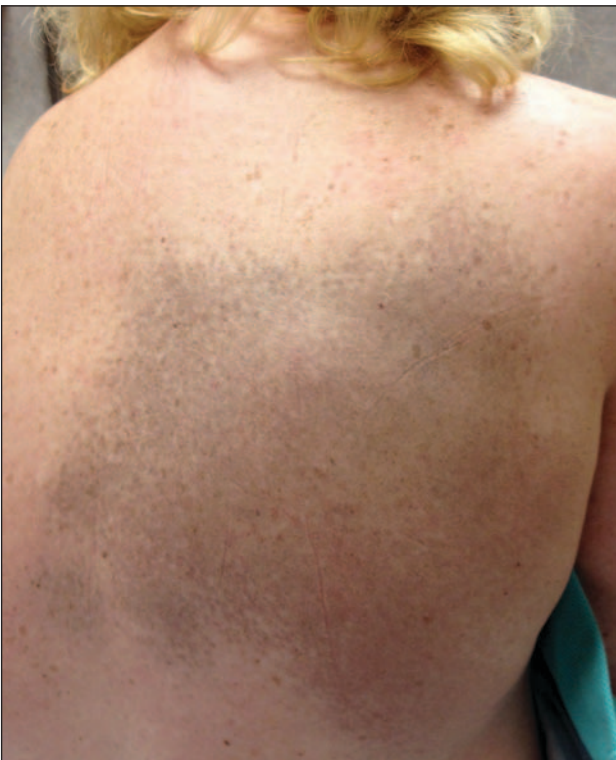**Dr. Schleicher**, editor of "Diagnosis at a Glance," is director of the DermDOX Center in Hazleton, Pennsylvania, a clinical instructor of dermatology at King's College in Wilkes-Barre, Pennsylvania, an associate professor of medicine at the Commonwealth Medical College in Scranton, Pennsylvania, and an adjunct assistant professor of dermatology at the University of Pennsylvania in Philadelphia. He is also a member of the EMERGENCY MEDICINE editorial board. **Mr. Himmelsbach** is a nurse practitioner at Berks Plastic Surgery in Wyomissing, Pennsylvania.

### ANSWER



#### CASE 1

Superficial basal cell carcinomas are a not uncommonly encountered subset of basal cell carcinomas that emerge from the deepest cell layer of the epidermis and penetrate only to the upper layer of the dermis. These neoplasms affect white-skinned individuals and are linked to both a hereditary predisposition and ultraviolet light exposure. The classic appearance is a pink to reddened erythematous patch whose appearance may be similar to that of psoriasis or eczema. Over time, the patch acquires a scaly or crusty texture. Small ulcerations arise if the condition is neglected. Metastatic spread is extremely rare. Treatment options include curettage, surgical excision, cryosurgery, and topical therapy with imiquimod cream.



#### CASE 2

Nevus of Ito is a variant of the dermal melanocytoses, which are characterized by an abundance of spindle-shaped melanocytes within the dermis. The condition occurs on the shoulder and upper back. A similar dermatosis, occurring on the face, is called *nevus of Ota*. Both entities are most commonly found in Asian populations, especially among females; occurrence in a Caucasian is quite uncommon. Classic for these conditions is the appearance of blue-to-gray speckled or mottled macules that tend to coalesce. Usually asymptomatic, these disorders may be associated with sensory changes in the affected area. Malignant transformation has rarely been reported.