

# Verrucous Carcinoma Occurring in a Lesion of Oral Lichen Planus

Erin M. Warshaw, MD, Minneapolis, Minnesota

Stephen F. Templeton, MD, Atlanta, Georgia

Carl V. Washington, MD, Atlanta, Georgia

*Verrucous carcinoma of the oral cavity is relatively rare. Well-documented associations include human papillomavirus and carcinogens such as tobacco. Less well understood is the association with chronic inflammation, such as seen in lichen planus. Verrucous carcinoma has previously been described occurring in lesions of lichen planus of the foot and penis. We report the first case, to our knowledge, of verrucous carcinoma occurring in a lesion of oral lichen planus.*

Verrucous carcinoma is a low-grade squamous cell carcinoma found primarily in the oropharynx, genitalia, or plantar surfaces.<sup>1</sup> In 1948, Ackerman<sup>2</sup> reported 31 cases of well-defined squamous cell carcinomas of the oral cavity with unique clinicopathologic features and coined the term “verrucous carcinoma” for these tumors. Synonyms for oral verrucous carcinoma include Ackerman tumor, verrucous carcinoma of Ackerman, and oral florid papillomatosis. This tumor is relatively rare,<sup>3,6</sup> accounting for 4.5 to 9% of oral squamous tumors. It appears clinically as a slowly enlarging, gray-white verrucous papule.<sup>7</sup> Because of its benign appearance and bland histopathologic features mimicking verruca vulgaris or pseudoepitheliomatous hyperplasia, lengthy periods of misdiagnosis often occur.<sup>1</sup>

As reviewed by Schwartz,<sup>1</sup> verrucous carcinomas have been most commonly associated with laryngeal and anogenital human papillomavirus (HPV) and tobacco or snuff-dipping (oropharynx). Cutaneous verrucous carcinomas have been reported in sites of ulcers, gunshot wounds, scars, or in chronically inflamed cysts. While lichen planus on the soles<sup>8</sup> and penis<sup>9</sup> has been reported as a precursor of verrucous

carcinoma, the association with oral lichen planus has not been reported. We describe the first case, to our knowledge, of verrucous carcinoma occurring in oral lichen planus.

## Case Report

A 70-year-old healthy, nonsmoking woman presented with a 15-month history of an asymptomatic, slowly enlarging lesion on her lower lip. Biopsy specimens of the lesion 12 and 7 months prior to presentation were diagnostic of lichen planus exhibiting lichenoid interface mucositis without atypia (Figure 1). Intralesional and topical steroids were unsuccessful in slowing the progressive growth of the lesion.

Examination at presentation revealed a 1.7- × 1.5-cm violaceous, nonulcerated, lobulated nodule with an overlying white, moist reticulated surface on the right lower lip involving the vermilion border (Figure 2). Results of oral examination revealed faint, lacy white plaques on the right buccal mucosa. Dusky, violaceous, 2- to 4-mm flat-topped papules were present on both ventral forearms. Nail abnormalities and adenopathy were not present. Histopathologic examination of a left arm lesion showed focal interface changes consistent with a resolving lesion of lichen planus. Shave excision of the lip lesion revealed a neoplasm comprised of interconnected lobules of large pale keratinocytes with minimal cytologic atypia extending from the epidermis to the skeletal muscle, consistent with the diagnosis of verrucous carcinoma (Figure 3).

Complete excision using Mohs' micrographic surgical technique was performed. Unfortunately, this verrucous carcinoma recurred 9 months later. The patient underwent repeat Mohs' excision and there was no further recurrence at 6 months post re-excision.

## Comments

Verrucous carcinoma is an uncommon, low-grade, squamous cell carcinoma. Our case exemplifies many of the common characteristics associated with this tumor: slow growth, lengthy time prior to diagnosis, occurrence in the elderly (although more commonly in men),<sup>5</sup> and lack of metastatic spread. The unusual

---

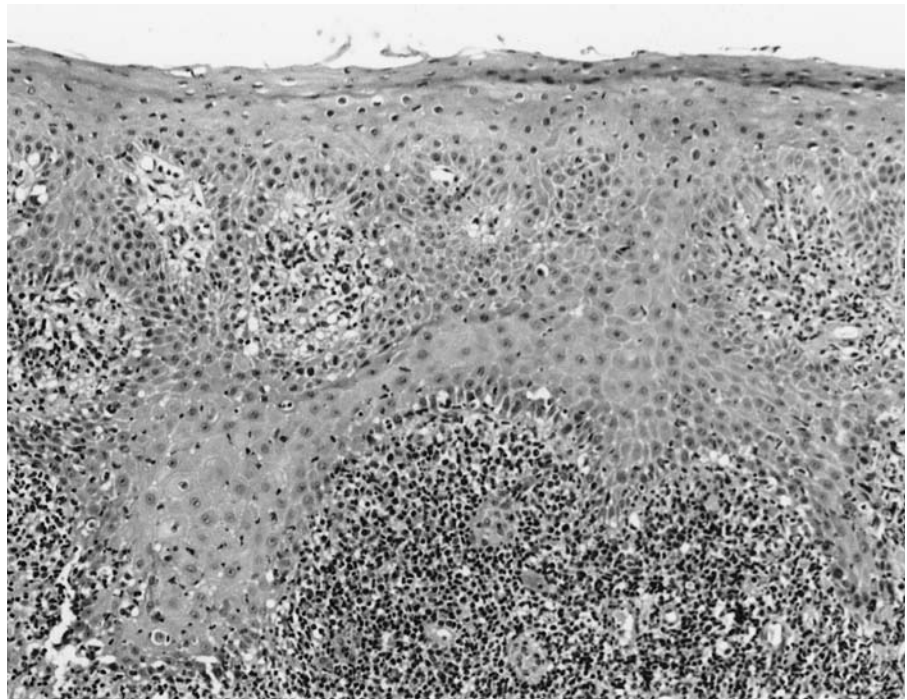
From the Departments of Dermatology and Pathology, Emory University, Atlanta, Georgia.

Dr. Warshaw is now at the Department of Dermatology, University of Minnesota and Veterans Affairs Medical Center, Minneapolis, Minnesota.

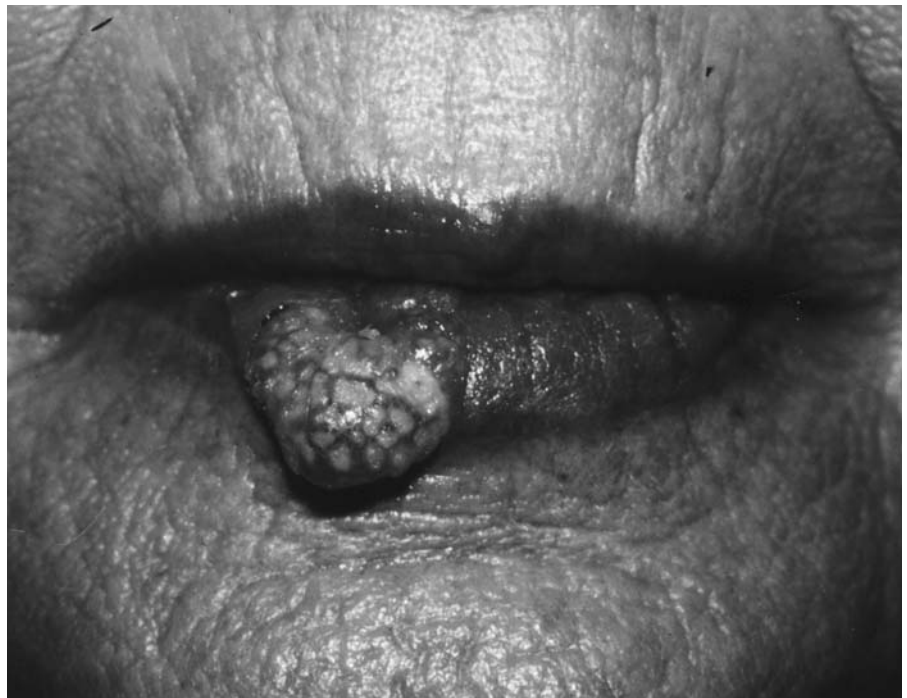REPRINT REQUESTS to Department 111K, Dermatology, VA Medical Center, 1 Veterans Drive, Minneapolis, Minnesota 55417 (Dr. Warshaw).

## VERRUCOUS CARCINOMA

**FIGURE 1.** Biopsy specimen from lip lesion one year prior to presentation. Prominent lichenoid interface dermatitis, Civatte bodies, and saw-tooth appearance of rete ridges are consistent with the diagnosis of lichen planus (H&E; original magnification,  $\times 100$ ).



**FIGURE 2.** Lip lesion at presentation.

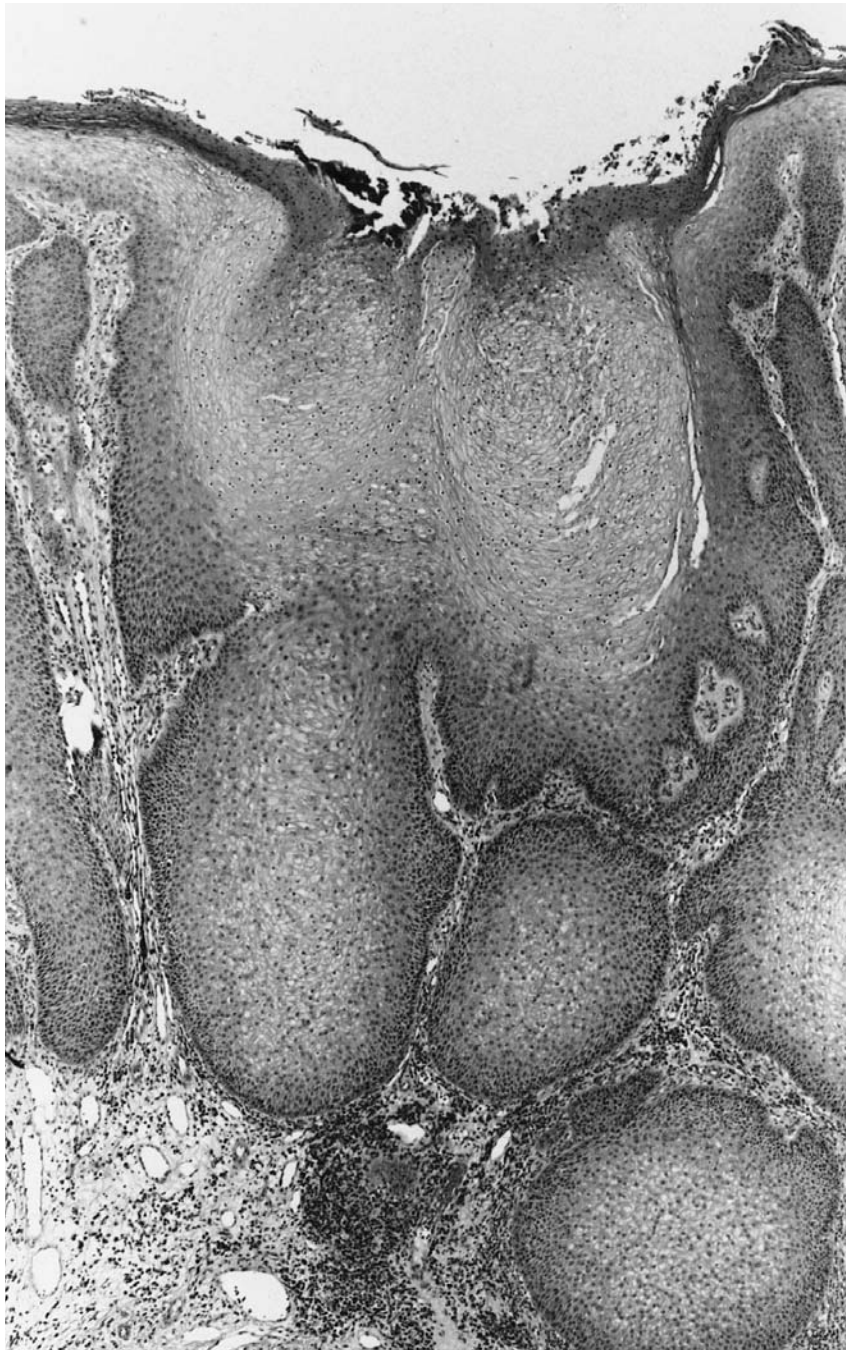

features of verrucous carcinoma observed in this patient include the location as well as the association with pre-existing lichen planus.

The most common sites of oral verrucous carcinoma are buccal mucosa and gingival/alveolar ridge. In a recent review by Florin *et al*,<sup>7</sup> only 44 of 362 (12%) reported cases of oral verrucous carcinoma occurred on the lip. Of these, 12 occurred on the “mu-

cosa/inner lip,” 13 on the labial commissure, and 19 were “site not specified.” Involvement of the vermilion border was not reported.<sup>7</sup> Occurrence of verrucous carcinoma on the vermilion border, as seen in our patient, appears to be very rare.

Causative factors most strongly associated with verrucous carcinoma of the oral cavity include tobacco use and HPV infection. In Ackerman’s<sup>2</sup> origi-



**FIGURE 3.** Shave biopsy specimen from lip lesion. Note interconnected lobules of large pale keratinocytes with minimal cytological atypia consistent with verrucous carcinoma (H&E; original magnification,  $\times 40$ ).

nal series, 11 of 18 (61%) patients chewed tobacco. The Medina *et al*<sup>5</sup> series of 107 patients had an 84% prevalence of tobacco use including smoking, chewing, and snuffing. The Vidyasagar *et al*<sup>10</sup> series of 107 Indian patients found a 79% habit of chewing “pan” (a mixture of lime, betel nuts, betel leaf, and tobacco). Our patient denied tobacco use. Several HPV types have been associated with oral verrucous carcinoma.

The Shroyer *et al*<sup>11</sup> series of 17 patients with oral verrucous carcinoma found evidence by polymerase chain reaction of HPV in seven (41%) patients. A study of 29 cases of laryngeal verrucous carcinoma showed evidence of HPV-16, HPV-18, or both in 13 (45%) cases.<sup>12</sup> The association with other factors such as poorly fitting dentures and poor oral hygiene has also been reported.<sup>7,13</sup>

Pathogenesis for verrucous carcinoma may include oncogene expression by HPV, chemical carcinogenesis secondary to mucosal carcinogens such as tobacco, or chronic inflammation as evidenced by the association of schistosomiasis of the bladder and verrucous carcinoma in that location.<sup>1</sup> It appears that chronic inflammation associated with lichen planus may have been the stimulus for verrucous carcinoma in our patient.

The clinical differential diagnosis of white, oral papules, and plaques includes squamous cell carcinoma, amelanotic melanoma, deep mycotic infections (especially histoplasmosis), *Candida*, verruca vulgaris, secondary lues, Darier’s disease, white sponge nevus, Crohn’s disease, discoid lupus erythematosus, and pyostomatitis vegetans. Verrucous carcinoma is frequently misdiagnosed, often due to superficial, inadequate biopsy specimens or because the pathologist is unaware of the clinical size, site, and duration of the lesion.<sup>8</sup> A deep-wedge incisional or excisional biopsy specimen is usually necessary.

The incidence of squamous cell carcinoma occurring within lesions of oral lichen planus has been reported<sup>14</sup> to be as high as 10%. Several authors fault studies with such high incidences for having poor documentation, incorrect diagnosis of the preceding lichen planus lesions, or both.<sup>14,15</sup> Several review articles have found that only about 1% of reported cases of squamous cell carcinoma occurring in lesions of lichen planus fulfilled the proper

diagnostic criteria for both diagnoses.<sup>14-17</sup> Therefore, it appears that malignant transformation of oral lichen planus occurs at a much lower rate than previously thought. To our knowledge, there have been no previous reports of verrucous carcinoma occurring in an oral lesion of lichen planus.

Treatment of verrucous carcinoma may include surgery (including Mohs' micrographic surgery), radiotherapy, photodynamic therapy, administration of bleomycin, methotrexate, and various combinations of these therapies.<sup>1</sup> Surgery is generally the modality of choice to treat oral lesions. Several cases were reported in the 1960s of "anaplastic transformation" occurring in verrucous carcinomas treated with radiotherapy in 1982.<sup>7</sup> McDonald *et al*<sup>18</sup> reviewed these reports and found that only four met the histopathologic criteria for verrucous carcinoma, and were, in fact, invasive squamous cell carcinomas prior to radiotherapy treatment. They concluded that radiotherapy should not be first-line therapy for extensive lesions because of this potential for anaplastic transformation, but should be used in patients with poor response to surgical resection.<sup>18</sup> Regardless of the therapeutic modality, local recurrences are common.<sup>1</sup>

In summary, we report a case of verrucous carcinoma occurring in a lesion of lichen planus of the lip that is significant for three reasons. 1) The vermilion border is an unusual location for verrucous carcinoma. 2) Although squamous cell carcinoma has been reported to occur in oral lichen planus, to our knowledge this is the first description of verrucous carcinoma occurring in a lesion of oral lichen planus. 3) Recurrence after surgery illustrates the need for close follow-up of these patients.

## REFERENCES

1. Schwartz RA: Verrucous carcinoma of the skin and mucosa. *J Am Acad Dermatol* 32: 1-21, 1995.
2. Ackerman LV: Verrucous carcinoma of the oral cavity. *Surgery* 23: 670-678, 1948.
3. Goethals PL, Harrison EG, Edvine KD: Verrucous squamous carcinoma of the oral cavity. *Am J Surg* 106: 845-850, 1963.
4. Slootweg PJ, Muller H: Verrucous hyperplasia or verrucous carcinoma: an analysis of 27 patients. *J Maxillofac Surg* 11: 13-19, 1983.
5. Medina JE, Dichtel W, Luna MA: Verrucous squamous carcinomas of the oral cavity: a clinicopathologic study of 104 cases. *Arch Otolaryngol* 110: 437-440, 1984.
6. McCoy JM, Waldron CA: Verrucous carcinoma of the oral cavity: a review of 49 cases. *Oral Surg* 52: 623-629, 1981.
7. Florin EH, Kolbusz RV, Goldberg LH: Verrucous carcinoma of the oral cavity. *Int J Dermatol* 33: 618-622, 1994.
8. Mayron R, Grimwood RE, Siegle RJ, *et al.*: Verrucous carcinoma arising in ulcerative lichen planus of the soles. *J Dermatol Surg Oncol* 14: 547-551, 1988.
9. Bain L, Geroneumus R: The association of lichen planus of the penis with squamous cell carcinoma *in situ* and with verrucous squamous carcinoma. *J Dermatol Surg Oncol* 15: 413-417, 1989.
10. Vidyasagar MS, Fernandes DJ, Akhileshwaran K, *et al.*: Radiotherapy and verrucous carcinoma of the oral cavity: a study of 107 cases. *Acta Oncol* 31: 43-47, 1992.
11. Shroyer KR, Greer RO, Fankhouser CA, *et al.*: Detection of human papillomavirus DNA in oral verrucous carcinoma by polymerase chain reaction. *Mod Pathol* 6: 669-672, 1993.
12. Fliss DM, Noble-Topham SE, McLachlin CM, *et al.*: Laryngeal verrucous carcinoma: a clinicopathologic study and detection of human papillomavirus using polymerase chain reaction. *Laryngoscope* 104: 146-152, 1994.
13. Fonts EA, Greenlaw RH, Rush BF, *et al.*: Verrucous squamous cell carcinoma of the oral cavity. *Cancer* 23: 152-159, 1969.
14. Fulling HJ: Cancer development in oral lichen planus. A follow-up study of 327 patients. *Arch Dermatol* 108: 667-669, 1973.
15. Reisman RJ, Schwartz AE, Friedman EW, *et al.*: The malignant potential of oral lichen planus—diagnostic pitfalls. *Oral Surg* 38: 227-232, 1974.
16. Kaplan B, Barnes L: Oral lichen planus and squamous carcinoma: case report and update of the literature. *Arch Otolaryngol* 11: 543-547, 1985.
17. Murti PR, Dartary DK, Bhonsle RB, *et al.*: Malignant potential of oral lichen planus: observations in 722 patients from India. *J Oral Pathol* 15: 71-77, 1986.
18. McDonald JS, Crissman JD, Gluckman JL: Verrucous carcinoma of the oral cavity. *Head Neck Surg* 5: 22-28, 1982.