

Malignant Melanoma with Zosteriform Metastases

Esther Cuerda Galindo, MD, Madrid, Spain
Francisco Sánchez de Paz, MD, Madrid, Spain
Isabel Mansilla Pérez, MD, Madrid, Spain
Olga Poza Madalena, MD, Madrid, Spain
Marta Casellas Bravo, MD, Madrid, Spain

Melanoma is a tumor that has a high tendency to metastasize to the skin. Zosteriform metastases are a rare form of metastasizing melanoma. We describe a 79-year-old man with melanoma presenting with a dermatomal distribution and no visceral metastases.

Melanoma is a tumor that is known for its ability to metastasize to nonvisceral sites such as skin, subcutaneous tissue, and regional lymph nodes in up to 42 to 57% of cases. Metastases in visceral sites can be divided as follows¹: 1) lung, 18 to 36%; 2) liver, 14 to 20%; 3) brain, 12 to 20%; and 4) bone, 11 to 17%.

Melanoma has a high tendency to metastasize to the skin. In an autopsy series of patients who died with melanoma as the direct cause of death, or with a coexisting melanoma at the moment of death, up to a 50% incidence of cutaneous metastases was found. These metastases can appear following a zosteriform pattern, as we describe here.

Case Report

A 79-year-old man had a clinical history that included chronic obstructive lung disease treated with bronchodilator drugs and cholecystectomy.

In July 1998, the patient presented after he observed a nodular, pigmented lesion on the trunk, in the left submammary region, near the armpit, measuring 2 × 1.5 cm, with an undetermined growth period. Clinical diagnosis of melanoma was made and the tumor was excised. Results of the preoperative study, including chest roentgenograms, blood test, and electrocardiogram, were normal.

The histologic study showed a Breslow 4-mm melanoma. Two months later, a prophylactic axillary lymphadenectomy was performed (negative lymph nodes).

The last follow-up was made in May 1999, and it included the following diagnostic procedures: 1) chest X-rays — small basal atelectases were found and were thought to be compatible with his chronic lung disease; 2) normal blood test; 3) absence of melanuria; and 4) abdominal ultrasonography revealing cysts on the right kidney. There were no echographic signs of tumoral damage of the liver.

Two months later, the patient was referred to the Dermatology service due to a 1-month history of an asymptomatic lesion on the chest (left submammary region), with a typical zosteriform distribution, consisting of infiltrated, amelanotic, lustrous papules measuring 0.5 cm or less in diameter, which had been treated by his general practitioner with topical glucocorticoids and H1-antihistamines without any signs of improvement (Figure 1).

A 6-mm punch-biopsy was taken. Microscopic examination disclosed a band of atypical melanocytes that was distributed along the dermis and did not affect the epidermic level (Figure 2). A certain degree of the keratinocytic epidermis was observed and there were no intraepidermal melanocytes. A diagnosis of metastatic melanoma was made.

Discussion

Up to a 19% of cutaneous and subcutaneous metastases in melanoma appear on the site where the original tumor was previously located. Medical literature describes only two cases of melanoma presenting with zosteriform metastases along a thoracic dermatome, and both patients already had visceral metastases.^{2,3} Our patient had no evidence of visceral metastases at the time skin metastases were described.

From the Department of Dermatology, Hospital Universitario Clínico San Carlos, Universidad Complutense de Madrid, Spain. REPRINT REQUESTS to C/Saavedra Fajardo 11, 5^oE, 28011 Madrid, Spain (Dr. Galindo).

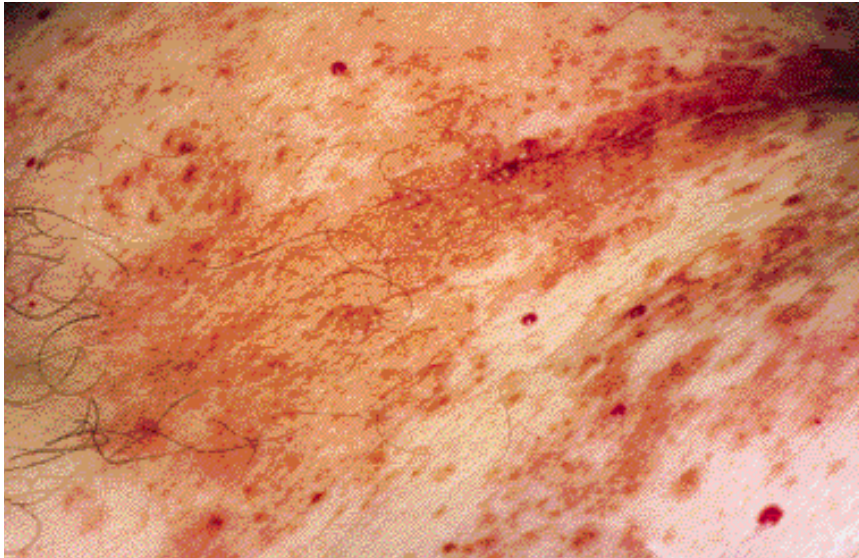


FIGURE 1. An amelanotic nodular skin eruption in the sixth thoracic dermatome. Bottom, scar resulting after the excision of the melanoma.

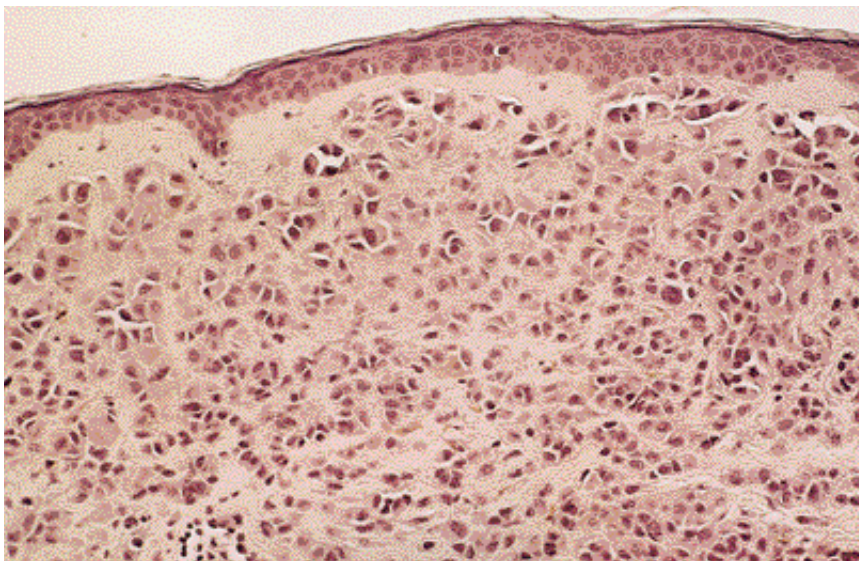


FIGURE 2. A 6-mm punch biopsy shows a band of atypical melanocytes along the dermis (H&E stain; original magnification, $\times 200$).

Skin metastases of any tumor-presenting zosteriform distribution are rare. There are cases reported with: 1) skin cancer — melanoma^{2,3} and/or squamous cell carcinoma⁴; 2) vascular malignancies — Kaposi's sarcoma⁵ and/or angiosarcoma⁶; 3) hematologic malignancies — mycosis fungoides⁷ and/or leukemia⁸; 4) visceral tumors — lung⁹ and/or prostate.¹⁰

There are several theories that try to explain a tumoral dissemination following a dermatomal eruption. Some of the cases mentioned above presented a zoster infection before metastatic lesions were observed along the same dermatome. Thus, a Koebner phenomenon could be postulated.^{5,6} In other cases with no recent zoster infection, the pathophysiology must be different. It is reasonable to consider metastatic spread by perineural lymphatic invasion or tumor invasion of dorsal ganglia with peripheral extension along a dermatome.³

The case report had no Koebner phenomenon before, and elective lymph node dissection was made. But this prophylactic lymphadenectomy was made in the armpit, and zosteriform metastases could suggest an invasion of a dorsal ganglia. In this study, therefore, and as noted previously, we cannot reject melanoma invasion of dorsal ganglia with peripheral extension along a dermatome or affirm spread by perineural lymphatic invasion.

Conclusion

Zosteriform metastases are a rare form of metastasizing melanoma. There are several theories that try to explain this rare melanoma dissemination, but none is proved. We describe the third case of melanoma presenting a dermatomal distribution and the first one with no visceral metastases.

MALIGNANT MELANOMA WITH ZOSTERIFORM METASTASES

REFERENCES

1. Meyels M: Diagnosis and treatment of metastatic melanoma. In *Cutaneous Melanoma* (CM Balch, AN Houghton, AJ Sober, SJ Soong), ed 3, pp 325-372. St Louis, Quality Medical, 1998.
2. North S: Recurrent malignant melanoma presenting with zosteriform metastases. *Cutis* 62: 143-146, 1998.
3. Itin PH, Lautenschlager S, Buechner SA: Zosteriform metastases in melanoma. *J Am Acad Dermatol* 32: 854-857, 1995.
4. Buecker JW, Ratz JL: Cutaneous metastatic squamous cell carcinoma in zosteriform distribution. *J Dermatol Surg Oncol* 10: 718-720, 1984.
5. Nietd GW, Prioleau PG: Kaposi's sarcoma occurring in a dermatome previously involved by herpes zoster. *J Am Acad Dermatol* 18: 448-451, 1988.
6. Hudson CP, Hanno R, Callen JP: Cutaneous angiosarcoma in a site of healed herpes zoster. *Int J Dermatol* 23: 404-407, 1984.
7. Williams LR, Levine LJ, Kauh YC: Cutaneous malignancies mimicking herpes zoster. *Int J Dermatol* 30: 432-434, 1991.
8. Barney RE: Zosteriform leukemia cutis. *Arch Dermatol Syph* 37: 238-246, 1938.
9. Matarasso SL, Rosen T: Zosteriform metastases: case presentation review of the literature. *J Dermatol Surg Oncol* 14: 774-777, 1988.
10. Blue Farb SM, Wallk S, Gecht M: Carcinoma of the prostate with zosteriform cutaneous lesions. *Arch Dermatol* 76: 402-406, 1957.