

From The New York-Presbyterian Hospital, Columbia-Presbyterian Center

# Transverse Leukonychia with Systemic Infection

Gail H. Mautner, MD, New York, New York

Irene Lu, MD, New York, New York

Richard J. Ort, MD, New York, New York

Marc E. Grossman, MD, New York, New York

*Transverse white nail bands (leukonychia) have been described in association with systemic illnesses and exposure to toxins, and medications. We describe the occurrence of transverse nail bands in two patients following acute systemic illnesses. In the first case, transverse white nail bands developed in a 30-year-old human immunodeficiency virus-positive man following acute pulmonary tuberculosis. In the second case, transverse white nail bands were noted in an 80-year-old patient following Streptococcus intermedius empyema.*

Acquired transverse white nail bands (leukonychia) are associated with various systemic illnesses. Few have documented the association of these bands with pulmonary tuberculosis or pleural empyema. We describe the development of these bands in a human immunodeficiency virus (HIV)-positive patient with acute pulmonary tuberculosis and in another patient with a left-sided empyema due to *Streptococcus intermedius*.

## Case Report I

A 30-year-old, HIV-positive, homosexual, black man was started on zidovudine in April 1988. Two months later, he noted increased blue-gray pigmentation in the proximal portion of all nails. In April 1993, he was admitted to Columbia Presbyterian Medical Center for fever, diarrhea, weakness, and a persistent cough. His history was significant for a negative purified protein derivative test in 1991 and a brother who had died from tuberculosis. Fevers of 38.8–39.4°C persisted without explanation during the 35-day hospitalization. Although an admission chest radiograph was unremarkable, sputum cultures

revealed *Mycobacterium tuberculosis*. He was started on anti-tuberculosis medications on June 7, 1993.

On July 18, 1993, 3 months after the initial positive acid-fast bacillus sputum culture was obtained, physical examination demonstrated transverse white nail bands against a background of diffusely blue-gray fingernails of both hands (Figure 1). The distal edge of the band was 7 mm and the proximal edge of the band 5 mm from the proximal nail fold.

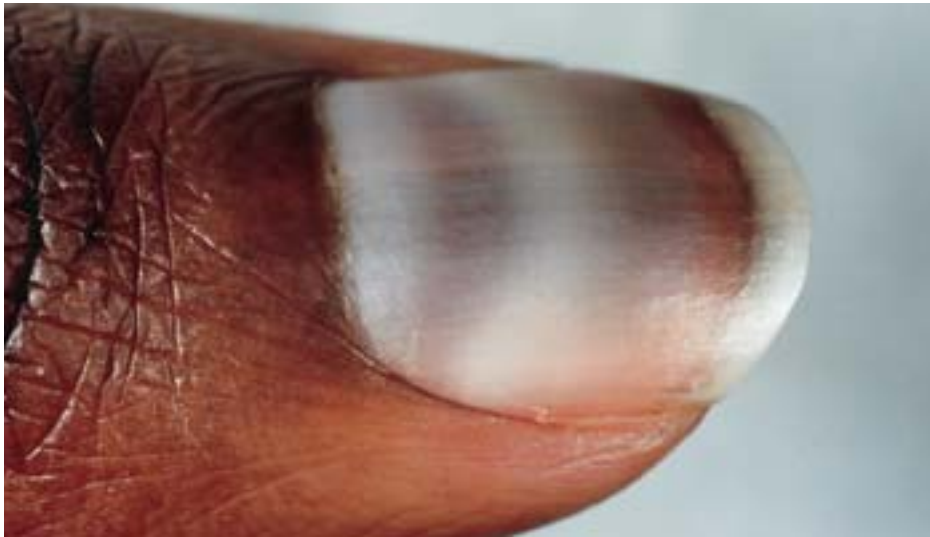
## Case Report II

An 80-year-old man presented on May 11, 1993 to Columbia Presbyterian Medical Center with a 2-week history of progressively increasing left-sided pleuritic chest pain, shortness of breath, low-grade fever, and a non-productive cough. He denied sputum production, hemoptysis, night sweats, chills, or weight loss. He had smoked one pack of cigarettes a day for 30 years, but had last smoked 30 years ago. On physical examination, temperature was 39.2°C, breath sounds were decreased on the left side with egophony, and dullness to percussion was noted over 75% of the left posterior lung field. A chest radiograph showed near-total opacification of the left hemithorax with a shift of the mediastinum to the right, consistent with a large pleural effusion. The white blood cell count was 22,000 with 37% bands present. PaO<sub>2</sub> on room air was 51. Serum albumin and renal function were normal.

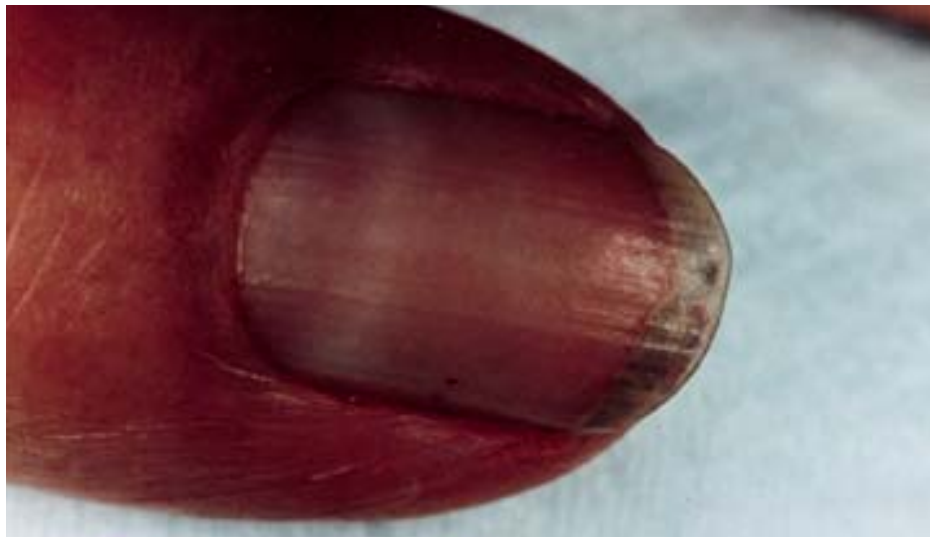Treatment with intravenous antibiotics was begun. A chest tube was placed and subsequent pleural fluid analysis revealed a red blood cell count of 26,500, a white blood cell count of 2900 with 96% neutrophils, protein 4770 mg/dl, glucose 5 mg/dl, leutinizing deficiency hormone 1803 units/liter, and a pH 6.89. A computer tomographic scan of the chest demonstrated a large loculated pleural effusion with possible pneumonia in the left lower and mid-lung zones. Because of the patient's worsening respiratory status, he underwent a left thoracotomy and decortication 8 days following admission. Pleural fluid cultures sub-

From the Dermatology Consultation Service, Columbia-Presbyterian Medical Center, New York, New York.

REPRINT REQUESTS to 12 Greenridge Avenue, White Plains, New York 10605 (Dr. Grossman).



**FIGURE 1.** Transverse leukonychia on a blue-gray nail plate of Case I.



**FIGURE 2.** Transverse white nail band of Case II.

sequently grew *S. intermedius*. The patient received an 8-week course of appropriate antibiotic coverage with resolution of the empyema.

On August 30, 1993, 11 days after the admission for empyema, physical examination revealed transverse white nail bands on all 10 fingernails (Figure 2). The distance to the proximal nail fold measured 4 mm from the proximal edge of the bands and 6 mm from the leading edge. The bands continued to move distally.

### Discussion

Pigmentary nail changes occur in association with various systemic illnesses. Leukonychia is a term used to describe white color nail changes that occur in either the nail plate (true leukonychia) or the nail bed (pseudoleukonychia). The changes involving the nail plate advance as the nail plate grows out while those involving the nail bed remain stationary.

Transverse white nail beds involving the nail plate were described by Mees<sup>1</sup> in 1919 in association with arsenical poisoning. They have also been reported in association with measles,<sup>2</sup> myocardial infarction,<sup>3</sup> pellagra,<sup>4</sup> Hodgkin's disease,<sup>5</sup> acute and chronic renal failure,<sup>6</sup> systemic lupus erythematosus,<sup>7</sup> varicella zoster infection,<sup>8</sup> acute rejection of renal allografts,<sup>9</sup> and with various combinations of chemotherapy.<sup>10</sup>

Pseudoleukonychia occurs in association with hepatic cirrhosis (Terry's nails),<sup>11</sup> hypoalbuminemia (Muehrcke's lines),<sup>12</sup> and in patients with renal failure ("half and half nail").<sup>13</sup> Pseudoleukonychia has also been reported in cases of zinc deficiency<sup>14</sup> and Kawasaki disease.<sup>15</sup>

We report the occurrence of transverse white nail bands in an HIV-infected patient with pulmonary tuberculosis and in another patient following a pleural empyema. These bands were localized to the

nail plate as a demonstrated by their subsequent distal growth.

In an average human nail, approximately 3 mm of the nail plate is located under the proximal nail fold and the growth of the nail plate averages 0.1 mm/day. Since the leading edge of the transverse nail bed was located 6 to 7 mm from the proximal nail fold in each case, we estimated that the nails had grown approximately 10 mm since the onset of the patient's acute illnesses. The distance corresponded with the clinical onset of the acute illnesses.

The histologic cause of true leukonychia has been controversial, although all theories propose that abnormal keratinization is present and that the defect arises in the nail matrix. One view is that small fractures within the nail allow intercellular pockets to form within the nail plate.<sup>8</sup> Most believe that defective keratinization alone is sufficient to produce leukonychia as evidenced histologically by the presence of large nucleated cells and keratohyalin granules within the nail plate.<sup>16</sup>

The blue-gray dyschromia associated with zidovudine therapy in HIV-infected individuals has been well documented in the literature.<sup>17</sup> The dyschromia is reportedly the result of increased melanogenesis of the nail matrix melanocyte. There have been no case reports of transverse white nail bands occurring in these patients.

The causative agent of empyema in the second patient was *S. intermedius*, an organism that has recently been recognized as an important pathogen in suppurative respiratory infections. This organism is a subspecies of the *Streptococcus milleri* family and is considered to be microaerophilic, although some strains require anaerobic conditions. Empyema due to *S. intermedius* is typically associated with early and rapid onset of severe and toxic symptoms, loculations, and pleural thickening.<sup>18</sup> Since the organism is part of the normal flora of the oropharynx, aspiration of oral or gastric contents predisposes to the development of pulmonary infection.

Transverse white nail bands provide a useful means by which to date the onset of a previously undiagnosed or unrecorded medical illness. The distance from the transverse band to the proximal nail fold provides an estimated time of systemic insult, which

corresponds to the development of the systemic illness in each case.

## REFERENCES

1. Mees RA: Een verschijnsel bij polyneuritis arsenicosa. *Nederl T Geneesk* 1: 391-396, 1919.
2. Costa OG, Horizonte B: Leukonychia striata semilunaris. *Arch Derm Syph* 54: 60-61, 1946.
3. Urbach E: White cross striae of the finger nails following cardiac infarction. *Arch Derm Syph* 52: 106-107, 1945.
4. Donald GF, Hunter GA, Gillam BD: Transverse leukonychia due to pellagra. *Arch Dermatol* 85: 530-531, 1962.
5. Ronchese F: Peculiar nail anomalies. *Arch Derm Syph* 63: 565-580, 1951.
6. Hudson JB, Dennis AJ: Transverse white lines in the fingernails after acute and chronic renal failure. *Arch Intern Med* 117: 276-279, 1966.
7. Friedman, SJ: Leukonychia striata associated with systemic lupus erythematosus. *J Am Acad Dermatol* 15: 536-538, 1986.
8. Zizmor J, Deluty S: Acquired leukonychia striata. *Int J Dermatol* 14: 49-50, 1980.
9. Held JL, Chew S, Grossman ME, Kohn SR: Transverse striate leukonychia associated with acute rejection of renal allograft. *J Am Acad Dermatol* 20: 513-514, 1989.
10. James WD, Odom RB: Chemotherapy-induced transverse white nail lines in the fingernail. *Arch Dermatol* 119: 334-335, 1983.
11. Terry RB: White nails in hepatic cirrhosis. *Lancet* 1: 757-759, 1954.
12. Muehrcke RC: The fingernails in chronic hypoalbuminemia. *Br Med J* 1: 1327-1328, 1956.
13. Lindsay PG: The half and half nail. *Arch Intern Med* 119: 583-587, 1967.
14. Grossman M, Scher RK: Leukonychia. *Int J Dermatol* 29: 535-541, 1990.
15. Iosub S, Gromisch DS: Leukonychia partialis in Kawasaki's disease. *J Infect Dis* 150: 617-618, 1984.
16. Albright SD, Wheeler CE: Leukonychia. *Arch Dermatol* 90: 392-399, 1964.
17. Prose NS, Abson KG, Scher RK: Disorders of the nails and hair associated with human immunodeficiency virus infection. *Int J Dermatol* 31: 453-457, 1992.
18. Roy WJ, Roy TM, Davis GJ: Thoracic empyema due to *Streptococcus intermedius*. *J Ky Med Assoc* 89: 558-562, 1991.