

From The New York-Presbyterian Hospital, Columbia-Presbyterian Center

Fusarium Fingernail Infection Responsive to Fluconazole Intermittent Therapy

Stephanie S. Tseng, MD, New York, New York

B. Jack Longley, MD, New York, New York

Richard K. Scher, MD, New York, New York

Ruth Kaplan Treiber, MD, New York, New York

A case of fingernail infection by Fusarium is presented. This nondermatophytic mold is an infrequent cause of onychomycosis, more typically involving the great toenail. Characteristic histologic features including the presence of hyphae and chlamydoconia are helpful in rapid diagnosis and selection of appropriate antifungal therapy. Although Fusarium has shown resistance to most antifungal medications in vitro, intermittent therapy with fluconazole led to improvement in this patient.

Onychomycosis caused by molds other than dermatophytes and *Candida*, such as *Scopulariopsis brevicaulis*, *Scytalidium*, *Fusarium*, *Alternaria*, *Aspergillus*, and *Acremonium*, have been found in various studies in 6 to 22% of cases of onychomycosis.¹ Susceptible groups include the elderly, patients with pre-existing skin disease with nail involvement, and immunocompromised patients. Absence of tinea pedis, involvement of only one or two toenails, history of trauma preceding nail dystrophy, and lack of response to systemic antifungal therapy may all be clues to nail infection by a nondermatophyte mold.² Many molds are sensitive to cycloheximide (found in Mycosel and DTM), necessitating the use of a cycloheximide-free medium such as

Sabouraud's dextrose agar in screening for potential fungal pathogens.³

Fusarium species are soil-borne fungi that have worldwide distribution, although they are more common in tropical/temperate regions. They are known to be plant, animal, and human pathogens.⁴ *Fusarium* (typically *Fusarium oxysporum*) has been reported to cause chromonychia,⁵ white superficial onychomycosis, distal subungual onychomycosis, and proximal subungual onychomycosis with subacute or acute paronychia. Great toenails are almost always involved, particularly in the presence of traumatic or dystrophic abnormalities. Fingernails are rarely affected.^{6,7}

Hyalohyphomycosis refers to an infection by pathogens such as *Fusarium*, *Paecilomyces*, or *Acremonium* in which colorless septate hyphae are formed in host tissue. In hyalohyphomycosis, irregular hyaline hyphae with both 45° and 90° branching, as well as adventitious sporulation (presence of fertile cells and spores known as phialides and conidia, respectively) are seen on histopathologic sections stained with either Gomori methenamine silver or periodic acid-Schiff stains. These morphologic characteristics may be particularly helpful when culture results are not available.⁸

Case Report

A 44-year-old woman presented in September 1997 with persistent infection of the left second fingernail for 18 months. She reported that in July 1996 the finger had become acutely inflamed and painful, accompanied by shedding of the entire nail. She was treated with ciprofloxacin, then itraconazole for 10 days, then fluconazole for several weeks with no response (Figure 1). Pathology report of a nail specimen obtained in December 1996 was interpreted as candidiasis; treatment with daily itraconazole over a

Dr. Tseng is a Resident, Dr. Longley is a Professor of Pathology in Dermatology, Dr. Scher is a Professor of Clinical Dermatology, and Dr. Treiber is an Assistant Clinical Professor, Department of Dermatology, College of Physicians and Surgeons, Columbia University, New York, New York. Dr. Longley is also from the Department of Pathology, College of Physicians and Surgeons, Columbia University, New York, New York.
REPRINT REQUESTS to Columbia University, Department of Dermatology, 161 Fort Washington Avenue, AP-7, New York, NY 10032 (Dr. Treiber).

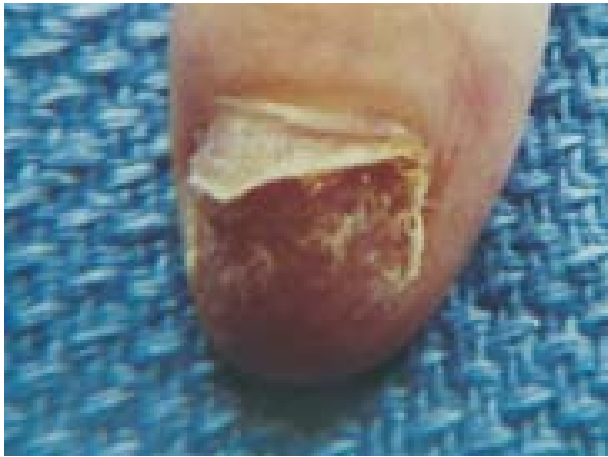

FIGURE 1. Near-complete onycholysis, with nail cut back.

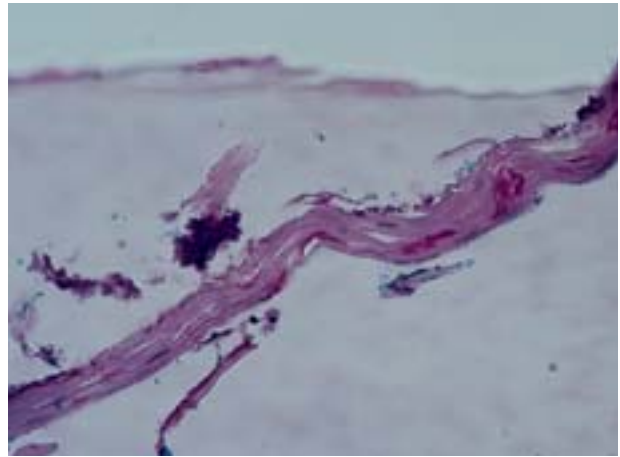


FIGURE 2. Histopathologic examination of nail plate shows thick, distorted periodic acid-Schiff-positive hyphae and chlamydoconia.

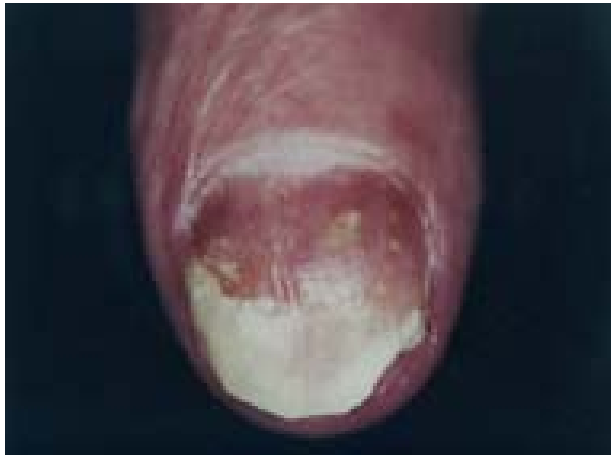

FIGURE 3. Decreased paronychia and yellow nail discoloration after 1 month of intermittent fluconazole therapy.

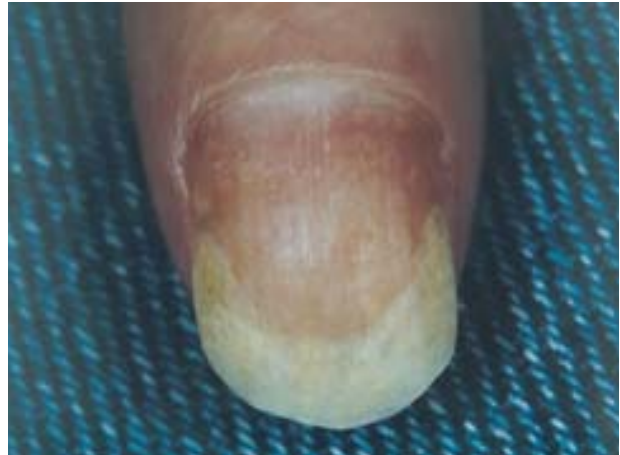

FIGURE 4. Resolution of paronychia with nail regrowth after 7 months of therapy.

4-month period resulted in re-attachment and partial clearing of the nail plate by May 1997. Within 6 weeks of discontinuing the medication, however, the nail infection recurred with nail detachment.

Initial examination showed yellow opaque thickening of the nail plate of the left second finger with distal onycholysis and minimal subungual debris. Bulbous changes of the distal second digit were noted, with tender swelling of the paronychia area. Radiographic examination of the left hand was unremarkable. Clippings and scrapings of the nail plate were sent for fungal culture and histopathology. Econazole cream twice daily following diluted Clorox soaks was started pending return of laboratory results. *Fusarium* species was isolated from the fungal culture; histopathology sections showed distorted, periodic acid-Schiff-positive mycelial structures within the nail plate (Figure 2). The nail was trimmed back and the patient

was switched to terbinafine cream twice daily for 4 weeks. Nail matrix biopsy was performed in November 1997 and was negative for fungal organisms. On follow-up visit, the patient was given cephalexin for 1 week for an inflamed paronychia. Nail clippings for fungal culture and histopathology were repeated and fluconazole 100 mg daily was started.⁹ Histopathology again revealed distorted hyphae; repeat fungal culture confirmed the presence of *Fusarium* species.

Clinical improvement was noted after 2 weeks, at which time fluconazole dosing was changed to 300 mg once weekly, and increased to 300 mg twice weekly 1 month later¹⁰ (Figure 3). Intermittent therapy was continued over the next 6 months with periodic nail debridement and monitoring of laboratory values. Significant improvement was seen with resolution of paronychia and slow regrowth of normal nail (Figure 4).

Discussion

Fusarium can cause a wide range of infections in humans including alimentary toxic aleukia (due to mycotoxin production), osteomyelitis, keratitis, brain abscess, and facial granuloma. Immunocompromised hosts, most commonly those with myeloproliferative disease, may have disseminated fusariosis. Cutaneous lesions appear in over 80% of cases of disseminated disease and include tender erythematous papules, nodules, or purpura.⁷ Nail infection may provide a portal of entry for often-lethal systemic disease during periods of neutropenia.

Characteristic histologic features including the presence of irregular hyaline hyphae and chlamydoconia may be helpful in rapid diagnosis and selection of appropriate antifungal therapy.

All strains of *Fusarium* have shown *in vitro* resistance to fluconazole and itraconazole. Significant activity has been shown by amphotericin B and terbinafine; natamycin and miconazole have also shown some activity. Ketoconazole has been found to be poorly active.^{11,12} *In vitro* sensitivity may not accurately predict *in vivo* response, since successful treatment of *Fusarium* onychomycosis with itraconazole, 200 mg daily for 6 to 12 weeks, or 200 mg twice daily for the first week of each month for 2 to 4 months, has been reported.^{7,13} Terbinafine at a dose of 250 mg daily for 3 months has also been used with good results.⁷ Nail avulsion followed by daily application of ciclopirox olamine nail lacquer or cream has led to clearance in a few cases.⁶ This is the first report of *Fusarium* nail infection responsive to fluconazole therapy.

REFERENCES

- Ramani R, Srinivas CR, Ramani A, *et al*: Molds in onychomycosis. *Int J Dermatol* 32: 877-878, 1993.
- Elewski BE, Charif MA, Daniel CR: Onychomycosis, In: Nails: Therapy-Diagnosis-Surgery (Scher RK, Daniel CR, eds), pp 151-162. Philadelphia, WB Saunders, 1997.
- DiSalvo AF, Fickling AM: A case of nondermatophytic toe onychomycosis caused by *Fusarium oxysporum*. *Arch Dermatol* 116: 699-700, 1980.
- Nelson PE, Dignani MC, Anaissie EJ: Taxonomy, biology, and clinical aspects of *Fusarium* species. *Clin Microbiol Rev* 7(4): 479-500, 1994.
- Arrese JE, Pierard-Franchimont C, Pierard GE: Fatal hyalohyphomycosis following *Fusarium* onychomycosis in an immunocompromised patient. *Am J Dermatopath* 18(2): 196-198, 1996.
- Baran R, Tosti A, Piraccini BM: Uncommon clinical patterns of *Fusarium* nail infection: report of three cases. *Br J Dermatol* 136: 424-427, 1997.
- Gianni C, Cerri A, Crosti C: Unusual clinical features of fingernail infection by *Fusarium oxysporum*. *Mycoses* 40: 455-459, 1997.
- Liu K, Howell DN, Perfect JR, *et al*: Morphologic criteria for the preliminary identification of *Fusarium*, *Paecilomyces*, and *Acremonium* species by histopathology. *Am J Clin Pathol* 109: 45-54, 1998.
- Hochman LG, Scher RK, Myerson MS, *et al*: The safety and efficacy of oral fluconazole in the treatment of onychomycosis. *J Geriatric Dermatol* 1: 169-172, 1993.
- Scher RK, Breneman D, Rich P, *et al*: Once-weekly fluconazole (150, 300, or 450 mg) in the treatment of distal subungual onychomycosis of the toenail. *J Am Acad Dermatol* 38 (6 pt. 2): S77-S86, 1998.
- Pujol I, Guarro J, Gene J, Sala J: *In-vitro* antifungal susceptibility of clinical and environmental *Fusarium* spp. strains. *J Antimicrob Chemother* 39: 163-167, 1997.
- Speeleveld E, Gordts B, Van Landuyt HW, *et al*: Susceptibility of clinical isolates of *Fusarium* to antifungal drugs. *Mycoses* 39: 37-40, 1996.
- De Doncker PR, Scher RK, Baran RL, *et al*: Itraconazole therapy is effective for pedal onychomycosis caused by some nondermatophyte molds and in mixed infection with dermatophytes and molds: a multicenter study with 36 patients. *J Am Acad Dermatol* 36: 173-177, 1997.