

A Newly Formulated Topical Triple-Antibiotic Ointment Minimizes Scarring

Richard S. Berger, MD, New Brunswick, New Jersey

Amy S. Pappert, MD, New Brunswick, New Jersey

Peter S. Van Zile, Pharm D, Morris Plains, New Jersey

Wes E. Cetnarowski, MD, Morris Plains, New Jersey

A randomized study of polymyxin B sulfate-bacitracin zinc-neomycin sulfate versus simple gauze-type dressings in dermabrasion wounds assessed the effects that each treatment had on scarring. Each of three uniform dermabrasion wounds created on the upper backs of 70 subjects was treated concurrently with a triple-antibiotic ointment (polymyxin B-bacitracin-neomycin), a double antibiotic (polymyxin B-bacitracin), or a simple, non-occlusive, gauze-type dressing, twice daily for up to 14 days. Pigmentary changes and textural changes (scarring) appearing after healing at the skin surface test sites were compared to adjacent normal skin at 45 and 90 days post-dermabrasion. These changes were graded visually utilizing fluorescent light, long-wave ultraviolet light, and by clinical color photography. The triple-antibiotic ointment was superior to simple gauze-type dressing alone in minimizing the scarring observed in dermabrasion wounds. The benefit of this new ointment was more pronounced in its effect on pigmentary changes.

Over the past 30 years, many investigators have demonstrated an influence of the local skin environment on the dynamics of wound healing. One of the important variables in epidermal wound healing is the presence of bacteria, where excessive bacterial growth in damaged skin can delay healing.¹ Topical antibiotic ointments have been

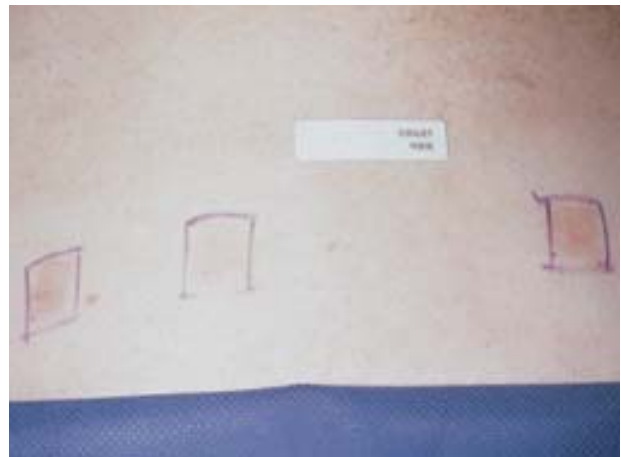


FIGURE 1. Global.

found to markedly reduce bacterial contamination and enhance wound healing, compared with no treatment.² Another variable that can influence wound healing is the degree of hydration of the skin during the healing process. Several investigators have shown that maintaining tissue hydration by the application of ointments and occlusive dressings increases epithelial migration and enhances skin re-epithelialization, thus, shortening the time necessary for wound repair.³⁻⁷

A topical triple-antibiotic ointment containing polymyxin B sulfate, bacitracin zinc, and neomycin sulfate has been available for many years as an over-the-counter preparation used to prevent infection in minor cuts, scrapes, and burns. Together, the ointment's antibiotic components provide a broad spectrum of antibacterial activity, while its occlusive petrolatum base maintains tissue hydration, an important variable in epidermal wound healing.

This controlled study was designed to evaluate whether a difference in scarring existed among test

Dr. Berger and Dr. Pappert are from Hill Top Research, Inc., East Brunswick, New Jersey, and the Robert Wood Johnson Medical School, University of Medicine and Dentistry of New Jersey, New Brunswick, New Jersey. Dr. Van Zile and Dr. Cetnarowski are from Warner-Lambert Company, Morris Plains, New Jersey. REPRINT REQUESTS to Warner-Lambert Company, 201 Tabor Road, Morris Plains, New Jersey 07950 (Dr. Van Zile).

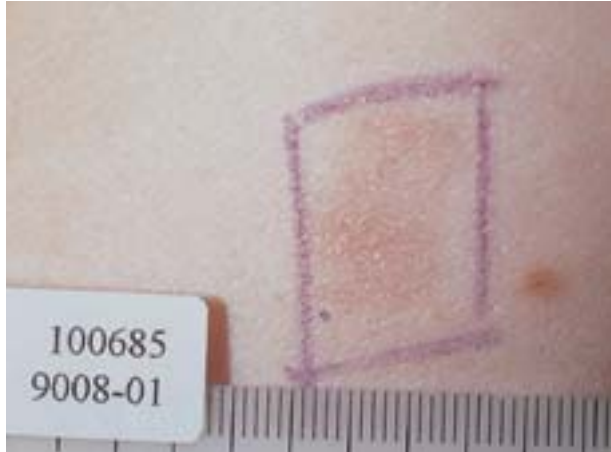


FIGURE 2. Gauze only.

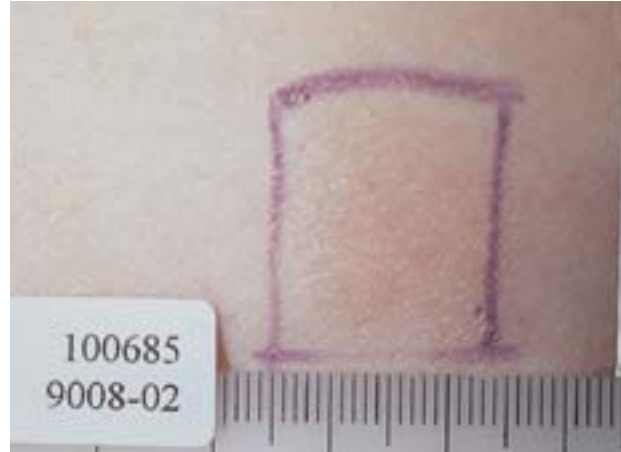

FIGURE 3. Triple antibiotic.

sites treated with one of the three study treatments. Visual evaluations at 45 and 90 days post-dermabrasion assessed pigmentary and textural changes, as compared to an area of adjacent, normal skin on the subject's own back. Clinical color photography was used to capture these changes, as well as to measure the areas of scarring.

The induced wound design and topical treatment regimens administered to the subjects in this controlled study approximated the current over-the-counter topical antibiotic indication for minor cuts and scrapes. In addition, the study design used here allowed for the evaluation of both epidermal wound healing and scar data, from the time of wound creation to scar resolution.

Materials and Methods

A single-center, randomized, evaluator-blind, parallel study was conducted to assess whether a difference existed in skin surface scarring (*ie*, in the severity and area of pigmentary and textural changes).

Trial Design—A clean dermabrasion model was chosen, which involved removal of the epidermis with some damage to the papillary dermis. This model was used in previous studies to evaluate the effects of agents on wound healing in healthy subjects because it was well suited to the treatment indication for minor cuts and abrasions.⁸

Volunteers were 18 years or older and in good general health. Individuals with a pre-existing disease or condition that could affect wound healing were excluded from the study.

On Study Day 0, subjects received three (2.5 × 2.5-cm) dermabrasion wounds on the upper back that were produced under anesthesia using a Robbins dermal abrader. Each of these wound sites was then ran-

domized to receive one of three treatments: 1) a newly formulated triple-antibiotic ointment (polymyxin B sulfate, bacitracin zinc, neomycin sulfate in vitamin E-sodium pyruvate-fatty acids petrolatum base); 2) a double antibiotic (polymyxin B sulfate-bacitracin zinc in vitamin E-sodium pyruvate-fatty acids petrolatum base); 3) or a simple, non-occlusive, gauze-type dressing. Each wound received an appropriate study treatment once after dermabrasion on Day 0. Subsequently, subjects returned to the testing facility for two applications daily, one in the morning and one in the evening, at approximately the same times each day. Treatments continued for each wound site until 100% re-epithelialization occurred or until the evening of Study Day 13, whichever was sooner. Any wounds not healed by Study Day 14 were treated according to the investigator's judgement; however, treatment with study medications was discontinued.

To maintain the blinding of the study, the treatments were applied by a technician, out of sight of the investigators. The evaluations of re-epithelialization of the wound sites, which began on Study Day 7, were conducted by a dermatologist, also out of sight of the investigator responsible for scarring evaluation.

Of 72 subjects who enrolled in the study, 66 subjects completed the study and were considered evaluable for efficacy. Two subjects withdrew consent, three experienced adverse events that required discontinuation, and one was lost to follow-up. The average age of the subjects was 41, while 96% (63 patients) were female and 85% (56 patients) were white.

Measurements of Efficacy—The pigmentary and textural changes (scarring) at the three test sites on each subject's back, as compared to the subject's normal skin adjacent to the test sites, were evaluated on Study Days 45 and 90 (±2 days). Long-wave UV ra-

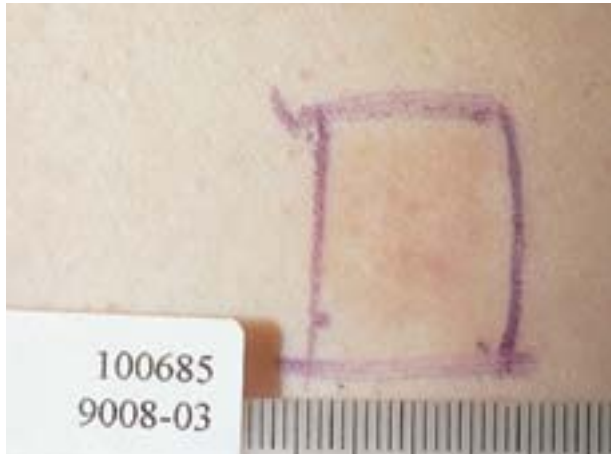


FIGURE 4. Double antibiotic.

diation from a Spectroline lamp was used by the blinded investigator to assess the severity and area of involvement of pigmentary changes observed in the test sites (*ie*, the presence of hypo- and/or hyperpigmented and the percentage of area covered by these changes for each test site). Similarly, using the Spectroline® lamp's white light source, severity and area of involvement of textural changes were also assessed. For either scale, a grade of 0 indicates that the test site appears equal in pigmentation and texture to adjacent, normal skin. Severity was graded on a 4-point scale (none, 1; mild, 2; moderate, 3; severe, 4), while area was based on a 5-point scale (none, 0; $\leq 25\%$, 1; $\leq 50\%$, 2; $\leq 75\%$, 3; $\leq 100\%$, 4).

A number of methods for scar assessment exist, but there are no absolute standards.^{9,10} Commonly, wounds and scars are evaluated by using a scale, either a visual analog scale or a composite based on several parameters. Since both measures, severity and area of involvement, contribute to the overall appearance of scars, a pigmentary composite score (PCS) and a textural composite score (TCS) were calculated for each test site (severity score \times the area of involvement = pigmentary or textural composite score). Clinical significance for the antibiotic ointments was defined as a minimum of 25% improvement in either composite score when compared to gauze-only treatment.

The investigator also ranked the three test sites in relation to one another for both pigmentary and textural changes from 1 (least severe in pigmentation/texture), to 3 (most severe in pigmentation/texture).

Finally, clinical color photography was used to record the results and determine the percentage area of scarring in each test site. One global and three individual photographic images (one for each test site) of each subject's back were taken on Study Days 45

and 90. The area of scarring was calculated by multiplying the longest-measured length by the longest-measured width. The area of the original dermabrasion wound was 6.25 cm². Percent scarring was then calculated using the formula:

$$\% \text{ involvement} = \frac{\text{area of scarring cm}^2}{6.25 \text{ cm}^2} \times 100$$

The primary efficacy variables were: 1) the PCS; and 2) TCS. Success was determined by achieving both statistical and clinical significance in either of the two composite scores. The secondary efficacy variables were: 1) overall ranking of pigmentary changes; 2) overall ranking of textural changes; and 3) percentage area of the test site exhibiting scarring. Sixty-six subjects were considered evaluable for efficacy.

Results

The mean pigmentary composite score on Day 45 for the triple-antibiotic ointment and the double-antibiotic ointment were not statistically significantly different from that of the gauze-only treatment. At 90 days, the triple-antibiotic ointment had a statistically significantly lower mean PCS (2.6) than that of gauze only (4.2) ($P < 0.001$). This difference was found to be clinically significant ($>25\%$ change), whereas the double-antibiotic ointment (3.7) was not different from that of gauze only.

The mean textural composite score at 45 days for the triple-antibiotic ointment and the double-antibiotic ointment were statistically ($P < 0.001$) and clinically significantly different from that of the gauze-only treatment. At 90 days, both the triple- and double-antibiotic ointments had a statistically significantly lower mean score than that of gauze only ($P < 0.001$), however, these differences were not clinically significant.

Both the pigmentary and textural ranking confirmed the superiority of the triple-antibiotic versus gauze-only at 90 days ($P < 0.001$). The double antibiotic was ranked statistically significantly better for textural changes at 90 days versus gauze-only treatment.

Percent area of scarring as determined through visual inspection of the photographic slides at 90 days was not found to be statistically significantly different for either treatment from gauze only. The photographic images presented here (Figures 1 to 4) are representative of the mean results of the study and demonstrate the average expected benefit.

To evaluate the efficacy within the triple-antibiotic ointment's indicated usage, efficacy analyses were also conducted for those subjects whose triple-antibiotic ointment wounds reached 100% re-epithe-

lialization before receipt of any study treatment on the morning of Study Day 8. Descriptive statistics were used for these analyses.

Forty-seven of 70 subjects demonstrated 100% re-epithelialization of their triple-antibiotic ointment wounds before receipt of any study treatment on the morning of Study Day 8. Within this efficacy subset, the triple-antibiotic ointment was judged to be better than gauze-only at all endpoints. These findings reflected the overall results.

Safety

None of the reported adverse events was considered serious and all reported adverse events resolved before subjects were released from the study. The most common adverse event was pain at the wound site(s). The subjects reporting site-specific pain (4.3%) were in the gauze-only treatment group. The most frequent reason for wound site withdrawal (discontinuation of treatment to one or more wound sites due to an adverse event) was contact dermatitis, which occurred more frequently in the two ointment groups (2.9%) versus the gauze-only group. The occurrence of contact dermatitis reactions was equal among the two ointment groups.

Conclusion

In conclusion, the newly formulated triple-antibiotic ointment appears to be safe and effective in minimizing the appearance of scars resulting from clean dermabrasion wounds. The triple-antibiotic ointment was significantly better at minimizing the appearance of scarring than simple gauze dressing alone. The benefit provided by the triple antibiotic was most pronounced in its effect on pigmentary changes.

Acknowledgment—We would like to thank the staff of Hill Top Research, Inc., particularly Christina Chaconas, Laurie Harnish, Joann Laino, John Lyssikatos, Blanca Smith, and Rita Wanser for all their efforts;

John Vine, MD, Robert Wood Johnson Medical School, University of Medicine and Dentistry of New Jersey, New Brunswick, New Jersey, for his review and comments; and Louis Tzagournis, MD, for his work in the preparation of this manuscript.

Product Information—Neosporin® Ointment, polymyxin B sulfate-bacitracin zinc-neomycin sulfate, Warner-Lambert Consumer Healthcare.

REFERENCES

1. Maibach HI, Rovee DT (eds): Epidermal Wound Healing, p 111. Chicago, Year Book Medical Publishers, Inc, 1972.
2. Leyden JJ, Bartlett NM: Comparison of topical antibiotic ointments as wound protectant, and antiseptics for the treatment of human blister wounds contaminated with *Staphylococcus aureus*. *J Fam Pract* 24: 601-604, 1987.
3. Odiand F, Rovee R: Human wound repair: epidermal regeneration. *J Cell Biol* 39: 135-151, 1968.
4. Him-nan CD, Maibach H: Effect of air exposure and occlusion on experimental human skin wounds. *Nature* 200: 377-378, 1963.
5. Ghadially R, Halkier-Sorensen L, Elias PM: Effects of petrolatum on stratum comeum structure and function. *J Am Acad Dermatol* 26: 387-396, 1992.
6. Winter GD, Scales JT: Effect of air drying and dressings on the surface of a wound. *Nature* 197: 91-92, 1963.
7. Rovee DT, Kurowsky CA, Labun J: Local wound environment and epidermal healing. *Arch Dermatol* 106: 330-334, 1972.
8. Cetnarowski W, Gabriel S: Comparison of two Neosporin ointment formulations on the time to healing of human dermabrasion wounds (Abstract). *Clin Pharmacol Ther* 63(2): 213, 1998.
9. Beausang E, Floyd H, Dunn KW, et al: A new quantitative scale for clinical scar assessment. *Plast Reconstr Surg* 102:1954-1961, 1998.
10. Quinn JV, Wells GA: An assessment of clinical wound scales. *Acad Emerg Med* 5: 583-586, 1998.