

A Case of a Hard Inguinal Nodule

Eyal K. Levit, MD, Philadelphia, Pennsylvania

Joseph Shaffer MD, MRCP, New York, New York

Peter C. Lombardo, MD, New York, New York

Daniel R. Foitl, MD, New York, New York

GOAL

To review the features of dermatofibrosarcoma protuberans (DFSP).

OBJECTIVES

Upon completion of this activity, dermatologists and general practitioners should be able to:

1. Describe the clinical appearance, locations, and differential diagnosis of DFSP.
2. Discuss the histologic characteristics of DFSP.
3. Review the treatment choices for DFSP.

CME Test on page 269.

This article has been peer reviewed and approved by Michael Fisher, MD, Professor of Medicine, Albert Einstein College of Medicine. Review date: September 2000.

This activity has been planned and implemented in accordance with the Essentials and Standards of the Accreditation Council for Continuing Medical Education through the joint sponsorship of Albert Einstein College of Medicine and Quadrant HealthCom, Inc. The Albert Einstein College of Medicine is accredited by the

ACCME to provide continuing medical education for physicians.

Albert Einstein College of Medicine designates this educational activity for a maximum of 1.0 hour in category 1 credit toward the AMA Physician's Recognition Award. Each physician should claim only those hours of credit that he/she actually spent in the educational activity.

This activity has been planned and produced in accordance with ACCME Essentials.

Dermatofibrosarcoma protuberans (DFSP) is an uncommon tumor with its onset typically in the second to fifth decades of life. It most commonly presents on the trunk, and recent cytogenetic studies suggest a neural origin. A case presentation and review of the recent literature on the diagnosis, differential diagnosis, and treatment of DFSP is presented.

Case Report

A 39-year-old white female presented with a complaint of a slowly growing inguinal nodule that

Dr. Levit is a Fellow in Mohs' Micrographic, Laser, and Dermatologic Surgery, University of Pennsylvania, Philadelphia. Dr. Shaffer is Chief Resident in the Department of Dermatology, St. Luke's-Roosevelt Hospital, Columbia University, New York, New York. Dr. Lombardo is Associate Clinical Professor in Dermatology and Dr. Foitl is Clinical Instructor of Dermatology, both at College of Physicians and Surgeons, Columbia University. REPRINT REQUESTS TO 1427 67th Street, 3rd Floor, Brooklyn, NY 11219 (Dr. Levit).

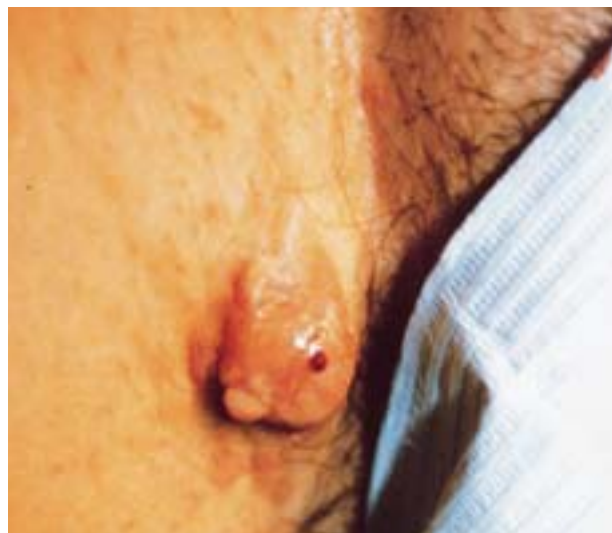

FIGURE 1. A 3-cm by 2.5-cm rock-hard, flesh-colored, dome-shaped, nontender, subcutaneous nodule in the right inguinal area.

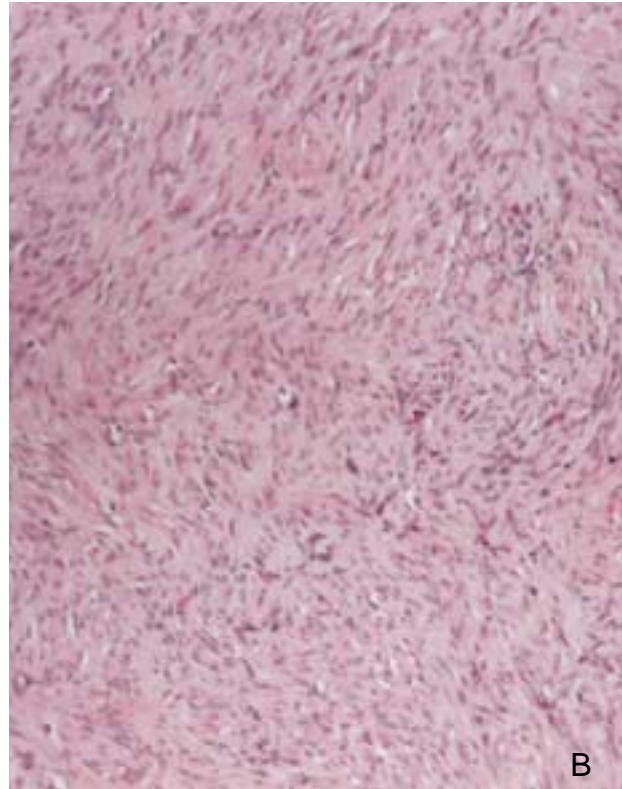
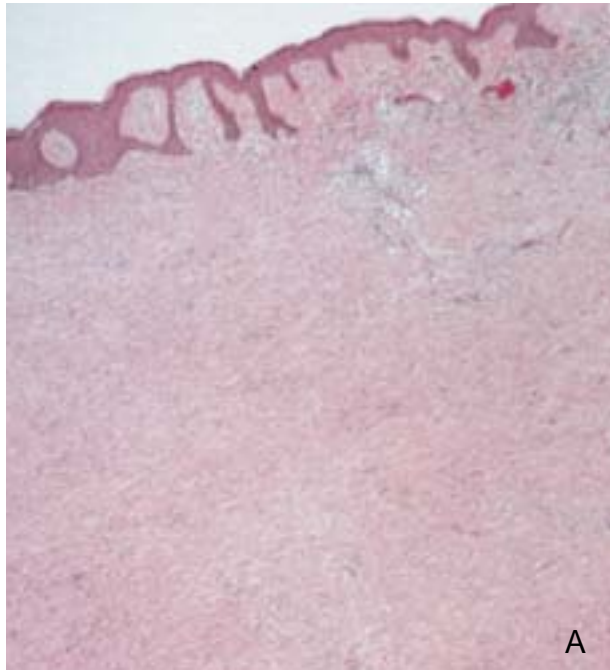


FIGURE 2. (A) Lower power magnification of the biopsy. Mesenchymal neoplasm showing storiform pattern. (B) A higher magnification, showing thin filiform cells with spindle-shaped nuclei in a storiform pattern.

developed 6 months previously. She denied pain, itching, or burning. She reported no antecedent trauma to the area. The patient was previously seen by her gynecologist and was told it was a wart.

She had no past medical history, took no medication, and had no allergies. Her family history is noncontributory.

On physical examination, a 3-cm by 2.5-cm rock-hard, flesh-colored, dome-shaped, nontender subcutaneous nodule was seen in the right inguinal area (Figure 1). The nodule appeared fixed to the overlying skin but mobile over the deep tissue.

An excisional biopsy was performed. Histopathology revealed an infiltrative mesenchymal neoplasm invading the fat with a lacelike array. The tumor was composed of numerous thin, filiform cells with little intervening collagen (Figure 2, A and B). Areas of the tumor showed a storiform pattern. Immunoperoxidase staining showed CD34 positive with very little staining for Factor XIIIa.

The patient was diagnosed with dermatofibrosarcoma protuberans (DFSP) and was referred for Mohs' micrographic surgery. A magnetic resonance image of the pelvis and groin was normal. The tumor was excised via the Mohs' technique requiring a 3 stage, 13 section procedure (Figure 3). The defect was then sent for repair to plastic surgery.

Comments

DFSP is uncommon, accounting for <0.1% of all malignancies.¹ Its incidence is 0.8/1x10⁶ patients per year.¹ Its behavior is noted for being locally aggressive² with a high rate of local recurrence. While reports vary, there appears to be equal frequency in males and females.^{3,4,5} However, blacks appear to have a higher incidence of this tumor than whites.^{6,7} The onset of this tumor ranges between birth and 80 years of age; the average being between the second and fifth decades of life. The tumor most commonly involves the trunk (>50%), followed by the proximal extremities (20%–30%) and the head and neck (~10%). Only a small amount of cases have been reported to occur on acral skin. Interestingly, in children, 15% of the tumors occur on the hands or feet, giving some weight to a possible association of this tumor with antecedent trauma.³ Morphologically, the tumor appears as an indurated plaque, red-brown, blue-red, or flesh in color. As the tumor grows, it may ulcerate, become lobulated, or painful. Areas of previous trauma, burns, or surgical scars² have a higher probability of developing DFSP within them. Bednar tumor is a histological variant of DFSP that, unlike DFSP, contains melanin.⁸ Recent evidence suggests neural origin of the tumor (chromosomes 17q & 22q, affected in NFI and NFII respectively, were found in cytogenetic studies of DFSP).^{9,10}

The differential diagnosis for DFSP includes both benign and malignant conditions (Table I). Histologically, DFSP appears as a well-differentiated fibrosarcoma.¹¹ It arises in the dermis with multiple interwoven fascicles of fibroblasts with spindle-shaped nuclei. The fascicles classically form a storiform pattern and replace the collagen and fat beneath it. The presence of CD34 and absence of factor XIIIa is typical on immunostaining of DFSP. In dermatofibroma, this pattern is reversed.¹²⁻¹⁵

Prognosis

Prognosis is determined in part by the presence of locally aggressive tentaclelike extensions that spread beneath clinically normal-looking skin. These often invade into subcutaneous fat, fascia, muscle, and bone. Bone erosion by the tumor, especially on the head, may result in death. The size of the clinically apparent tumor is not related to prognosis.² Of cases with local recurrence, 50% to 75% occurred within 3 years of surgery; rarely, recurrence may present after 10 years.¹⁶

When present, metastases are usually associated with multiple local recurrences. Regional lymph nodes are involved in approximately 1% of cases, and in approximately 4%, hematogenous spread may occur, predominantly to the lungs.⁴ Survival after metastatic disease ranges from 1 to 42 months with a mean of 14 months.²

Management

Studies have shown a total recurrence rate of 44% when standard surgical excision without complete histological examination of the margins is used (Table II).¹⁷ This total recurrence rate falls to 20% when a wide (>2cm) excision down to fascia is used. When Mohs' surgery is employed, recurrence falls further to 1.6%,² clearly showing that this is the treatment of choice. The principle reason for such high recurrence is the presence of clinically unrecognized and histologically easily overlooked projections of tumor deep into fascia and muscle. These projections are left behind with conservative surgery or missed on standard histological examination.

The benefit of skin conservation with Mohs' surgery has been demonstrated in DFSP. In a total of 38 Mohs patients, a

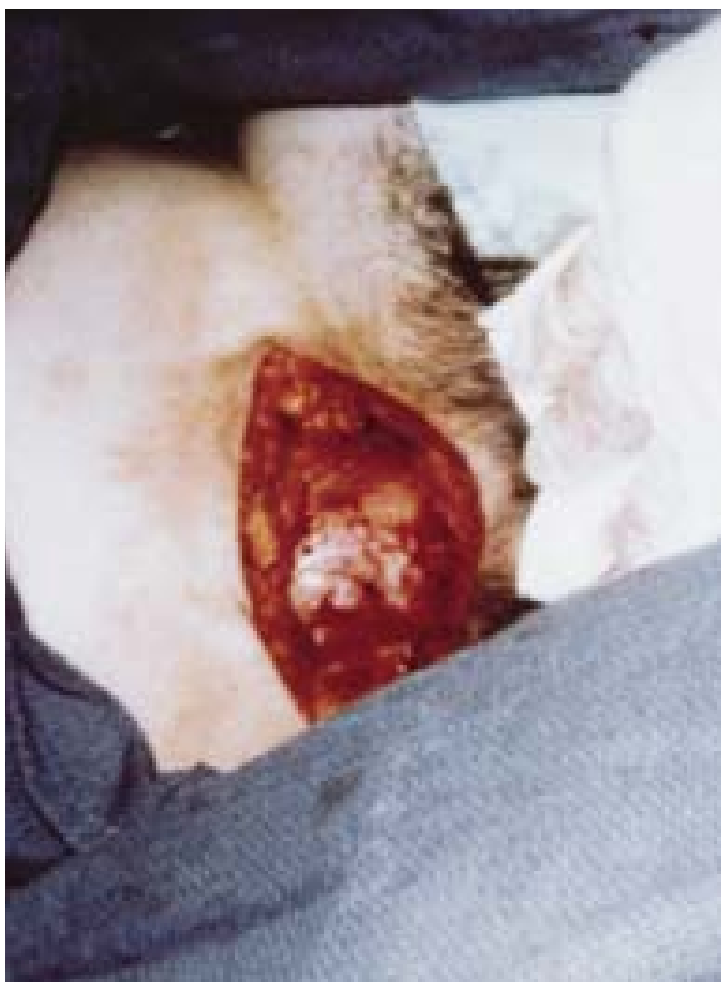

FIGURE 3. Mohs' micrographic surgery defect after 3 stage, 13 section procedure.

Table I.

Clinical Differential Diagnosis of DFSP

Benign	Malignant
1. Dermatofibroma	1. Cutaneous metastases
2. Syphilitic gumma	2. Desmoid tumor
3. Keloid	3. Fibrosarcoma
4. Lipoma	4. Lymphoma
5. Morphea	5. Malignant melanoma
6. Neurofibroma	6. Neurogenic sarcoma
7. Sarcoidosis	7. Sweat gland carcinoma
8. Sclerosing hemangioma	
9. Epidermoid cyst	

Table II.

Comparison of Surgical Modalities in the Treatment of DFSP¹⁷

Procedure	General Recurrence Mean and Range	No. of Patients	Follow-up Period
Surgery	20% (0%–60%)	489	1 mo–14 y
MMS	1.6% (0%–6.6%)	64*	3 mo–8 y
Surgery >4-cm margin	23%	13	1 y–7 y
MMS 1-cm margin	0%	15	3 mo–8 y

MMS indicates Mohs' micrographic surgery.

* The one patient with recurrence in that series underwent a second MMS without recurrence (3 years).

2.5-cm surgical margin would have been needed to fully remove the tumor if standard surgical excision had been used.^{17,18} Through skin conservation, Mohs allowed primary closure of the wounds in up to 88% of cases.¹⁹ Further benefit may be obtained by injections of hyaluronidase into the tumor before Mohs' surgery. A preliminary study suggested that reduced surgical margins were seen in 5 patients pretreated with hyaluronidase compared with standard Mohs' technique.²⁰

Several studies have looked at the role of radiation therapy in DFSP. They include patients treated with radiation alone and those combined with surgery. Using electron beam and brachytherapy, Suit et al produced clinically local control in 3 patients, 1 with primary disease and 2 with local recurrence, at up to 10 years.^{21,22} Haas et al looked retrospectively at 38 patients to try to compare surgical therapy alone with radiation and surgery.²³ Local control with surgery alone was 67%, while for radiation it was 82%. These results, however, were not statistically significant, a fact they attribute to the small numbers in the study. Ballo et al²⁴ had a single patient treated with radiation therapy alone who failed to achieve local control.

Interestingly these studies come from nondermatological departments that continue to describe wide local excision (>3 cm margin) as the best means of therapy, even though they cite evidence that Mohs' surgery has better local control. Indeed many of the patients in these studies received radiation precisely because the standard surgical margins were positive for tumor, a feature that could be eliminated or greatly reduced by Mohs' technique. Adjuvant radiation after Mohs' excision has not been studied. Reports of the few patients described with radiation as sole therapy do suggest that, when no other option exists, it

can be used as the sole treatment modality. However, the role of radiation in DFSP still has yet to be clarified. Only case reports exist of chemotherapy use in metastatic DFSP; there are no definitive studies. Chemotherapy has no role in local control.²

REFERENCES

1. Bendix-Hansen K, Myhre-Jensen D, Haae S. Dermatofibrosarcoma protuberans: a clinico-pathological study of nineteen cases and review of the world literature. *Scand J Plast Reconstr Surg Hand Surg*. 1983;17:247-252.
2. Gloster HM Jr. Dermatofibrosarcoma protuberans. *J Am Acad Dermatol*. 1996;35:355-374.
3. Taylor HB, Helwig EB. Dermatofibrosarcoma protuberans: a study of 115 cases. *Cancer*. 1962;15:717-725.
4. Rutgers EJ, Kroon BR, Albus-Lutter CE, et al. Dermatofibrosarcoma protuberans: treatment and prognosis. *Eur J Surg Oncol*. 1992;18:241-248.
5. Burkhardt BR, Soule EH, Winkleman RK, et al. Dermatofibrosarcoma protuberans: study of fifty-six cases. *Am J Surg*. 1966;111:638-644.
6. Halder RM, Bang KM. Skin Cancer in blacks in the United States. *Dermatol Clin*. 1986;6:397-405.
7. Garg SK, Subbuswamy SG, Alabi JO, et al. Dermatofibrosarcoma protuberans in Northern Algeria: a clinical pathological review of 17 cases. *Clin Oncol*. 1978;4:113-122.
8. Dupree WB, Langloss JW, Weiss SW. Pigmented dermatofibrosarcoma protuberans (Bednar tumor): a pathologic, ultrastructural and immunohistochemical study. *Am J Surg Pathol*. 1985;9:630-639.
9. Pedebour F, Simon MP, Minoletti F, et al. Translocation (17;22)(q22;q13) in dermatofibrosarcoma protuberans: a new tumor-associated chromosome rearrangement. *Cytogen Cell Genet*. 1996;72:171-174.
10. Dobin SM, Diaz JA, Silva MT, et al. Translocation (17;22)(q22;q13) in a case of subcutaneous dermatofi-

- bro sarcoma protuberans in an adult. *Cancer Genet Cytogenet*. 1999;109:86-87.
11. Mopper C, Pinkus H. Dermatofibrosarcoma protuberans: report of two cases. *Am J Clin Pathol*. 1950;20:171-176.
 12. Haycox CL, Odland PB, Olbricht SM, et al. Immunohistochemical characterization of dermatofibrosarcoma protuberans with practical applications for diagnosis and treatment. *J Am Acad Dermatol*. 1997;37:438-444.
 13. Cohen PR, Rapini RP, Farhood AI. Dermatofibroma and dermatofibrosarcoma protuberans: differential expression of CD34 and Factor XIIIa. *Am J Dermatopathol*. 1994;16:573-574.
 14. Altman DA, Nickoloff BJ, Fivenson DP. Differential expression of factor XIIIa and CD34 in cutaneous mesenchymal tumors. *J Cut Pathol*. 1993;20:154-158.
 15. Abenoza P, Lillemoe T. CD34 and factor XIIIa in the differential diagnosis of dermatofibroma and dermatofibrosarcoma protuberans. *Am J Pathol*. 1993;15:429-434.
 16. Mark RJ, Bailet JW, Tran LM, et al. Dermatofibrosarcoma protuberans of the head and neck: a report of 16 cases. *Arch Otolaryngol Head Neck Surg*. 1993;119:891-896.
 17. Gloster HM Jr, Harris KR, Roenigk RK. A comparison between Mohs micrographic surgery and wide surgical excision for the treatment of dermatofibrosarcoma protuberans. *J Am Acad Dermatol*. 1996;35:82-87.
 18. Parker TL, Zitelli JA. Surgical margins for excision of dermatofibrosarcoma protuberans. *J Am Acad Dermatol*. 1995;32:233-236.
 19. Mikhail GR, Lynn BH. Dermatofibrosarcoma protuberans. *J Dermatol Surg Oncol*. 1978;4:81-84.
 20. Menon P, Smith KJ, Crittenden J, et al. Adjuvant therapy with hyaluronidase prior to excision of dermatofibrosarcoma protuberans. *Dermatol Surg*. 1999;25:205-209.
 21. Suit H, Spiro I, Mankin HJ, et al. Radiation in management of patients with dermatofibrosarcoma protuberans. *J Clin Oncol*. 1996;14:2365-2369.
 22. Marks LB, Suit HD, Phil D, et al. Dermatofibroma protuberans treated with radiation therapy. *Int J Radiation Oncology Biol Phys*. 1989;17:379-384.
 23. Haas RL, Keus RB, Loftus BM, et al. The role of radiotherapy in the local management of dermatofibrosarcoma protuberans. *Eur J Cancer*. 1997;33:1055-1060.
 24. Ballo MT, Zagars GK, Pisters P, et al. The role of radiation therapy in the management of dermatofibrosarcoma protuberans. *J Radiation Oncology Biol Phys*. 1998;40:823-827.

DISCLAIMER

The opinions expressed herein are those of the authors and do not necessarily represent the views of the sponsor or its publisher. Please review complete prescribing information of specific drugs or combination of drugs, including indications, contraindications, warnings, and adverse effects before administering pharmacologic therapy to patients.

FACULTY DISCLOSURE

The Faculty Disclosure Policy of the College of Medicine requires that faculty participating in a CME activity disclose to the audience any relationship with a pharmaceutical or equipment company that might pose a potential, apparent, or real conflict of interest with regard to their contribution to the program. Drs. Levit, Shaffer, Lombardo, and Foittl report no conflict of interest. Dr. Fisher reports no conflict of interest.