

Testicular Choriocarcinoma Metastatic to the Skin: An Additional Case and Literature Review

Lily L. Tinkle, MD, PhD, Irvine, California

LCDR Brad S. Graham, MC, USNR, Irvine, California

Thomas J. Spillane, MD, Irvine, California

Ronald J. Barr, MD, Irvine, California

Choriocarcinoma, a malignancy of trophoblastic cells, is characterized by the secretion of human chorionic gonadotropin (hCG). Choriocarcinoma primarily arises from the fetal (placental) trophoblasts in the setting of a molar pregnancy. Nongestational choriocarcinoma from the ovary or testis is much rarer. Testicular choriocarcinoma is a malignant tumor with great propensity for distant metastasis. The primary sites of metastasis are the lungs, liver, and brain. Skin metastasis is very rare but portends a grave prognosis when diagnosed. We present the case of a 24-year-old white male with a testicular mixed germ-cell tumor with skin metastases of choriocarcinoma.

Choriocarcinoma is a malignant tumor of trophoblastic cells. Most commonly, choriocarcinoma arises from fetal trophoblasts of a hydatidiform mole or true pregnancy, which is known as gestational choriocarcinoma.¹ Choriocarcinoma is characterized by the secretion of human chorionic gonadotropin (hCG) from syncytiotrophoblastic cells. Origin from the testis, ovary, or ectopic cell rests is uncommon. In males, choriocarcinoma arises primarily as a component of testicular mixed germ-cell tumors or seminomas; it often metastasizes hematogenously to the lungs, liver, gastrointestinal tract, brain,

spleen, and adrenal glands.² Skin metastases are uncommon. To the best of our knowledge, only 14 cases have been reported in the literature since 1974, 6 of which had skin metastases of testicular origin.¹⁻⁵ Skin metastases in nongestational choriocarcinoma coincide with visceral metastases and portend a poor prognosis despite aggressive chemotherapy or surgical intervention.¹ A rare case of metastatic testicular choriocarcinoma to the skin and viscera is presented.

Case Report

A 24-year-old white male was admitted to our medical center for the treatment of an enlarged left testicular mass. Although the tumor had been present for 10 months, the patient had refused to seek medical treatment until just 2 weeks before hospital admission, when he presented with complaints of fever, right frontal headache, lower back pain, intermittent paresthesias of the extremities, hemoptysis, as well as the testicular growth. Physical examination at admission revealed a 15-cm nontender, solid, left testicular mass with no significant inguinal lymphadenopathy. Lung examination revealed left-sided pulmonary rales with decreased breath sounds at the base. Spiral computed tomography (CT) scan of the body found extensive lymphadenopathy that included enlarged supraclavicular, axillary, anterior mediastinum, prevascular, and left periaortic lymph nodes. Multiple metastases were also identified in the lung and liver. Magnetic resonance imaging (MRI) of the brain revealed 6 focal areas consistent with hemorrhagic metastases. Significant surrounding edema was present without midline shift or acute hemorrhage.

Tumor markers were drawn from admission laboratory testing, and showed an elevated β -hCG level of 856,208 mIU/mL (normal, 0 mIU/mL), α -fetoprotein (AFP) level of 81.7 ng/mL (normal

Drs. Tinkle, Graham, Spillane, and Barr are from the University of California at Irvine. Drs. Tinkle, Graham, and Barr are from the Department of Dermatology and the Dermatopathology Laboratory. Dr. Spillane is from the Division of Hematology/Oncology.

The views expressed herein are those of the authors and do not necessarily reflect the views, official policy, or position of the US Navy, the Department of Defense, or the US Government.

Reprints: Ronald J. Barr, MD, University of California, Irvine Medical Center, Dermatopathology Laboratory, Rte 98, 101 The City Dr, Orange, CA 92868.

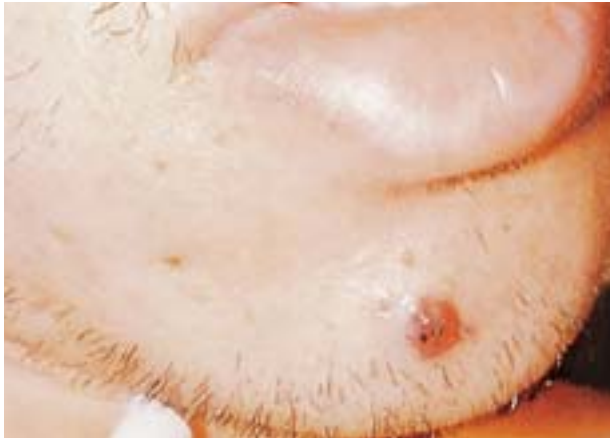

Figure 1. Violaceous-to-hemorrhagic, firm, dome-shaped papule with focal necrosis on the right side of the chin.

range, 0–5.5 ng/mL), and lactate dehydrogenase (LDH) level of 1335 U/L (normal range, 91–180 U/L). Liver enzymes were within normal limits. Radical orchiectomy was performed to obtain a tissue diagnosis, results of which revealed a mixed germ-cell tumor consisting of 90% seminoma, 5% embryonal carcinoma, and 5% choriocarcinoma. Extensive necrosis and hemorrhage were present, especially in the areas of choriocarcinoma. Involvement of the vascular and lymphatic spaces was noted, as was invasion into the tunica albuginea of the testis.

The patient was started on intravenous dexamethasone to reduce cerebral edema. Daily palliative radiation of the whole brain was begun on the third day of hospitalization. The patient also received the first dose of a course of chemotherapy consisting of cisplatin and etoposide. On the fifth day, along with increasing headache, the patient developed a dense left hemiplegia. A CT scan of the brain revealed acute hemorrhage of the right frontal lobe with accompanying midline shift and compression of the right lateral ventricle.

Seven days after admission, dermatology was consulted for the appearance of skin lesions on the face and scalp. Skin examination revealed 3 isolated nodules. The right chin lesion was a 1.0×9-cm nontender, violaceous-to-hemorrhagic, firm, dome-shaped papule (Figure 1). The right mandibular area had a 1.0×1.0×0.6-cm translucent bright red vascular nodule similar to a pyogenic granuloma. In addition, a large erythematous and hemorrhagic, crusted, indurated nodule measuring 1.8×2.0×0.7 cm was located on the vertex of the scalp.

Clinical deterioration continued rapidly over the next 2 days, and the patient developed gastrointestinal bleeding, seizures, and progressive obtundation. He died on hospital day 9 due to hemorrhagic sequelae secondary to cerebral tumor metastases.

Histopathologic examination of the skin biopsy from the right mandibular area showed replacement of the entire dermis with islands and cords of neoplastic cells (Figure 2). Two cell types were present: solid masses of polygonal cells with distinct cell borders consistent with cytotrophoblasts and large multinucleated pleomorphic cells with marked atypia consistent with syncytiotrophoblasts (Figures 2 and 3). The syncytiotrophoblasts surrounded solid masses of cytotrophoblasts in several areas. Large areas of hemorrhage and necrosis were present throughout the tumor; epidermal necrosis and ulceration were noted focally. Several clusters of cytotrophoblasts and syncytiotrophoblasts were detached and “floating” in areas of extensive hemorrhage. Immunohistochemical staining with β -hCG using the avidin-biotin complex technique strongly labeled the cytoplasm of the syncytiotrophoblasts with weaker staining of the cytotrophoblasts, confirming the diagnosis of metastatic choriocarcinoma (Figure 4). The AFP stain was negative. Cytokeratins strongly labeled the syncytiotrophoblasts; the cytotrophoblasts showed only focal staining.

Comment

Choriocarcinoma is a highly malignant germ-cell tumor composed of 2 cell types: cytotrophoblasts and syncytiotrophoblasts, which secrete hCG. The origin of choriocarcinoma varies based on gender. In women, choriocarcinoma usually presents following a gravid state, arising from fetal trophoblasts.² It is estimated that 40% to 50% of choriocarcinomas stem from hydatidiform moles, 25% to 30% from prior abortions, and 20% follow a normal pregnancy and delivery.⁶ Rarely, choriocarcinoma may arise from an ovarian mixed germ-cell tumor or teratoma.⁷ Gestational choriocarcinoma occurring simultaneously in mother and child has been infrequently reported.⁷ In men, choriocarcinoma usually arises as a component of a testicular mixed germ-cell tumor and occurs almost exclusively in the second or third decade of life.

Testicular mixed germ-cell tumors are common, comprising almost one third of all testicular tumors.⁸ Because the germ cells in the testis are totipotent, they may undergo either trophoblastic or somatic differentiation. Thus, in any primary testicular tumor or its metastases, areas of choriocarcinoma, seminoma, embryonal carcinoma, yolk sac tumor, or teratoma may be observed.³ Choriocarcinoma is the most aggressive component, with high metastatic potential. Up to 40% of testicular neoplasms contain elements of choriocarcinoma.⁴ Pure choriocarcinoma of the testis is very rare, accounting for less than 3% of all testicular tumors.⁵ Clinical findings vary depending

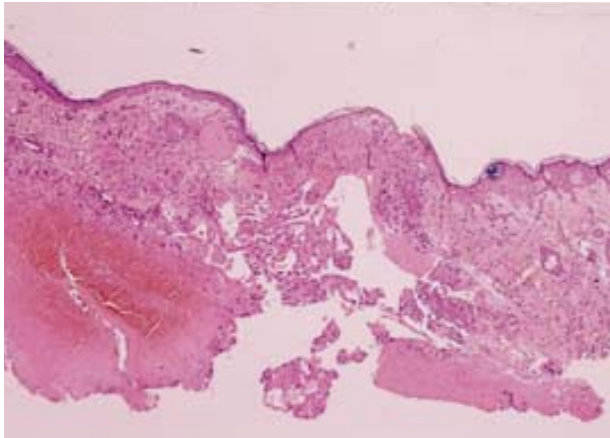


Figure 2. Photomicrograph of the right mandibular area shows extensive hemorrhage, epidermal necrosis, and replacement of the dermis with islands and cords of neoplastic cells (H&E, original magnification $\times 40$).

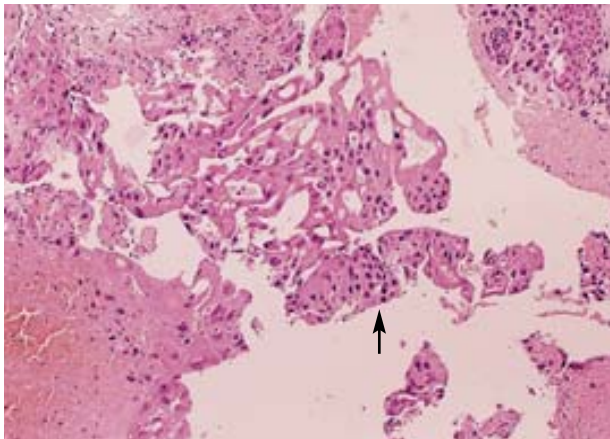


Figure 3. High magnification photomicrograph shows hemorrhage, necrosis, and 2 neoplastic cell populations: syncytiotrophoblasts and cytotrophoblasts. Arrow indicates the smaller eosinophilic cuboidal cytotrophoblasts (H&E, original magnification $\times 100$).

on whether the choriocarcinoma originates from a mixed germ-cell tumor or whether it exists as a pure testicular choriocarcinoma. In pure choriocarcinoma, metastatic disease may be the presenting symptom, as the testis is frequently normal or only slightly enlarged with little or no pain.² Choriocarcinoma arising from mixed germ-cell tumors, however, usually presents with testicular enlargement and pain in addition to metastatic symptoms. Choriocarcinoma has a distinct propensity for early hematogenous spread to distant sites. The most frequent sites of metastases are the lungs, liver, brain, gastrointestinal tract, spleen, and adrenal glands.² The lungs are involved in virtually 100% of cases with metastasis; liver in 86%; gastrointestinal tract in 71%; and brain, spleen, or adrenal glands in 56% of reported cases.³

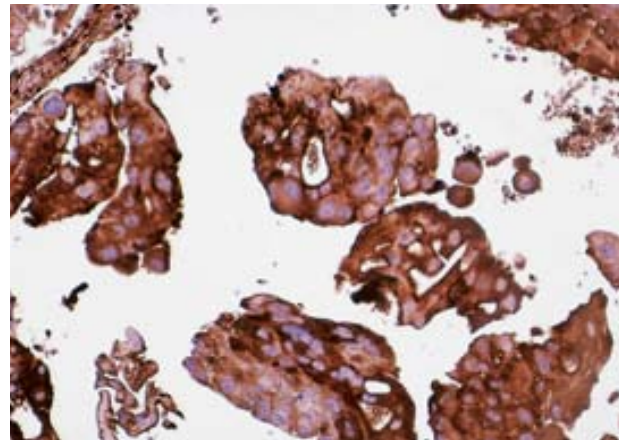


Figure 4. Immunohistochemical stain with human chorionic gonadotropin strongly labels the syncytiotrophoblasts, with weaker staining of the cytotrophoblasts (β -hCG, original magnification $\times 400$).

Periaortic and iliac lymph nodes also are frequently involved with metastatic disease.

Cutaneous metastasis of choriocarcinoma is rare. In an autopsy study of choriocarcinoma, Park and Lees⁹ found that only 4 of 123 patients had cutaneous metastases.⁹ Overall, 14 cases of skin metastases have been reported since 1974.^{1-7,10-15} Only 6 of those patients had metastatic choriocarcinoma of testicular origin.¹⁻⁵ The other 8 cases were gestational choriocarcinoma.^{6,7,11-15} Solitary cutaneous metastasis was reported in 10 patients^{1,3,4,6,10-14} and multiple lesions in 4 additional cases.^{2,5,7,15} Skin metastasis was the presenting symptom in 6 of these cases.^{1,2,6,10-12} Skin metastases usually present as hemorrhagic nodules, red papules simulating hemangiomas, or as asymptomatic subcutaneous nodules.⁵ Locations of metastases have included scalp, trunk, nose, lower extremities, buttocks, neck, gingiva, and nail bed.^{3-5,10-15} Skin metastases from choriocarcinoma usually coincide with widespread visceral metastases.

On histopathologic examination, the skin metastases show a biphasic cellular pattern of syncytiotrophoblasts and cytotrophoblasts arranged in cords and islands associated with variable amounts of hemorrhage and necrosis. The cytotrophoblasts are polygonal cells with clear cytoplasm and large irregular nuclei and prominent nucleoli, which tend to be arranged in sheets and nests. Syncytiotrophoblasts are large multinucleated cells with pleomorphic nuclei and abundant eosinophilic cytoplasm. The syncytiotrophoblasts characteristically surround the nests of cytotrophoblasts, forming a syncytium. Diagnosis of choriocarcinoma requires the presence of both syncytiotrophoblasts and cytotrophoblasts. Immunohistochemical staining for β -hCG, which labels the syncytiotrophoblasts, confirms the diagnosis.

TESTICULAR CHORIOCARCINOMA

Serum and urinary levels of β -hCG are invariably elevated in metastatic choriocarcinoma (extremely high in most cases) and tend to correlate with the amount of viable tumor. Choriocarcinoma is a highly aggressive neoplasm with approximately 70% of patients having metastatic disease at the time of diagnosis.² Skin metastases, although uncommon, tend to portend a worse prognosis. Standard treatment has been orchiectomy and chemotherapy. Postorchiectomy radiation therapy has not been shown to affect survival. The current therapy involves aggressive combination chemotherapy. Response to chemotherapy is indicated by a decrease in tumor volume and falling β -hCG levels. Persistence of elevated β -hCG levels signals residual tumor and a worse prognosis.¹ Previously, patients with widespread metastatic disease had a 2-year mortality rate of 75%; currently, with aggressive therapy, the cure rate approaches 75%.² Unfortunately, in many cases, death occurs despite chemotherapy, as in our patient, from complications due to the mass effects of rapid growth and/or from hemorrhage secondary to the metastases.

In summary, choriocarcinoma arising from a testicular tumor should be included in the differential diagnosis of cutaneous metastatic malignancies, especially in a male in the second to third decades with visceral metastases and hemorrhagic or hemangioma-like cutaneous lesions.

REFERENCES

1. Requena L, Sanchez M, Aguilar A, et al. Choriocarcinoma of the testis metastatic to the skin. *J Dermatol Surg Oncol*. 1991;17:466-470.
2. Chhieng DC, Jennings TA, Slominski A, et al. Choriocarcinoma presenting as a cutaneous metastasis. *J Cutan Pathol*. 1995;22:374-377.
3. Nespeca JA, Sass JK. Choriocarcinoma metastatic to maxillary gingiva. *J Oral Surg*. 1980;38:534-537.
4. Winter CC, Trepashko DW. Rare solitary metastasis to subcutaneous tissue from choriocarcinoma of the testis. *Urology*. 1989;33:320-321.
5. Shimizu S, Nagata Y, Han-yaku H. Metastatic testicular choriocarcinoma of the skin: report and review of the literature. *Am J Dermatopathol*. 1996;18:633-636.
6. Cosnow I, Fretzin DF. Choriocarcinoma metastatic to skin. *Arch Dermatol*. 1974;109:551-553.
7. Avril MF, Mathieu A, Kalifa C, et al. Infantile choriocarcinoma with cutaneous tumors: an additional case and review of the literature. *J Am Acad Dermatol*. 1986;14:918-927.
8. Ulbright TM. Germ cell neoplasms of the testis. *Am J Surg Pathol*. 1993;17:1075-1091.
9. Park WW, Lees GC. Choriocarcinoma. *Arch Pathol*. 1950;49:205-209.
10. Sugano I, Nagao K, Kondo Y, et al. Primary nongestational choriocarcinoma of submental region. *Acta Pathol Jpn*. 1984;34:895-900.
11. Balat O, Verschraegen CF, Edwards CL, et al. Unusual presentation of a metastatic choriocarcinoma following a full term pregnancy: a case report. *Eur J Gynaecol Oncol*. 1996;17:271-273.
12. Mukherjee DK. Choriocarcinoma of the nose. *Ann Otol Rhinol Laryngol*. 1978;87:257-259.
13. Ertüngenalp E, Axelrod J, Stanek A. Skin metastasis from malignant gestational trophoblastic disease: report of two cases. *Am J Obstet Gynecol*. 1982;143:843-846.
14. Seoud M, Kaspar H, Khalil A, et al. Subungual metastatic choriocarcinoma. *J Am Acad Dermatol*. 1996;34:511-512.
15. Raziq F, Khan MT. Choriocarcinoma metastatic to skin. *J Pak Med Assoc*. 1987;37:183-184.