

# Symmetrically Distributed Orange Eruption on the Ears: A Case of Lupus Vulgaris

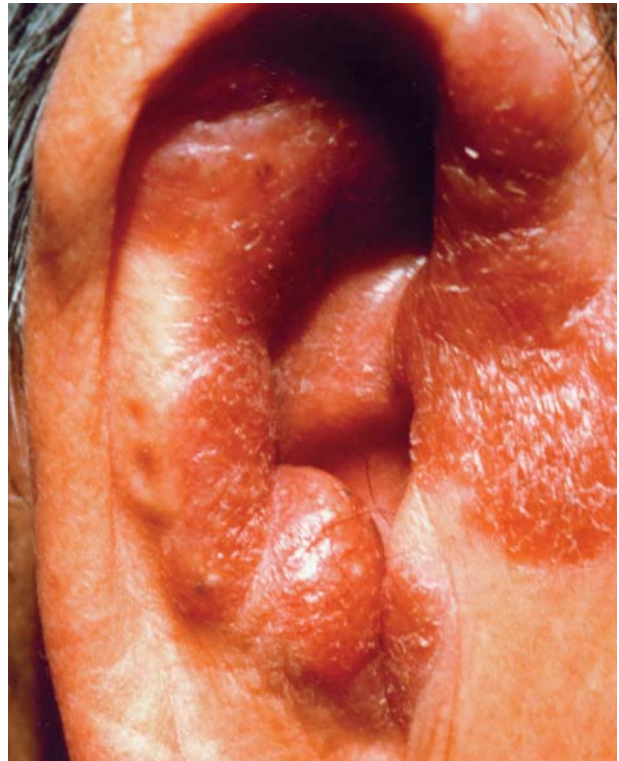Carmen D. Campanelli, BS, Wilmington, Delaware  
Anthony F. Santoro, MD, Philadelphia, Pennsylvania  
Cynthia G. Webster, MD, Hockessin, Delaware  
Jason B. Lee, MD, New York, New York

*Although the incidence and morbidity of tuberculosis (TB) have declined in the latter half of the last decade in the United States, the number of cases of TB (especially cutaneous TB) among those born outside of the United States has increased. This discrepancy can be explained, in part, by the fact that cutaneous TB can have a long latency period in those individuals with a high degree of immunity against the organism. In this report, we describe an individual from a region where there is a relatively high prevalence of tuberculosis who developed lupus vulgaris of the ears many years after arrival to the United States.*

Cutaneous tuberculosis (TB) is a rare manifestation of *Mycobacterium tuberculosis* infection. Scrofuloderma, TB verrucosa cutis, and lupus vulgaris (LV) comprise most of the cases of cutaneous TB. All 3 are rarely encountered in the United States. During the last several years, the incidence of TB has declined in the United States, but the incidence of these 3 types of cutaneous TB has increased in foreign-born individuals. This discrepancy can be explained, in part, by the fact that TB can have a long latency period, especially in those individuals with a high degree of immunity against the organism. Individuals from regions where there is a high prevalence of TB may develop cutaneous TB many years after arrival to the United States, despite screening protocol when they enter the United States. This case of LV in an older adult man illustrates this trend.

---

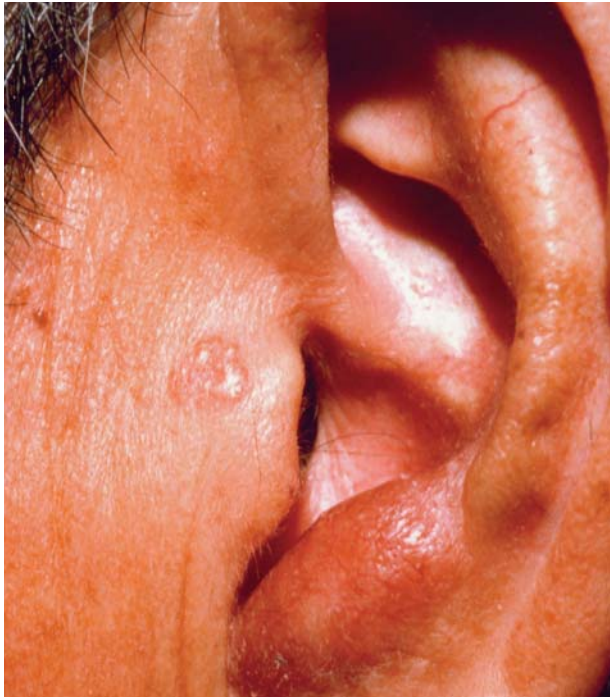Ms. Campanelli and Drs. Santoro and Webster are from Jefferson Medical College, Thomas Jefferson University, Wilmington, Delaware. Dr. Lee is from the Ackerman Academy of Dermatopathology, New York, New York.  
Reprints: Jason B. Lee, MD, 145 E 32nd St, 10th Floor, New York, NY 10016.



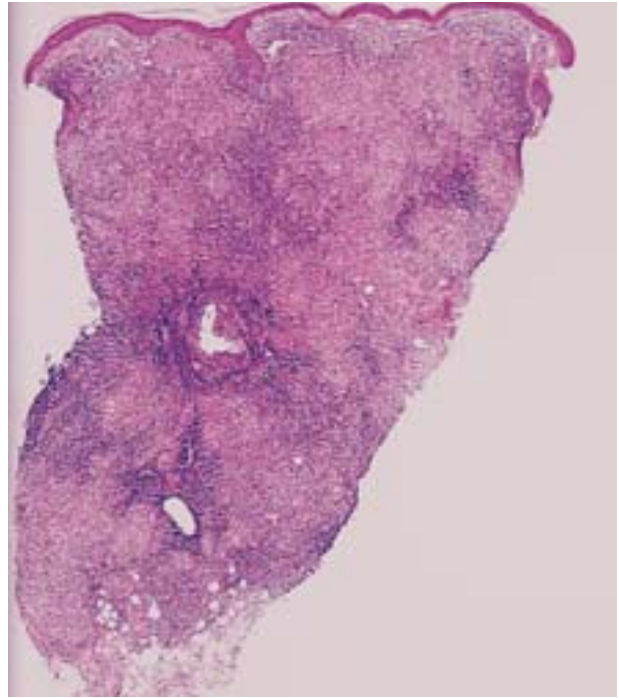
**Figure 1.** Orange plaques and nodules on the right ear.

## Case Report

A 71-year-old man from the Philippines presented with an eruption on both ears that had existed for one year. He reported that the condition was asymptomatic except for mild occasional pruritus. His medical history was significant for diabetes mellitus, hypertension, and heart disease, for which he was on coumarin, nifedipine, and tolbutamide. Physical examination revealed orange nodules and plaques on the right ear, involving the crura of helix, antihelix, and antitragus (Figure 1). A similar nodule was present on the antitragus of the left ear with central



**Figure 2.** A nodule on the antitragus and a smaller papule on the preauricular region of the left ear.



**Figure 3.** Dense diffuse nodular granulomatous inflammation spanning the entire dermis (H&E, original magnification  $\times 50$ ).

telangiectases and atrophy (Figure 2). No lymph nodes were palpable.

A punch biopsy from the right ear revealed a dense diffuse nodular granulomatous inflammation spanning the entire dermis (Figure 3). A dense infiltrate of lymphocytes surrounded the granulomas in multiple foci (Figure 4). Atrophic epidermis and ectatic vessels in the superficial dermis were also noted. Caseous necrosis was absent. Periodic acid-Schiff and Fite's stains revealed no organisms. A chest x-ray was within normal limits as were routine laboratory studies (complete blood count, chemistry panel, nonreactive rapid plasma reagin test, calcium and angiotensin-converting enzyme levels, and urinalysis). A tissue culture confirmed the diagnosis of LV. The patient was treated with isoniazid (INH), 300 mg/d; pyrazinamide, 2 g/d; and rifampin, 600 mg/d for 2 months. INH and rifampin were then continued in the same dosages for another 4 months. The patient tolerated the treatment well and had resolution of the lesions within 6 months. Two years after treatment, there was no evidence of recurring infection.

### Comment

TB continues to remain an important public health problem. The World Health Organization estimates that one third of the world's population is infected with *M tuberculosis*. Five percent to 10% of these

people will become sick or infectious sometime during their lives, killing 2 million per year.<sup>1</sup> In developed countries the incidence is considerably less. The United States, in 1999, reported 17,528 or 6.4/100,000 cases.<sup>2</sup> Cutaneous TB is considerable less prevalent, occurring in 4.4% of reported TB cases in one study.<sup>3</sup> The different forms include scrofuloderma, TB verrucosa cutis, and LV. Approximately 40% of the cutaneous TB are cases of LV.<sup>4,5</sup>

LV is a progressive form of cutaneous TB that occurs in individuals with a moderate to high degree of immunity, usually in patients previously infected elsewhere (primarily the lung).<sup>6</sup> Contiguous, lymphatic, or hematogenous spread from a tuberculous focus elsewhere is the usual mode in which LV develops. Concomitant active infection elsewhere can be demonstrated in only 10% to 30% of the cases, and approximately only one half of the cases have history of past infection.<sup>7-10</sup> Often, the focus of infection is not clinically apparent, as was the case in this patient. Because both ears were involved in this patient, hematogenous spread from an unknown source of infection, most likely the lung, was presumed. Rarely, LV develops as a result of primary inoculation.

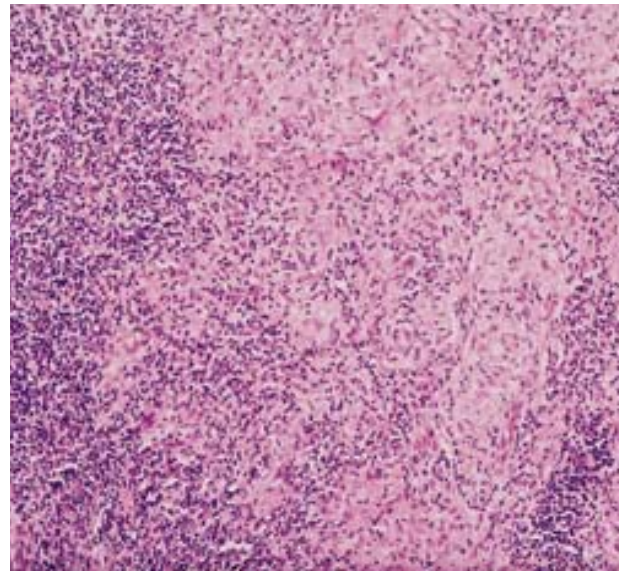
The most common sites of involvement are reported to be the face and neck,<sup>4,7,11,12</sup> especially on sites such as the ear that are slightly cooler than core temperature.<sup>9,13,14</sup> Unusual sites for LV, such as the BCG vaccination site, have been reported.<sup>15</sup> The

classic clinical appearance has been described as red or orange papules or nodules, which turn more yellowish upon diascopy, and hence the "apple-jelly" color. As the infection persists, well-demarcated papules and nodules at the periphery advance outward, while, centrally, an irregularly surfaced atrophic plaque develops. Squamous cell carcinoma and, much less frequently, basal cell carcinoma and sarcoma have been reported to occur in long standing lesions of LV.<sup>9,16</sup> However, the relative risk of development of these neoplasms is unknown.

The diagnosis is based on combinations of clinical presentation, biopsy findings, tissue culture, and, recently, detection of *M tuberculosis* DNA complex within the lesions.<sup>17</sup> Because usually a sparse number of bacilli are present in lesions of LV, it is not surprising that they are not routinely detected or isolated in biopsy specimens and cultures. The presence of the hallmark histopathologic change of caseous necrosis within granulomas, indicative of high bacilli load, is variable. Culture of the organism is the gold standard for diagnosis, but the isolation rate is also variable and often low (0%–50%).<sup>5,7,9</sup> The detection of *M tuberculosis* DNA complex via polymerase chain reaction may become the standard for diagnosing all forms in the future, but its sensitivity still may be low in paucibacillary cutaneous TB such as LV. Tan and coworkers were unable to detect DNA in all of their 32 cases of cutaneous TB using polymerase chain reaction.<sup>18</sup> In a recent study, however, polymerase chain reaction dot-blotting was shown to have sensitivity better than microscopic examination and was comparable with culture, achieving positive results in 60% of their specimens.<sup>19</sup>

Because the detection and isolation of the organism is often unfruitful in tissue specimens, the diagnosis may only be based on clinical presentation. The clinical differential diagnosis for LV can be extensive: sarcoidosis, discoid lupus erythematosus, deep fungal infections, syphilis, foreign body granuloma, leprosy, psoriasis, and other granulomatous disorders. Nongranulomatous diagnosis can be eliminated based on biopsy result. Diascopy may be helpful. Atypical mycobacterial and deep fungal infections do not display an apple-jelly color.<sup>6</sup> A negative tuberculin test provides strong evidence against LV because of the high degree of host immunity and is positive in most affected patients. Finally, a clinical response to antituberculosis chemotherapy may confirm the diagnosis.

The recommended treatment of LV does not differ from pulmonary TB. The standard triple therapy of INH, pyrazinamide, and rifampin for 6 months is recommended by the World Health Organization.<sup>20</sup> Pyrazinamide may be discontinued after 2 months, as



**Figure 4.** Granulomatous inflammation without caseous necrosis, along with dense infiltrate of lymphocytes at the periphery (H&E, original magnification  $\times 200$ ).

it was done for this patient. Ethambutol hydrochloride, pyrazinamide, and streptomycin contribute very little after 2 months of therapy.<sup>21</sup> If there is resistance to rifampin, 8 to 9 months of ethambutol, INH, pyrazinamide, and streptomycin are recommended.<sup>21</sup> INH use alone has been reported but is not appropriate.<sup>7</sup> Surgical treatments are useful when long-term medication is not possible.

Although the incidence and morbidity of TB have declined in the latter half of the last decade in the United States, the percentage of cases has increased in those born outside the United States.<sup>22</sup> Since TB may have a long latency period, especially LV in which the individuals have a high degree of immunity, the infection may manifest many years after arrival to the United States. Thus, clinicians should have a high index of suspicion in those individuals who are in a higher risk group.

## REFERENCES

1. World Health Organization. Information fact sheet no. 104: tuberculosis. Available at: <http://www.who.int/inf-fs/en/fact104.html>. Accessed June 15, 2000.
2. Centers for Disease Control and Prevention, Division of Tuberculosis Elimination. Tuberculosis cases and case rates per 100,000 population: states, 1999 and 1998. Available at: <http://www.cdc.gov/nchstp/tb/surv/surv99/surv99.htm>. Accessed June 15, 2000.
3. Yates VM, Ormerod LP. Cutaneous tuberculosis in Blackburn district (U.K.): a 15-year prospective series, 1981-95. *Br J Dermatol.* 1997;136:483-489.
4. Chong LY, Lo KK. Cutaneous tuberculosis in Hong Kong:



## LUPUS VULGARIS

- a 10-year retrospective study. *Int J Dermatol.* 1995;34:26-29.
5. Sehgal VN, Srivastava G, Khurana VK, et al. An appraisal of epidemiological, clinical, bacteriologic, histopathologic, and immunologic parameters in cutaneous tuberculosis. *Int J Dermatol.* 1987;26:521-526.
  6. Ackerman AB, Chongchitnant N, Sanchez J, et al. Tuberculosis. In: *Histologic Diagnosis of Inflammatory Skin Diseases: An Algorithmic Method Based on Pattern Analysis.* 2nd ed. Baltimore, Md: Williams and Wilkins; 1997:766-770.
  7. Marcoval J, Servitje O, Moreno A, et al. Lupus vulgaris: clinical, histopathologic, and bacteriologic study of 10 cases. *J Am Acad Dermatol.* 1992;26:404-407.
  8. Tecimer C, Oram Y, Tecimer T. Lupus vulgaris in a patient with pulmonary tuberculosis. *Cutis.* 1994;53:246-248.
  9. Bourke J, O'Shea D, Dervan P, et al. Lupus vulgaris—a report of 3 cases. *Ir J Med Sci.* 1988;157:154-156.
  10. Sehgal VN, Wagh SA. Cutaneous tuberculosis. *Int J Dermatol.* 1990;29:237-252.
  11. Munn SE, Basarab T, Jones RR. Lupus vulgaris—a case report. *Clin Exp Dermatol.* 1995;20:56-57.
  12. Moin A, Downham TF. A slow growing lesion on the face: lupus vulgaris. *Arch Dermatol.* 1996;132:83,86.
  13. Okazaki M, Sakurai A. Lupus vulgaris of the earlobe. *Ann Plast Surg.* 1997;39:643-646.
  14. Jaisankar TJ, Garg BR, Reddy BS, et al. Penile lupus vulgaris. *Int J Dermatol.* 1994;33:272-274.
  15. Izumi AK, Matsunaga J. BCG vaccine-induced lupus vulgaris. *Arch Dermatol.* 1982;118:171-172.
  16. Gooptu C, Marks N, Thomas J, et al. Squamous cell carcinoma associated with lupus vulgaris. *Clin Exp Dermatol.* 1998;23:99-102.
  17. Serfling U, Penneys NS, Leonardi CL. Identification of *Mycobacterium tuberculosis* DNA in a case of lupus vulgaris. *J Am Acad Dermatol.* 1993;28:318-322.
  18. Tan SH, Tan BH, Goh CL, et al. Detection of *Mycobacterium tuberculosis* DNA using polymerase chain reaction in cutaneous tuberculosis and tuberculids. *Int J Dermatol.* 1999;38:122-127.
  19. Arora SK, Kumar B, Sehgal S. Development of polymerase chain dot-blotting system for detecting cutaneous tuberculosis. *Br J Dermatol.* 2000;142:72-76.
  20. Sehgal VN, Bhattacharya SN, Jain S, et al. Cutaneous tuberculosis: evolving scenario. *Int J Dermatol.* 1994;33:97-104.
  21. Iseman MD. Tuberculosis chemotherapy, including directly observed therapy. In: *A Clinician's Guide to Tuberculosis.* Philadelphia, Pa: Lippincott Williams and Wilkins; 2000:271-321.
  22. Walker PF, Jaranson, J. Refugee and immigrant health care. *Med Clin North Am.* 1999;83:1103-1120.