

Lichen Sclerosus et Atrophicus Affecting the Wrists and Left Ankle and Clinically Simulating Lichen Planus

Raúl Corbalán-Vélez, MD, Zaragoza, Spain

Amparo Pérez-Ferriols, MD, Valencia, Spain

Lichen sclerosus et atrophicus (LSA) is a disease of unknown etiology, although hereditary, endocrine, and autoimmune factors are known to be involved. Although the anal and genital regions are predominantly affected, 2.5% of patients only present with extragenital lesions—particularly of the trunk, neck, and upper limbs. The wrists, palmoplantar regions, nipples, and face are less commonly involved. The possible relationship between LSA and both lichen planus and localized scleroderma (morphea) has not been clearly established, although in a number of cases, several of these conditions have been found simultaneously. We report the case of a 61-year-old woman with LSA lesions affecting only the wrists and left ankle. The unusual character of this presentation is pointed out, along with its clinical similarity to lichen planus.

Lichen sclerosus et atrophicus (LSA) is a disease of unknown yet multifactorial etiology in which hereditary, endocrine, and autoimmune factors are known to be involved.^{1,2} The disease tends to affect the anogenital region either alone or in combination with other areas (15.5% of patients). In 2.5% of cases, only extragenital areas are affected² in the form of depressed and atrophic, whitish papules or maculae that merge to form larger plaques. The lesions tend to affect the upper half of the trunk, neck, and upper limbs. The face,³ nipples,⁴ wrists,⁵ and palmoplantar regions⁵⁻⁸ are involved less frequently.

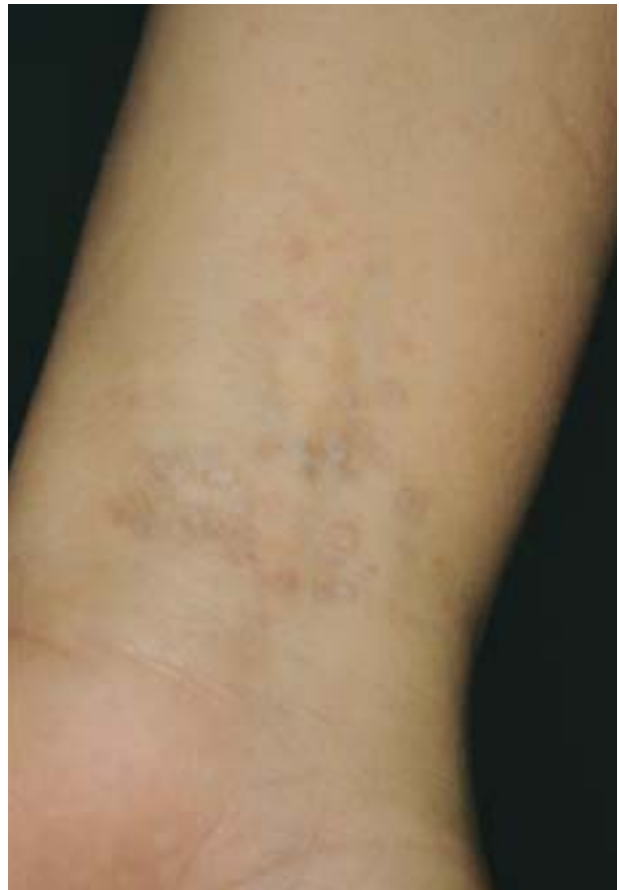

Figure 1. Polygonal papular and centrally depressed lesions on the right wrist.

Case Report

A 61-year-old woman with a history of uterine polypectomy presented with a 3-year history of asymptomatic lesions that initially developed on the right wrist and posteriorly also appeared on the contralateral wrist and left ankle. Exploration revealed small, centrally depressed, polygonal papular lesions on the right wrist (Figure 1) that left

Dr. Corbalán-Vélez is from the Department of Dermatology, University Clinic Hospital Lozano Blesa, Zaragoza, Spain.

Dr. Pérez-Ferriols is from the Department of Dermatology, University General Hospital, Valencia, Spain.

Reprints: Juan Ramón Jiménez, 6, 1ºD, 30430, Cehegin (Murcia), Spain.

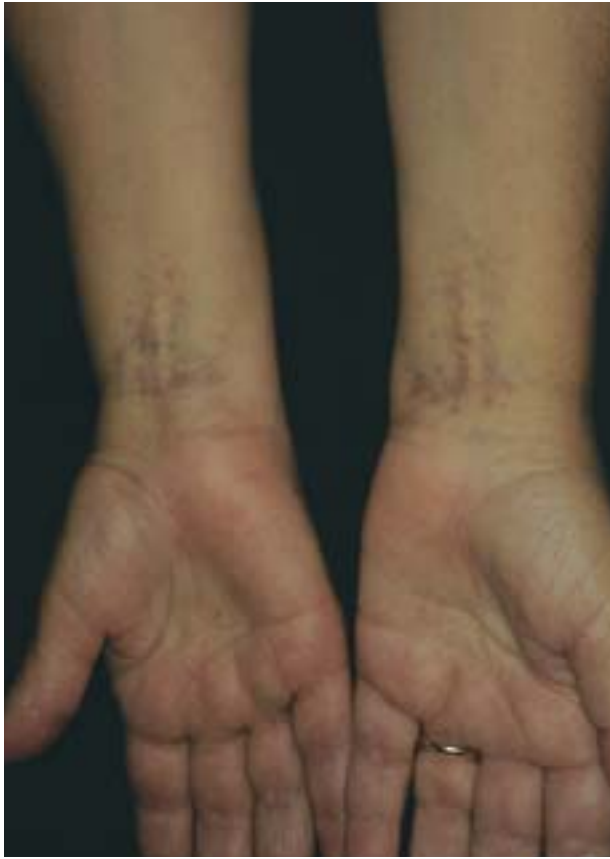

Figure 2. Bilateral, symmetric lesions and residual hyperpigmentation affecting both wrists.

residual hyperpigmentation upon resolution. The left wrist (Figure 2) and ankle only showed atrophic and hyperpigmented areas, without clinically active lesions. There were no lesions of the oral mucosa, genitals, or rest of the body. Physical examination was otherwise normal.

Laboratory studies, including hemogram, biochemistry, and antibodies against thyroid, parietal cells, thyroglobulin, mitochondria, and antinuclear antibodies revealed slightly elevated cholesterol levels of 275 mg/dL. The remaining parameters were either normal or negative.

The histopathologic study of one of the lesions on the right wrist showed compact, predominantly follicular, orthokeratotic hyperkeratosis, along with epidermal atrophy, homogenization of the underlying collagen, dermal papillary edema, and a lymphohistiocytic band infiltration of the superior dermis (Figures 3 and 4).

The patient was diagnosed with extragenital LSA, and topical corticosteroid treatment produced a clear improvement of the lesions.

Comment

Cases have been reported of simultaneous LSA and

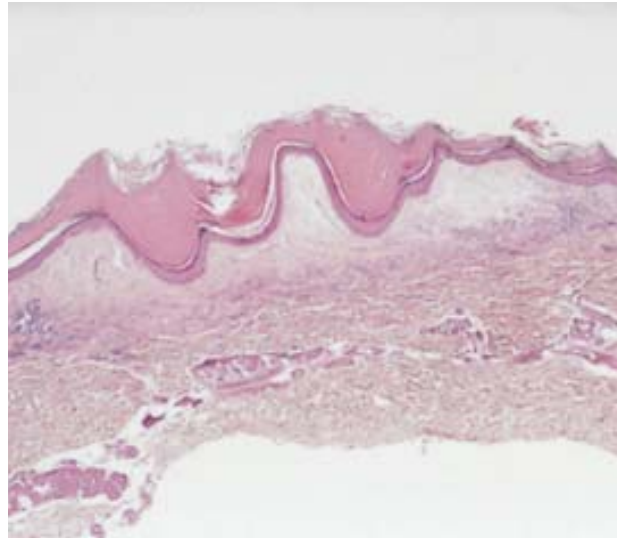


Figure 3. Orthokeratotic hyperkeratosis, epidermal atrophy, collagen homogenization, and band infiltration of the superior dermis (H&E, original magnification ×100).

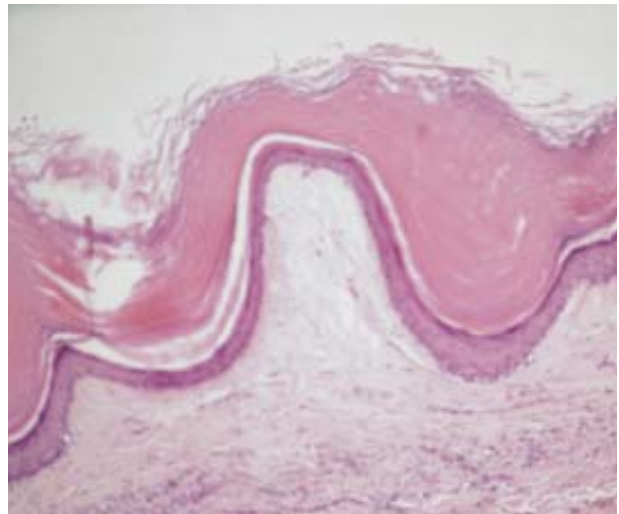


Figure 4. Detail of dermal papillary edema and homogenized collagen (H&E, original magnification ×400).

localized scleroderma (morphea) in the same patient and even within the same lesion.⁹⁻¹³ The coexistence of LSA and lichen planus¹⁴⁻¹⁶ and even the coexistence of all 3 diseases also has been described in the literature.¹⁷

All of these findings support the hypothesis of a similar etiopathogenesis shared among these 3 diseases which, according to certain authors,¹³⁻¹⁷ could reflect the same disease with different clinical and histopathologic patterns of presentation. In this case, the lesions were clinically suggestive of LSA (white-grayish, centrally depressed, papular lesions with keratotic plugs), although both the symmetric distribution and residual hyperpigmentation were more characteristic of lichen planus.

REFERENCES

1. Ridley CM. Lichen sclerosus et atrophicus. *Semin Dermatol*. 1989;8:54-63.
2. Meyrick Thomas RH, Ridley CM, McGibbon DH, et al. Lichen sclerosus et atrophicus and autoimmunity—a study of 350 women. *Br J Dermatol*. 1988;118:41-46.
3. Patel RI, Reed WB. Annular atrophic plaques of the face and upper body: an unusual variant of lichen sclerosus et atrophicus or lichen planus. *Cutis*. 1979;24:90-93.
4. Alexandre J, Walderez M. Lichen sclerosus et atrophicus of rare location. *Med Cutan Ibero Lat Am*. 1977;28:604-607.
5. Tudino ME, Wong AK. Bullous lichen sclerosus et atrophicus on the palms and wrists. *Cutis*. 1984;33:475-476.
6. Purres J, Krull EA. Lichen sclerosus et atrophicus involving the palms. *Arch Dermatol*. 1971;104:68-69.
7. Lampert A, Fortier-Beaulieu M, Thomine E, et al. Palmar-plantar lichen sclerosus et atrophicus. *Arch Dermatol*. 1979;115:884.
8. Hammar H. Plantar lesions of lichen sclerosus et atrophicus accompanied by erythralgia. *Acta Derm Venereol*. 1978;58:91-92.
9. Lampert A, Fortier-Beaulieu M, Thomine E, et al. Association sur un membre d'un lichen scléroseux et d'une sclérodermie monomélisque. *Ann Dermatol Venereol*. 1995;122:102-104.
10. Izumi T, Tajima S. A case of linear type of lichen sclerosus et atrophicus? *J Dermatol*. 1995;22:279-282.
11. Natarajan S, Green ST. Generalized morphea, lichen sclerosus et atrophicus and primary biliary cirrhosis. *Clin Exp Dermatol*. 1986;11:304-308.
12. Shono S, Imura M, Ota M, et al. Lichen sclerosus et atrophicus, morphea and coexistence of both diseases. *Arch Dermatol*. 1991;127:1352-1356.
13. Tremaine R, Adam JE, Orizaga M. Morphea coexisting with lichen sclerosus et atrophicus. *Int J Dermatol*. 1990;29:486-489.
14. Marren P, Millard P, Chia Y, et al. Mucosal lichen sclerosus/lichen planus overlap syndromes. *Br J Dermatol*. 1994;131:118-123.
15. Graham-Brown RA, Sarkany I. Lichen sclerosus et atrophicus with primary biliary cirrhosis and lichen planus. *Int J Dermatol*. 1986;25:317.
16. Grussendorf EI. Lichen sclerosus et atrophicus and lichen ruber planus. *Hautarzt*. 1977;28:604-607.
17. Connelly MG, Winkelmann RK. Coexistence of lichen sclerosus, morphea, and lichen planus. *J Am Acad Dermatol*. 1985;12:844-845.