

# Lasers in Dermatology: A Review

Ralph A. Massey, MD, New York, New York

Gina Marrero, MD, New York, New York

Mimi Goel-Bansal, MD, New York, New York

Robyn Gmyrek, MD, New York, New York

Bruce E. Katz, MD, New York, New York

*The revolution in laser technology has had a significant impact on medicine in general and dermatology in particular and has piqued the interest of physicians, the lay public, and the media. Advances in laser therapy have dramatically improved the clinicians' ability to treat cosmetic and noncosmetic skin lesions safely and effectively. The number and variety of skin problems amenable to laser treatment continues to grow. We will provide a review of the major cosmetic and therapeutic applications of laser therapy.*

It is not often in medicine that the advances in a particular technology simultaneously capture the imagination and immense curiosity of physicians, the lay public, and the media. This has been the case with laser applications in dermatology. The great interest in this subject is primarily because of the enhanced specificity of laser interactions with skin and the significant advances of laser applications in cosmetic surgery.

The great proliferation in laser technology is due in large part to the concept of selective photothermolysis. In other words, if a targeted tissue (chromophore) strongly absorbs a selected wavelength, and the pulse duration is shorter than the thermal relaxation time (cooling time) of the tissue, then only selective thermal injury will occur. By limiting thermal damage to the target chromophore, less injury occurs to the surrounding tissue, with a reduced risk for scarring.

Lasers that were developed based on the principle of selective photothermolysis include the pulsed dye, Q-switched ruby, neodymium:yttrium aluminum garnet (Nd:YAG), alexandrite, carbon dioxide (CO<sub>2</sub>), and erbium:yttrium aluminum garnet (Er:YAG). The precise, controlled, and reproducible effects of these

lasers have resulted in their successful application to a wide variety of conditions. These include vascular and pigmented lesions, acne scarring, wrinkled and sun-damaged skin, tattoos, hypertrophic scars, warts, stretch marks, excessive hair, and skin cancer.

Although many practitioners are not directly involved in laser therapy, a basic knowledge of its applications is vital given the considerable public interest in this field. This review will describe the types of conditions treated and the appropriate lasers used.

## Vascular Lesions

Vascular lesions such as port-wine stains were among the first to be treated effectively with lasers, and much of our understanding of laser tissue interactions stems from this work. Today, a wide variety of lasers are used to treat both congenital and acquired vascular lesions, including port-wine stains, hemangiomas, facial telangiectasias, poikiloderma, cherry angiomas, venous lakes, and spider leg veins. Many variables may affect the efficacy of lasers in treating these lesions, for example: the depth and caliber of the target vessels; the level of pigmentation of the overlying epidermis; and the emission wavelength, pulse duration, spot size, and fluence (energy output) of the laser.

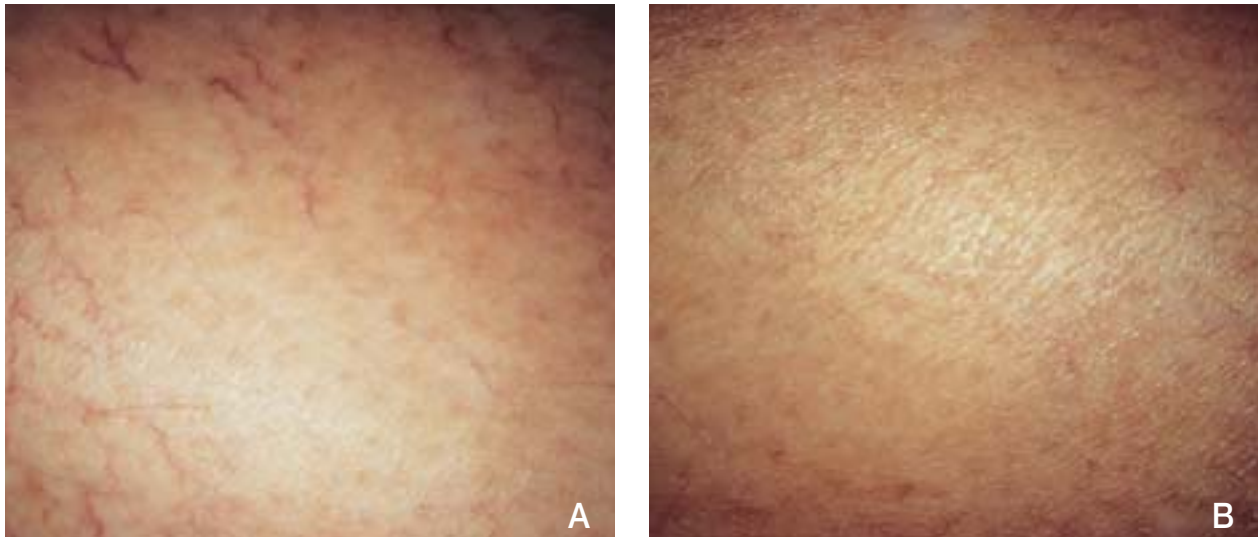
When treating vascular lesions, the chromophore targeted is hemoglobin. The efficiency of energy transfer to the chromophore will depend on the wavelength of the laser. Hemoglobin has absorption peaks at 418 nm, 542 nm, and 577 nm. Energy absorption by this chromophore results in local thermal damage. Limiting the spread of this damage is achieved best with a pulse duration that is less than the thermal relaxation time of the target vessels.<sup>1</sup>

The first laser used in dermatology was the argon laser, with emission bands at 488 and 514 nm. Although this did not coincide directly with one of the absorption peaks of hemoglobin, it was sufficiently well-absorbed to have a selective effect on vascular lesions. The relatively long pulse duration of

---

Drs. Massey, Marrero, Goel-Bansal, Gmyrek, and Katz are from the Department of Dermatology, Columbia University, College of Physicians and Surgeons, New York, New York.

Reprints: Bruce E. Katz, MD, JUVA Skin & Laser Center, 60 E 56th St, New York, NY 10022.



**Figure 1.** Spider leg veins before (A) and 3 months after (B) VersaPulse laser treatment.

this laser was associated, however, with a significant risk for fibrosis and scarring.

The first pulsed-dye laser had an emission wavelength of 577 nm to coincide with one of the absorption peaks of hemoglobin. The more recently developed pulsed-dye lasers of 585 nm have a greater depth of penetration at this longer wavelength. These new lasers have a pulse duration of 450  $\mu$ s, which is less than the thermal relaxation time of the target vessels. This gives good results and a better safety profile than the argon laser. However, purpura resulting from rupture of the target vessels, probably as a result of the short pulse duration, is a significant cosmetic problem.

The frequency-doubled, 532-nm Nd:YAG laser does not coincide with one of the absorption peaks of hemoglobin but, nevertheless, has shown great utility for the treatment of vascular lesions such as facial telangiectasias<sup>2,3</sup> and leg veins.<sup>4</sup> The pulse duration of this laser (1–50 ms) may allow for intravascular coagulation without vessel rupture or significant peripheral thermal damage, causing slower heat transfer to the target vessel. Presently, this means that the post-operative purpura seen with the pulsed-dye laser can be avoided, without an increased risk for scarring. Even longer pulse durations, up to 50 ms, are being evaluated for the treatment of larger vascular lesions, such as leg veins.

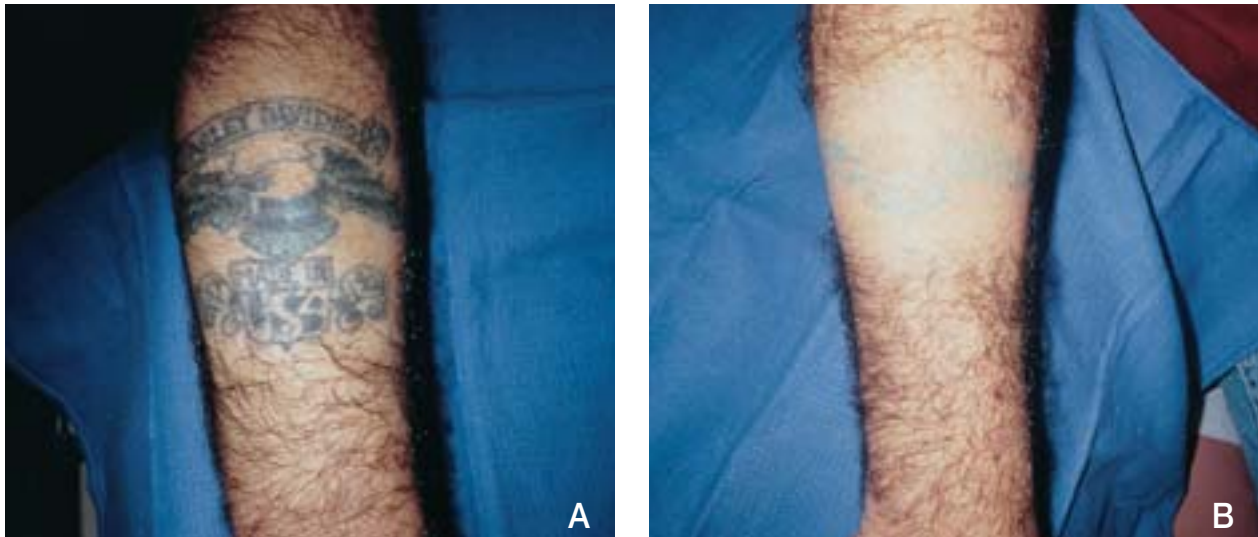
Despite efforts to match the laser wavelength to one of the absorption peaks of hemoglobin, some energy will be absorbed by epidermal melanin. Thus, there is always a risk for epidermal damage, with resultant hypopigmentation, hyperpigmentation, or even scarring. One method of limiting damage is the use of simultaneous epidermal cooling. This can be achieved with either a transparent, water-cooled

“chill tip” that is placed on the skin overlying the vessel to be treated<sup>5</sup> or a dynamic cooling device that sprays a brief spurt of cryogen before the laser pulse.<sup>6</sup> The benefits of these methods include decreased pain and limited epidermal heating and damage.

Any of the following lasers can be used to treat a variety of vascular lesions: the argon at 488 to 514 nm; the frequency-doubled Nd:YAG at 532 nm; the krypton at 568 nm; the argon dye at 577 to 600 nm; the copper vapor at 578 nm; and the pulsed dye at 585, 595, and 600 nm. In principle, any cutaneous vascular lesion may be helped by laser therapy, and lasers are recognized as the treatment of choice for many of these lesions (Figure 1). However, no one laser is ideal for all types of vascular lesions. Lasers with longer wavelengths penetrate more deeply, thus having an advantage for the treatment of deeper lesions. Target vessels, as opposed to epidermal melanin, will absorb lasers with wavelengths at or close to one of the absorption peaks of hemoglobin more selectively. A longer pulse duration may be advantageous in treating larger caliber vessels. Epidermal cooling devices may limit some of the more common side effects. As investigators try different combinations of these and other laser parameters, more will be learned about which lasers and what settings are appropriate for any given vascular lesion.

### Pigmented Lesions

Treatment of benign pigmented lesions, including solar lentigines, ephelides, melasma, and Ota’s nevus, as well as red, blue, black, and green tattoos, has been revolutionized by the advent of the Q-switched lasers. “Q-switching” refers to lasers that produce very high power and extremely short pulses of light. The Q-switched lasers approved for use in



**Figure 2.** Tattoo before (A) and after (B) 4 treatments with the 1064-nm Nd:YAG laser.

the United States are the ruby, which emits a red light at 695-nm wavelength; the Nd:YAG, at 1064 nm in the near-infrared spectrum and 532 nm in the green light spectrum; and the alexandrite, which emits a red light at 755 nm.<sup>7,8</sup> The predominant chromophores for these lasers are melanin and exogenously placed tattoo pigment, and the wavelengths of these lasers are long enough to penetrate into the dermis where there is tattoo ink or dermal pigment.<sup>8</sup> Therefore, considerable gains have been made with these lasers for the treatment of decorative, traumatic, and cosmetic tattoos, as well as benign pigmented lesions and congenital nevi.

All of these lasers are effective in treating tattoos. It is believed that the destruction of tattoos occurs through energy transfer, as well as through photoacoustic waves occurring secondary to the ultrashort pulse duration of these lasers. This breaks the tattoo particles into smaller pieces. Then, the tattoo fragments are phagocytosed and removed by macrophages, with only a small amount of pigment being eliminated through the epidermis.<sup>8</sup> Blue-black tattoos respond best to the Q-switched ruby and 1064-nm Nd:YAG lasers (Figure 2); green tattoos fade quickest with the alexandrite laser; and red tattoos are treated most appropriately by the shorter wavelength 532-nm Nd:YAG laser. It is important to remember that professional tattoos do not respond as quickly as amateur tattoos.<sup>9</sup>

A concern in treating the red, white, and flesh-colored ink tattoos used in permanent eyeliner and lip liner is the chemical reaction that may occur, leading to the immediate blackening of the ink. This black discoloration is often resistant to subsequent treatments.<sup>10</sup>

Pigmented lesions with a predominant epidermal

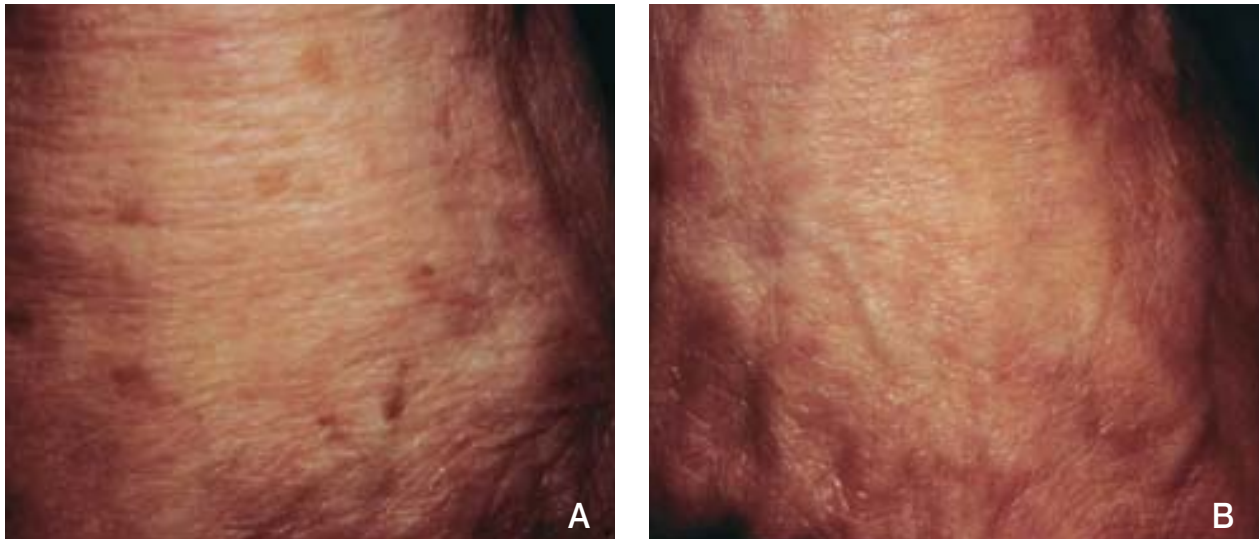
component, such as lentigines and ephelides, may be treated by all of these lasers, with lightening usually occurring in 3 to 6 weeks (Figure 3). Café au lait maculae, Becker's nevi, and melasma have a variable response to these lasers.<sup>11</sup> Melasma may recur, even after successful treatment, especially if patients are not diligent with their use of sunscreens. Infraorbital hyperpigmentation associated with dermal melanin pigment also shows improvement with the ruby, alexandrite, and 532-nm Nd:YAG lasers, as well as with the nonpigment-specific, high-energy, pulsed CO<sub>2</sub> laser.<sup>12,13</sup>

Lesions with a deeper dermal pigmented component, including Ota's nevi and congenital nevi, respond better to the longer wavelength Q-switched lasers such as the ruby, 1064-nm Nd:YAG, and alexandrite. However, deeper dermal melanocytes may persist.

The most common side effects associated with these lasers are loss of tanning, erythema, and postinflammatory hyperpigmentation or hypopigmentation. Rarely, textural changes or scarring may occur. The hypopigmentation is transient and usually resolves spontaneously.

Other non-Q-switched lasers used to treat pigmented lesions are the flashlamp-pumped pulsed dye with a green light at 510 nm and the krypton, which simultaneously produces a green light at 521 nm and 530 nm and a yellow light at 568 nm. These lasers treat benign, superficial pigmented lesions, such as lentigines, café au lait maculae, seborrheic keratoses, and postinflammatory hyperpigmentation.<sup>9</sup> Although the pulsed-dye laser has minimal risk for scarring or hypopigmentation, its use is limited by the unsightly posttreatment purpura, which may last 1 to 2 weeks.<sup>9</sup>

Recently, attention has been focused on the



**Figure 3.** Solar lentigines on the hand before (A) and 2 months after (B) 755-nm alexandrite laser treatment.

normal-mode (long pulse) ruby laser for the treatment of congenital nevi, which have abundant melanin and can be very large and disfiguring. This laser has a much longer pulse duration, which is advantageous for targeting large, dense nests of pigmented cells seen in certain congenital nevi.<sup>14</sup> The high-energy fluences used in this laser, coupled with the longer pulse duration, make the normal-mode ruby an appropriate laser to treat congenital nevi that were previously unresponsive to the Q-switched ruby laser. Another benefit is that the normal-mode ruby laser destroys melanocytes deep in the hair bulb, thereby potentially decreasing the risk for recurrence, as well as improving the overall cosmetic appearance. Recent studies note that the major side effect is slight scarring, but that otherwise the skin of the treated area shows improvement in both color and texture.<sup>14</sup>

The risk for recurrence using the normal-mode ruby laser is not completely known. Therefore, further studies with long-term follow-up are necessary to determine if treatment with this laser will affect the risk for developing malignant melanoma within large congenital nevi.

### Skin Resurfacing

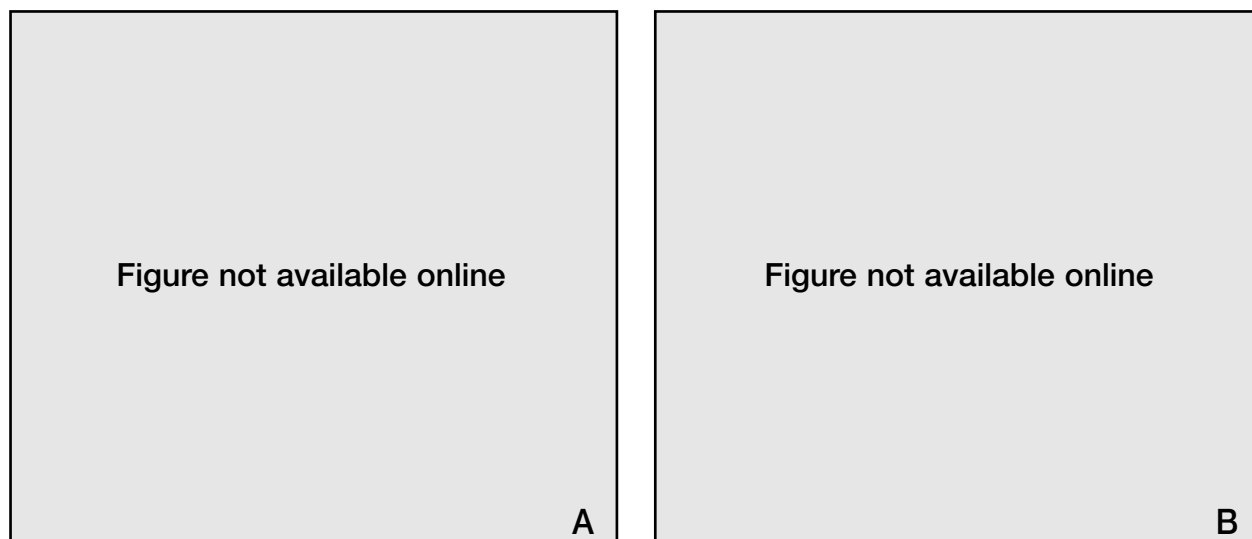
Skin resurfacing for the treatment of facial wrinkles, acne scarring, and dermatoheliosis has been an important modality in cosmetic dermatology for many years. In the past, this was achieved with either caustic chemicals or mechanical abrasions with reepithelialization from adnexal epithelium. Recently, lasers have been used to vaporize the epidermis and part of the dermis in a controlled manner. While resurfacing is usually used to eradicate facial rhytides or acne scarring,<sup>15-19</sup> it also can be used to treat a wide

variety of lesions, such as multiple trichoepitheliomas or adenoma sebaceum (Figure 4).<sup>20-23</sup>

The lasers presently used for skin resurfacing are the CO<sub>2</sub> at 10,600 nm and the Er:YAG at 2940 nm, although use of the Q-switched Nd:YAG also has been reported.<sup>24</sup>

Water is the chromophore targeted during laser skin resurfacing. The rapid heat transfer results in vaporization of the tissue. With the early CO<sub>2</sub> lasers that operated in a continuous mode, the tissue was exposed to the laser for longer than the thermal relaxation time of the skin.<sup>25</sup> As a result, peripheral thermal damage would occur to an unpredictable depth, with a significant risk for scarring. This problem has been solved in 2 different but equally effective ways. One method is to use superpulsed lasers that emit a high-powered pulse of very short duration.<sup>26-29</sup> Alternatively, the laser beam can be scanned across the tissue by a computerized scanning device in such a way that the laser interacts with any one spot on the tissue for less than 1 ms, even though the total pulse duration may be significantly longer.<sup>30-31</sup>

With each pass of the laser, a predictable thickness of tissue is vaporized. By adjusting the power, spot size, and number of passes, the depth of ablation can be controlled accurately. The Er:YAG laser at 2940 nm is absorbed even more avidly by water than with the CO<sub>2</sub> laser. Consequently, the peripheral heat transfer and thermal necrosis zone will be less with each pass of the Er:YAG than with the CO<sub>2</sub> laser,<sup>32,33</sup> resulting in less thermal injury and a slightly more rapid healing time. However, the CO<sub>2</sub> laser has the advantage of coagulating small blood vessels, allowing for a relatively bloodless field during resurfacing. Furthermore, the peripheral heat transfer seen with the CO<sub>2</sub>



**Figure 4.** Facial wrinkles before (A) and 4 months after (B) CO<sub>2</sub> laser skin resurfacing.

laser may be beneficial in causing collagen shrinkage, thus having a skin-tightening effect.<sup>34,36</sup>

In laser skin resurfacing, as with any cosmetic procedure, appropriate patient selection is a vital consideration that may affect the final outcome. This includes a careful assessment of the patient's risk for various complications, such as infection, scarring, and dyspigmentation.<sup>37</sup>

### Removal of Hair

Removal of unwanted hair has been accomplished by multiple methods including shaving, wax epilation, chemical depilatories, electrolysis, and thermolysis. Electrolysis and thermolysis are the only 2 methods capable of providing permanent hair removal. These modalities are tedious, painful, and operator dependent; require numerous treatments; and carry the risk for scarring and infection.

In response to the need for safer and more efficacious hair removal, multiple techniques based on the theory of photothermolysis have been studied. The Nd:YAG laser at 1064 nm with an exogenous chromophore was the first laser system to be approved for hair removal. A carbon-based solution that penetrates to the depth of the follicle is applied to the skin surface. The excess solution is removed, and the laser is scanned over the treatment site. As the carbon particles absorb the light, they undergo a rapid temperature increase that causes thermal damage to the hair follicle. A single treatment has been shown to cause a growth delay of up to 6 months<sup>38</sup> but not permanent hair removal. Treatment with this laser is beneficial because it is independent of hair color, and side effects are rare. A few cases of temporary (<6 months) posttreatment hyperpigmentation have occurred, but scarring has never been reported.

Melanin, an endogenous chromophore, serves as a target for several systems, including the normal-mode ruby, long pulse alexandrite, and diode lasers, as well as a nonlaser pulsed-light source. It is an ideal target chromophore because there is increased melanin in the follicle compared with the surrounding epidermis or dermis, especially in the early anagen phase of the hair growth cycle. All lasers work by the same mechanism, and all have been approved for use, but most studies have been done with the ruby laser.

The 694-nm ruby laser's wavelength penetrates into the dermis, where it is absorbed preferentially by melanin in the follicle. The pulse width must be long enough to allow thermal damage to occur to the hair follicle. This is evidenced by studies using the Q-switched ruby laser, which, at a pulse duration of nanoseconds, is able to cause only leukotrichia but not hair loss. The normal-mode ruby laser has a pulse duration that is between the thermal relaxation time for the hair follicle (estimated at 200–300  $\mu$ m) and the epidermis (3–10 ms).<sup>39</sup> It has proven efficacious in delaying growth, and in one study, even achieving permanent hair loss.<sup>40</sup> It is hypothesized that the longer pulse duration allows for greater thermal conduction and destruction of the follicle. A cooling hand piece is placed at the skin surface to conduct heat away from the epidermis and minimize thermal damage. Hair removal with the ruby laser is much more efficacious in the fair-skinned, dark-haired patient. Darker-skinned patients are at greater risk for alterations in their pigment because epidermal melanin may act as a competing chromophore.

Another method of hair removal involves the use of a nonlaser pulsed-light source. This system uses an intense source of white light from a flashlamp that is

filtered so that a spectrum of wavelengths all greater than 590 nm is delivered to the skin.<sup>41</sup>

Photodynamic therapy also has been used for hair removal.<sup>42</sup> It uses topical  $\delta$ -aminolevulinic acid (ALA) that induces the synthesis of a potent photosensitizer by follicular cells. An argon-pumped laser dye (630 nm) is used to induce the production of single-oxygen molecules that cause membrane damage. This method allows for the treatment of large areas and is independent of skin and hair color. Further studies are needed to determine the safety and efficacy of this therapy.

Currently, lasers provide effective and possibly permanent hair removal, with minimal discomfort and low risk for scarring. As laser technology continues to advance and with additional understanding of germinal hair centers, it is likely that methods of permanent, cost-effective, and relatively painless hair removal will be developed in the near future.

### Other Applications

With the expansion of laser technology, an increasingly diverse range of conditions can be treated. As dermatologists continue to explore other applications for laser therapy, the literature is growing.

The CO<sub>2</sub> laser can be used in various therapeutic modes, for example, for tissue ablation, as a cutting tool, or for skin resurfacing. Furthermore, it can treat a variety of benign, infectious, premalignant, and malignant skin lesions. Examples of benign lesions vaporized by the CO<sub>2</sub> laser include trichoepitheliomas, syringomas, xanthelasma, adenoma sebaceum, lymphangioma circumscriptum, neurofibromas, myxoid cysts, apocrine hydrocystomas, rhinophyma, skin tags, seborrheic keratoses, nevus sebaceus, pyogenic granulomas, and warts. Inflammatory conditions treated by the CO<sub>2</sub> laser include Hailey-Hailey disease. Malignant and premalignant disorders treated with the CO<sub>2</sub> laser include superficial basal cell carcinomas, actinic keratoses, actinic cheilitis, balanitis xerotica obliterans, bowenoid papulosis, kraurosis vulvae, balanitis of Zoon, and erythroplasia of Queyrat. The CO<sub>2</sub> laser also has been used for tissue vaporization in the treatment of recalcitrant warts.<sup>43,44</sup>

The CO<sub>2</sub> laser can be used as a cutting tool in excisional and cosmetic surgery, including blepharoplasty, hair transplantation, excision of rhinophyma, and keloids. This laser allows a relatively bloodless surgical field by sealing vessels up to 0.5 mm in diameter. This is especially important in patients who are taking warfarin or have bleeding disorders or in the excision of highly vascular tumors. In addition, it has proved useful in nail surgery.<sup>44</sup>

The Er:YAG laser is used for tissue vaporization, even though it lacks the hemostatic effect of the CO<sub>2</sub>

laser. Adnexal lesions such as sebaceous hyperplasia, adenoma sebaceum, syringomas, and telangiectatic fibromas have been treated with the Er:YAG laser, as well as other benign lesions such as xanthelasma.<sup>45</sup>

Other than hemangiomas and telangiectasias, the list of lesions treatable with vascular lasers is growing. Pulsed-dye lasers cause alteration of the dermis by increasing the amount of collagen and elastin in the skin and have proved effective for the treatment of striae, hypertrophic scars, and keloids.<sup>46,47</sup> Pulsed-dye lasers have been used to treat a variety of benign, inflammatory, and infectious lesions, including psoriasis,<sup>48</sup> warts,<sup>49</sup> xanthelasma,<sup>50</sup> and sebaceous hyperplasia.<sup>51</sup>

Photodynamic therapy is a form of photochemotherapy utilizing light to activate a photosensitizer to generate singlet oxygen and other free radicals. The photosensitizer commonly used in dermatology is topical ALA, with the lesion being irradiated 4 to 6 hours after application. Both laser and nonlaser light sources have been used, such as the argon ion pumped-dye laser at 630 nm and the filtered projector machine light.

Photodynamic therapy is used most often to treat actinic keratoses, Bowen's disease, or multiple superficial cancers (eg, in patients who have basal cell nevus syndrome). Also, it has been tried in other multiple tumors, with variable results. Their use in acne, viral warts, alopecia areata, port-wine stains, and hair removal is being investigated.<sup>52</sup>

Laser treatment of psoriasis and vitiligo has recently shown significant promise with the use of a 308-nm wavelength laser. Although multiple sessions are required, it is reassuring that innovative technology is now available for these 2 recalcitrant conditions.

One of the most recent developments in laser therapy is nonablative laser resurfacing. This methodology also is referred to as laser photo-rejuvenation, laser toning, N-Lite, and Foto-Facial treatment. A variety of laser wavelengths and light sources are used, including 532, 585, 595, 1064, 1320, and 1450 nm. The significant advantages to this novel therapy are that epidermal, vascular, and pigmented lesions such as telangiectasias and lentiginos are improved, and new dermal collagen formation also seems to be stimulated, resulting in improvement of wrinkles. This is all without any downtime. The proposed mechanism of action is nonspecific laser-energy absorption by dermal vessels leading to release of cytokines, which produce fibroblast stimulation and new collagen formation. Although the typical clinical reaction from the laser treatment is minor redness and slight swelling for 12 to 24 hours, a series of 3 to 5 treatments at 2- to 3-week intervals often is needed for maximum benefit.

## Conclusion

Advances in laser technology have added a new dimension to dermatology. As the variety of lesions being treated with lasers continues to grow, so will our experience and knowledge. Having a firm understanding of how lasers work enables the physician to tailor the type of laser used to target the lesion.

## REFERENCES

1. Anderson RR, Parrish JA. Microvasculature can be selectively damaged using dye lasers: a basic theory and experimental evidence in the human skin. *Lasers Surg Med.* 1987; 1:263-276.
2. Oscar Hevia O. New treatment for facial telangiectasias: a randomized study. *Cosmetic Dermatol.* 1997;10:53-56.
3. Adrian RM, Tanghetti EA. Long pulse 532-nm laser treatment of facial telangiectasias. *Dermatol Surg.* 1998;24: 71-74.
4. Adrian RM. Treatment of leg telangiectasias using a long-pulse frequency-doubled neodymium:YAG laser at 532 nm. *Dermatol Surg.* 1998;24:19-23.
5. Chess C, Chess Q. Cool laser optics treatment of large telangiectasia of the lower extremities. *J Dermatol Surg Oncol.* 1993;19:74-80.
6. Waldorf HA, Alster TS, McMillan K, et al. Effect of dynamic cooling on 585 nm pulsed dye laser treatment of port wine stain birthmarks. *Dermatol Surg.* 1997;23: 657-662.
7. Goldberg DJ. Laser treatment of pigmented lesions. *Dermatol Clin.* 1997;15:397-407.
8. Kilmer SL. Laser treatment of tattoos. *Dermatol Clin.* 1997; 15:409-417.
9. Wheeland RG. Cosmetic laser surgery. In: Coleman W, Hanke CW, Alt TH, et al, eds. *Cosmetic Surgery of the Skin: Principles and Practices.* St Louis, Mo: Mosby; 1997:782-791.
10. Kilmer SL, Anderson RR. Clinical use of the Q-switched ruby and the Q-switched Nd:YAG (1064 nm and 532 nm) lasers for treatment of tattoos. *J Dermatol Surg Oncol.* 1993; 19:330-338.
11. Goldberg DJ. Benign pigmented lesions of the skin: treatment with the Q-switched ruby laser. *J Dermatol Surg Oncol.* 1993;19:376-379.
12. Lowe NJ, Wieder JM, Shorr N, et al. Infraorbital pigmented skin: preliminary observations of laser therapy. *Dermatol Surg.* 1995;21:767-770.
13. West TB, Alster TS. Improvement of infraorbital hyperpigmentation following carbon dioxide laser resurfacing. *Dermatol Surg.* 1998;24:615-616.
14. Ueda S, Imayama S. Normal-mode ruby laser for treating congenital nevi. *Arch Dermatol.* 1997;133:355-359.
15. Waldorf HA, Kauvar ANB, Geronemus RG. Skin resurfacing of fine to deep rhytides using a char-free carbon dioxide laser in 47 patients. *Dermatol Surg.* 1995;21:940-946.
16. Lowe NJ, Lask G, Griffin ME, et al. Skin resurfacing with the ultrapulse carbon dioxide laser. *Dermatol Surg.* 1995;21: 1025-1029.
17. Garrett AB, Dufresne RG, Ratz JL, et al. Carbon dioxide laser treatment of pitted acne scarring. *J Dermatol Surg Oncol.* 1990;16:737-740.
18. Ratz J, McGillis S. Treatment of facial acne scarring with the carbon dioxide laser. *Am J Cosmetic Surg.* 1992;9:181-183.
19. Alster TS, West TB. Resurfacing of atrophic facial acne scars with a high-energy, pulsed carbon dioxide laser. *Dermatol Surg.* 1996;22:151-152.
20. Wheeland RG, Bailin PL, Kronberg E. Carbon dioxide (CO<sub>2</sub>) laser vaporization for the treatment of multiple trichoepithelioma. *J Dermatol Surg Oncol.* 1984;10:470-475.
21. Rosenbach A, Alster TS. Multiple trichoepitheliomas successfully treated with a high-energy, pulsed carbon dioxide laser. *Dermatol Surg.* 1997;23:708-710.
22. Wheeland RG, Bailin PL, Kantor GR, et al. Treatment of adenoma sebaceum with carbon dioxide laser vaporization. *J Dermatol Surg Oncol.* 1985;11:861-864.
23. Boixeda P, Sanchez-Miralles E, Azana JM, et al. CO<sub>2</sub>, argon, and pulsed dye laser treatment of angiofibromas. *J Dermatol Surg Oncol.* 1994;20:808-812.
24. Goldberg DJ, Whitworth J. Laser resurfacing with the Q-switched Nd:YAG laser. *Dermatol Surg.* 1997;23:903-907.
25. David LM, Lask GP, Glassberg E, et al. Laser abrasion for cosmetic and medical treatment of facial actinic damage. *Cutis.* 1989;43:583-587.
26. Hobbs ER, Bailin PL, Wheeland RG, et al. Superpulsed lasers: minimizing thermal damage with short duration, high irradiance pulses. *J Dermatol Surg Oncol.* 1987;13: 955-964.
27. Fitzpatrick R, Ruiz-Esparza J, Goldman M. The clinical advantage of the superpulse carbon dioxide lasers [abstract]. *Lasers Surg Med Suppl.* 1990;2:52.
28. Fitzpatrick R, Goldman M, Satur N, et al. Pulsed carbon dioxide laser resurfacing of photoaged skin. *Arch Dermatol.* 1996;132:395-402.
29. Ross E, Domankevitz Y, Skrobal M, et al. Effects of pulse duration on CO<sub>2</sub> laser ablation: implications for laser resurfacing. *Lasers Surg Med.* 1996;19:123-129.
30. Lask G, Keller G, Lowe N, et al. Laser skin resurfacing with the silk touch flashscanner for facial rhytides. *Dermatol Surg.* 1995;21:1021-1024.
31. David LM, Same AJ, Unger WP. Rapid laser scanning for facial resurfacing. *Dermatol Surg.* 1995;21:1031-1033.
32. Walsh JT, Flotte TJ, Deutsch TF. Er:YAG laser ablation of tissue: effect of pulse duration and tissue type on thermal damage. *Lasers Surg Med.* 1989;9:314-326.
33. Teikmier G, Goldberg DJ. Skin resurfacing with the Erbium:YAG laser. *Dermatol Surg.* 1997;23:685-687.
34. Stringer H, Parr J. Shrinkage temperature of eye collagen. *Nature.* 1964;204:1307.
35. Gardner ES, Reinsch L, Stricklin GP, et al. In vitro changes in non-facial human skin following CO<sub>2</sub> laser resurfacing: a comparison study. *Lasers Surg Med.* 1996;19:379-387.

36. Ross EV, Naseef GS, Skrobal M, et al. In vivo dermal collagen shrinkage and remodeling following CO<sub>2</sub> laser resurfacing [abstract]. *Lasers Surg Med.* 1996;8:38.
37. Massey R, Jones D, Diamond J, et al. The importance of patient selection in CO<sub>2</sub> laser skin resurfacing. *Cosmetic Dermatol.* 1997;10:10-13.
38. Nanni C, Alster T. Optimizing treatment parameters for hair removal using a topical carbon based solution and 1064 nm Q switched Neodymium:YAG laser energy. *Arch Dermatol.* 1997;133:1546-1549.
39. Grossman MC, Dierickx C, Farinelli W, et al. Damage to hair follicles by normal-mode ruby laser pulses. *J Am Acad Dermatol.* 1996;35:889-894.
40. Dierickx CC, Grossman MC, Farinelli WA, et al. Permanent hair removal by normal-mode ruby laser. *Arch Dermatol.* 1998;134:837-842.
41. Gold MH, Bell MW, Foster TD, et al. Long term epilation using the Epilight broad band, intense pulsed light hair removal system. *Dermatol Surg.* 1997;23:909-913.
42. Grossman MC, Wimberly J, Dwyer P, et al. PDT for hirsutism. *Lasers Surg Med.* 1995;17(suppl):41.
43. Spicier MS, Goldberg DJ. Lasers in dermatology. *J Am Acad Dermatol.* 1996;34:1-25.
44. Hruza GJ. Laser treatment of warts and other epidermal and dermal lesions. *Dermatol Clin.* 1997;15:487-506.
45. Kaufmann R, Hibst R. Pulsed erbium:YAG laser ablation in cutaneous surgery. *Lasers Surg Med.* 1996;19:324-330.
46. Fox JL. Pulsed dye laser eliminates stretch marks. *Cosmetic Dermatol.* 1997;10:51-53.
47. Alster TS. Laser treatment of hypertrophic scars, keloids, and striae. *Dermatol Clin.* 1997;15:419-429.
48. Zelickson BD, Mehregan DA, Wendelschfer-Crabb G, et al. Clinical and histologic evaluation of psoriatic plaques treated with a flashlamp pulsed dye laser. *J Am Acad Dermatol.* 1996;35:64-68.
49. Webster GF, Satur N, Goldman MP, et al. Treatment of recalcitrant warts using the pulsed dye laser. *Cutis.* 1995;56:230-232.
50. Schonemark MP, Raulin C. Treatment of xanthelasma palpebrarum with the pulsed dye laser. *Lasers Surg Med.* 1996;19:336-339.
51. Schonemark MP, Schmidt C. Treatment of sebaceous gland hyperplasia with the pulsed dye laser. *Lasers Surg Med.* 1997;21:313-316.
52. Fritsch C, Goerz G, Ruzicka T. Photodynamic therapy in dermatology. *Arch Dermatol.* 1998;134:207-214.