

# Primary Multiple Miliary Osteoma Cutis and Exogenous Ochronosis

Paul H. Bowman, MD, Augusta, Georgia

Jack L. Leshner, Jr, MD, Augusta, Georgia

## GOAL

To discuss a case of primary multiple miliary osteoma cutis (MMOC) and exogenous ochronosis

## OBJECTIVES

Upon completion of this activity, dermatologists and general practitioners should be able to:

1. Describe the clinical presentation of primary MMOC.
2. Contrast primary MMOC with the classic form of MMOC.
3. Identify the characteristics and cause of accompanying exogenous ochronosis.

## CME Test on page 119.

This article has been peer reviewed and approved by Michael Fisher, MD, Professor of Medicine, Albert Einstein College of Medicine. Review date: July 2001.

This activity has been planned and implemented in accordance with the Essentials and Standards of the Accreditation Council for Continuing Medical Education through the joint sponsorship of Albert Einstein College of Medicine and Quadrant HealthCom, Inc. The Albert Einstein College of Medicine is accredited by the

ACCME to provide continuing medical education for physicians.

Albert Einstein College of Medicine designates this educational activity for a maximum of 1.0 hour in category 1 credit toward the AMA Physician's Recognition Award. Each physician should claim only those hours of credit that he/she actually spent in the educational activity.

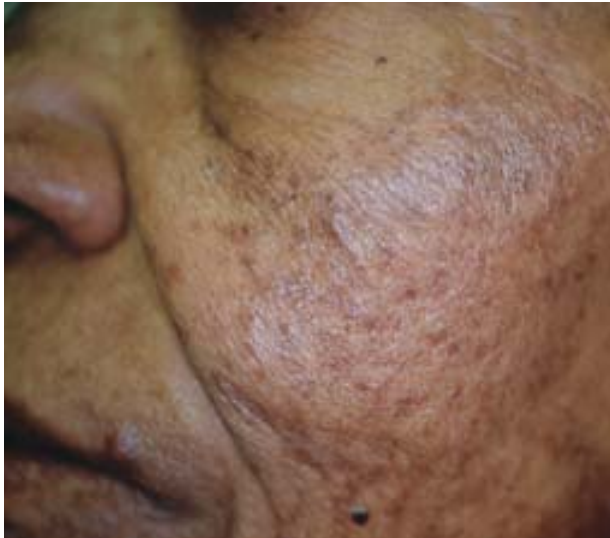This activity has been planned and produced in accordance with ACCME Essentials.

*Multiple miliary osteoma cutis (MMOC), a rare disorder characterized by the appearance of numerous bony nodules on the face, was initially classified as a consequence of severe, long-standing acne vulgaris. However, several cases have now been described in patients with no preceding history of acne or other inflammatory conditions. We report such a case of primary MMOC in a 75-year-old African American woman and highlight the differences between these conditions. We also note the incidental histologic*

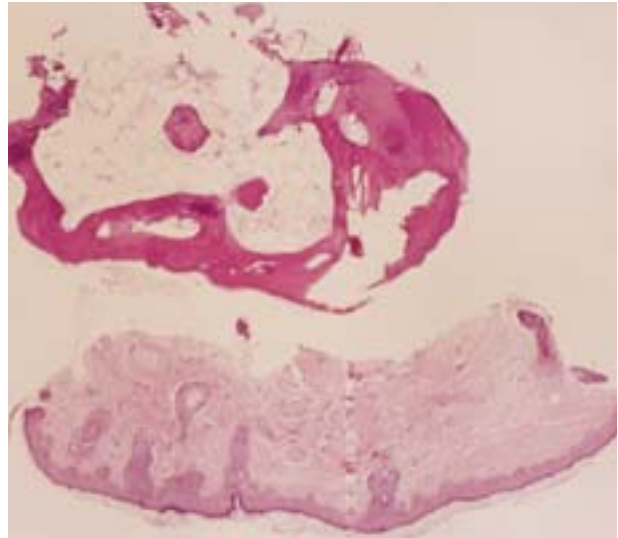
*finding of exogenous ochronosis, which, in our case, indicates the patient's use of hydroquinone-containing bleaching creams in an attempt to treat the disorder.*

The term *osteoma cutis* is derived from the Greek and Latin words for bone (*osteo*) and skin (*cutis*) and refers to true bone that forms within cutaneous tissue. Both primary and secondary forms exist, the latter being defined by the presence of tumors (eg, pilomatricomas, chondroid syringomas, epidermal cysts) or inflammatory conditions (eg, acne vulgaris, dermatomyositis, scleroderma) that subsequently develop areas of ossification. Primary cutaneous ossification is more rare and has been reported to occur in both localized

Drs. Bowman and Leshner are from the Medical College of Georgia, Augusta. Dr. Bowman is Chief Resident in Dermatology. Dr. Leshner is Professor and Chief, Section of Dermatology. Reprints: Jack L. Leshner, Medical College of Georgia, Section of Dermatology, 1004 Chafee Ave, Augusta, GA 30912.



**Figure 1.** Numerous small, firm, yellowish papulonodules present on the forehead, cheeks, and chin. Many of the lesions had associated hyperpigmentation.



**Figure 2.** Histologically, each lesion contained a spherical nodule of bone in the reticular dermis, with a central marrow cavity (H&E, original magnification  $\times 4$ ).

(nodules, plaques) and generalized (Albright's hereditary osteodystrophy, progressive osseous heteroplasia) forms.<sup>1</sup> We present our clinical and histologic findings in a case of primary multiple miliary osteoma cutis (MMOC) in an older woman.

### Case Report

A 75-year-old African American woman presented with a 3-year history of yellowish lesions on her face. They were not itchy or painful but were accumulating to the point of being cosmetically troublesome. Her medical history was significant only for hypothyroidism, which had been controlled with levothyroxine replacement therapy. The patient denied any history of arthritis, antecedent lesions, acne vulgaris, or trauma to her face. She had used several over-the-counter topical acne medications and bleaching creams without any improvement. On examination, she had numerous discrete, 2- to 3-mm, firm, yellowish papulonodules on her forehead, cheeks, and chin, many with surrounding areas of hyperpigmentation (Figure 1).

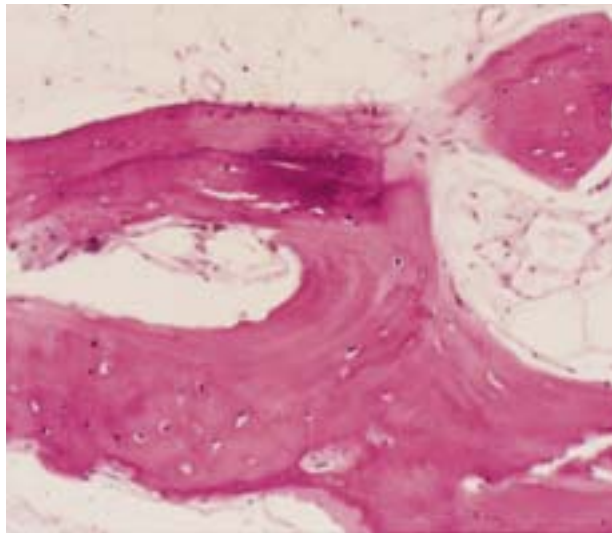
Several lesions were removed by 3-mm punch biopsy for histologic examination. Each specimen revealed a solitary spherical piece of bone in the reticular dermis (Figure 2). There was no evidence of any inflammation, association with adnexal structures, or other neoplasm. Each piece of bone had a central marrow cavity, complete with numerous blood vessels and adipocytes. Higher magnification (Figure 3) revealed numerous osteocytes, haversian canals, osteoblasts laying down osteoid and multinucleated osteoclasts resorbing bone, and

signs of active bone remodeling. In several specimens stained with hematoxylin and eosin (H&E), we also discovered collections of homogenous yellow-brown pigment in the upper dermis, directly above the bony nodule (Figure 4).

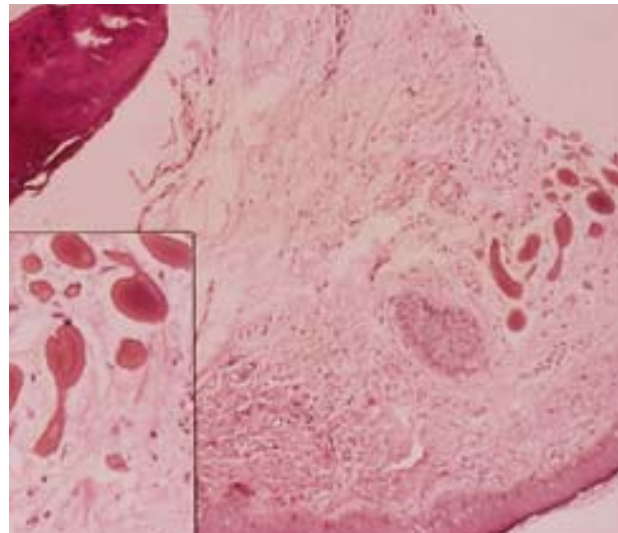
All laboratory results were normal, including complete blood count, serum calcium, phosphorus, alkaline phosphatase, calcitonin, 25-hydroxy vitamin D, and 1,25-dihydroxy vitamin D. Cutaneous calcifications were not evident on plain radiographs of the head and neck. After removing several of the larger lesions using a 3-mm punch biopsy, we began topical treatment with adapalene gel daily. The patient reported improvement in hyperpigmentation after several months using this therapy.

### Comment

MMOC is a rare condition that was first described by Virchow<sup>2</sup> in 1864 in a patient with multiple bony nodules on the face. The condition is usually asymptomatic but can become disfiguring as large numbers of lesions accumulate. Two variants of MMOC are now recognized.<sup>3</sup> The classic form, categorized as a type of secondary cutaneous ossification (developing subsequent to inflammation or tumors), presents in young women in their 20s and 30s with a long history of facial acne vulgaris. However, 15 cases of primary MMOC have now been reported.<sup>3,7</sup> In contrast to the classic form, primary MMOC presents in older women (50s to 70s) with no history of acne or other inflammatory dermatosis (Table 1).



**Figure 3.** Higher magnification of Figure 2 reveals osteocytes and haversian canals (osteoblasts and multinucleated osteoclasts)(H&E, original magnification  $\times 20$ ).



**Figure 4.** In several specimens, collections of homogeneous yellow-brown pigment were seen overlying the bony nodule (H&E, original magnification  $\times 10$ , inset  $\times 20$ ).

Table 1.

### Comparison of Primary MMOC and Classic (Secondary) MMOC\*

	Primary MMOC	Classic (Secondary) MMOC
Average age, y	63	35
History	No preceding acne or inflammatory dermatosis	Preceding acne vulgaris
Etiology	Hamartomatous vs metaplastic ossification	Dystrophic ossification
Incidence	Very rare (15 cases reported)	Rare

\*MMOC indicates multiple miliary osteoma cutis.

As shown in our case, lesions of primary MMOC are composed of true bone tissue that is undergoing active remodeling. The pathogenesis is unclear and may involve differentiation of ectopic embryologic nests of mesenchymal cells into osteoblasts (hamartoma) or stimulation of dermal fibroblasts to become osteoblasts (metaplasia).<sup>7</sup>

Treatment is difficult and usually involves individual removal of the bony nodules. This can be done using a scalpel or punch biopsy instrument; dermabrasion<sup>8</sup> and ablation with carbon dioxide or

Erbium:YAG lasers<sup>5,6</sup> also has been proven to be useful in treating this condition. Tetracycline double labeling has shown the bony lesions of MMOC to have high rates of internal remodeling; however, treatment using systemic etidronate disodium (a synthetic diphosphonate and inhibitor of bone metabolism) has not been helpful.<sup>9</sup> Topical tretinoin has been reported to be effective through gradual transepidermal elimination of more superficial lesions.<sup>10</sup> Our patient has reported subjective improvement using adapalene gel for a period of 6 months.

An interesting incidental histologic finding in our patient was the presence of collections of homogenous yellow-brown pigment in the upper dermis, directly above bony nodules (Figure 4). This represents exogenous ochronosis, so named for the yellow to light brown (ochre) microscopic granules. In this condition, topical hydroquinone (which must have been present in the over-the-counter preparations applied by our patient) causes localized inhibition of homogentisic acid oxidase and subsequent deposition of homogentisic acid polymers around collagen fibers in the dermis. Hydroquinone-induced exogenous ochronosis has been treated with the carbon dioxide laser in the past.<sup>11</sup>

Our case of primary MMOC is distinguished from classically described MMOC by the absence of any preexisting acne, neoplasm, or other conditions. The incidental finding of exogenous ochronosis was an interesting histologic clue that our patient had used hydroquinone-containing bleaching creams to try to treat the disorder.

## REFERENCES

1. Ragsdale BD. Tumors of fatty, muscular, and osseous tissue. In: Elder D, Elenitsas R, Jaworsky C, et al, eds. *Lever's Histopathology of the Skin*. 8th ed. Philadelphia, Pa: Lippincott-Raven; 1997:933-975.
2. Virchow R. Die Krankhaften Geschwülste. Vol 2. Berlin, Germany: Hirschwald; 1864:103. Cited by: Hopkins JG. Multiple miliary osteomas of the skin. *Arch Dermatol Syphilol*. 1928;18:706-715.
3. Gfesser M, Worret WI, Hein R, et al. Multiple primary miliary osteoma cutis. *Arch Dermatol*. 1998;134:641-643.
4. Novak C, Siller G, Wood D. Idiopathic multiple miliary osteomas of the face. *Austral J Dermatol*. 1998;39:109-111.
5. Ochsendorf FR, Kaufmann R. Erbium:YAG laser-assisted treatment of miliary osteoma cutis. *Br J Dermatol*. 1998;138:371-372.
6. Hughes PS. Multiple miliary osteomas of the face ablated with the Erbium:YAG laser. *Arch Dermatol*. 1999;135:378-380.
7. Baginski DJ, Arpey CJ. Management of multiple miliary osteoma cutis. *Dermatol Surg*. 1999;25:233-235.
8. Fulton J. Dermabrasion-loo-punch technique for the treatment of acne-induced osteoma cutis. *J Dermatol Surg Oncol*. 1987;13:655-659.
9. Goldminz D, Greenberg RD. Multiple miliary osteoma cutis. *J Am Acad Dermatol*. 1991;24:878-881.
10. Moritz DL, Elewski B. Pigmented postacne osteoma cutis in a patient treated with minocycline. *J Am Acad Dermatol*. 1991;24:851-853.
11. Diven D. Hydroquinone-induced localized exogenous ochronosis treated with dermabrasion and CO<sub>2</sub> laser. *J Dermatol Surg Oncol*. 1990;16:1018-1022.

### DISCLAIMER

The opinions expressed herein are those of the authors and do not necessarily represent the views of the sponsor or its publisher. Please review complete prescribing information of specific drugs or combination of drugs, including indications, contraindications, warnings, and adverse effects before administering pharmacologic therapy to patients.

### FACULTY DISCLOSURE

The Faculty Disclosure Policy of the College of Medicine requires that faculty participating in a CME activity disclose to the audience any relationship with a pharmaceutical or equipment company that might pose a potential, apparent, or real conflict of interest with regard to their contribution to the program. It is required by the Accreditation Council for Continuing Medical Education that each author of a CME article disclose to the participants any discussion of an unlabeled use of a commercial product or device or an investigational use not yet approved by the Food and Drug Administration. Drs. Bowman and Leshner report no conflict of interest. Dr. Fisher reports no conflict of interest.