

What's Eating You? *Echidnophaga gallinacea* (The Sticktight Flea)

COL Dirk M. Elston, MC, USA, San Antonio, Texas

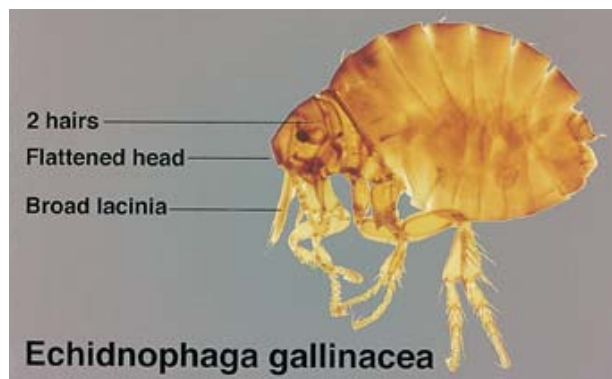
Identifying Features

All fleas have laterally compressed bodies and large hind legs. *Echidnophaga gallinacea*, the sticktight flea (Figure), is a combless flea (lacking the genal and pronotal combs present in dog and cat fleas) with no pleural rod. (A pleural rod above the second set of legs is a feature of *Xenopsylla* fleas.) The head is flattened anteriorly, and 2 pairs of setae (hairs) are present behind the antennae. The laciniae (stiletto-shaped cutting extensions of the maxilla) are exceptionally broad and coarsely serrated. This adaptation is probably related to the flea's ability to "stick tight" to its host. The last leg segment has 3 thick and 1 smaller pair of setae.

The sticktight flea is a poultry flea that also can be found on wild animals and domestic pets.¹⁻³ *E gallinacea* is a ubiquitous flea with worldwide distribution. It has been noted to be the most common flea on dogs in areas of South Africa,⁴ and it is also a common flea on dogs and cats in parts of Florida.^{1,5} *E gallinacea* is found on mammals as diverse as cottontailed rabbits in New Mexico⁶ and rodents in Angola.⁷ It is a vector for plague and murine typhus and serves as an intermediate host of the dog tapeworm (*Diphylidium caninum*).

Adverse Reactions

Flea bites present as tense, tumid, intensely pruritic papules, vesicles, and excoriated papules on the exposed areas of the lower extremities, forearms, and hands. The sites of lesions correspond to areas exposed while handling infested animals and exposed areas within "jumping height" for fleas on carpets and furniture. Bullous lesions are not uncommon. Sticktight fleas have a greater tendency than most other fleas to remain on an incidental



Sticktight fleas have prominent laciniae.

host for a prolonged period while feeding. Patients, therefore, may be more likely to notice the flea.

Histologic Analysis

Histologically, flea bites are characterized by a wedge-shaped, perivascular, dermal infiltrate. Eosinophils are commonly present around vessels and within vesicles and bullae.

REFERENCES

1. Harman DW, Halliwell RE, Greiner EC. Flea species from dogs and cats in north-central Florida. *Vet Parasitol.* 1987;23:135-140.
2. Kalkofen UP, Greenberg J. *Echidnophaga gallinacea* infestation in dogs. *J Am Vet Med Assoc.* 1974;165:447-448.
3. Patrick MJ, Harrison RL. Fleas on gray foxes in New Mexico. *J Med Entomol.* 1995;32:201-204.
4. Rautenback GH, Boomker J, de Villiers IL. A descriptive study of the canine population in a rural town in southern Africa. *J South Afr Vet Assoc.* 1991;62:158-162.
5. Beard CB, Butler JF, Hall DW. Prevalence and biology of endosymbionts of fleas (Siphonaptera: Pulicidae) from dogs and cats in Alachua County Florida. *J Med Entomol.* 1990;27:1050-1061.
6. Pfaffenberger GS, Valencia VB. Ectoparasites of sympatric cottontails (*Sylvilagus audubonii* Nelson) and jack rabbits (*Lepus californicus* Mearns) from the high plains of Eastern New Mexico. *J Parasitol.* 1988;74:842-846.
7. Linardi PM, Gomes AF, Botelho JR, et al. Some ectoparasites of commensal rodents from Huambo, Angola. *J Med Entomol.* 1994;31:754-756.

Dr. Elston is from the Department of Dermatology, Brooke Army Medical Center, San Antonio, Texas.

The opinions expressed are those of the author and should not be construed as official or as representing those of the Army Medical Department, the United States Air Force, or the Department of Defense.

Reprints: COL Dirk M. Elston, MC, USA, Department of Dermatology (MCHE-DD), Brooke Army Medical Center, 3851 Roger Brooke Dr, Fort Sam Houston, TX 78134-6200 (e-mail: dirk.elston@cen.amedd.army.mil).