

Cutaneous Malignant Fibrous Histiocytoma With the Characteristics of Different Variants

Eiichi Kakizoe, MD; Fukuko Kakizoe, MD; Kenji Kakizoe, MD; Hideki Okunishi, MD, PhD

We report the case of a 50-year-old woman with cutaneous malignant fibrous histiocytoma (MFH) on the right hypogastric region. A purplish-red blood-filled tumor, approximately 40 mm in diameter, was detected on the region. A histopathologic analysis of the excised tumor showed that it extended from the upper dermis to the subcutaneous tissue over the fascia and, furthermore, that a variety of cells, from highly atypical spindle shaped to histiocytelike, were embedded in the collagenous stroma without forming a capsule. The storiform pattern was not significant. In addition, an area occupied primarily by multinucleated giant cells and rich in vascular components was observed in the deep portion of the tumor that came into contact with the bloody contents. Based on these findings, the patient was diagnosed as having a cutaneous MFH exhibiting the characteristics of different variants.

Malignant fibrous histiocytoma (MFH) was first reported as malignant fibrous xanthoma by O'Brien and Stout.¹ However, the term MFH currently is used because this undifferentiated tumor is composed mostly of fibroblastlike and histiocytelike cells.² Although MFH is the most common form of adult soft tissue sarcomas, relatively few cases have been reported arising on the skin.³⁻⁵ In addition, MFH can be classified under several variants based on its clinical and histopathologic characteristics.⁶ We report a case of cutaneous MFH exhibiting the characteristics of 3 different variants.

Case Report

A 50-year-old Japanese woman presented with a dome-shaped tumor on the hypogastric region. She had noticed a small fingertip-sized hard nodule on the region over the last 6 months. Because of a lack of any subjective symptoms such as pain, the patient did not seek medical attention. Subsequently, the tumor increased in size, and it changed from flesh-toned to red. The patient's medical history and that of her family's were unremarkable.

The findings from the physical examination revealed a dome-shaped tumor of approximately 40 mm in diameter on the right hypogastric region (Figure 1). The surface of the skin appeared purplish red and relatively smooth, and the tumor was soft and elastic to the touch. Whereas the tumor adhered strongly to the surface of the skin, it barely adhered to the underlying tissue. Regional lymph nodes were not palpable. Clinical features suggested a soft tissue tumor. The entire tumor was excised—along with surrounding fatty tissue—down to the fascia, with 20-mm wide surgical margins; the tumor was not fused to the fascia. The surface of the tumor that was in contact with the fatty tissue appeared grayish white and capsulated. When an incision was made, slightly viscous liquid consisting primarily of blood was discharged. The intramural surface was irregular and granulated.

A histopathologic assessment revealed that the tumor extended from the upper dermis beneath the intact epidermis to the subcutaneous tissue over the fascia. Pleomorphic cells, atypical spindle cells to histiocytelike cells rich in slightly eosinophilic cytoplasm, proliferated, and frequent mitoses were found between the superficial and middle regions of the tumor (Figure 2). Various atypical cells were embedded in the collagenous stroma without forming a clear capsule, and no pronounced storiform pattern was noted. On the other hand, an area primarily occupied by multinucleated, osteoclast-type

Drs. E. Kakizoe, F. Kakizoe, and K. Kakizoe are from the Kakizoe Clinic of Dermatology, Kurume, Japan. Drs. Okunishi and E. Kakizoe are from the Department of Pharmacology, Shimane Medical University, Izumo, Japan.
Reprints: Eiichi Kakizoe, MD, Department of Pharmacology, Shimane Medical University, 89-1 Enya-cho, Izumo, Shimane 693-8501, Japan (e-mail: phamcL26@shimane-med.ac.jp).

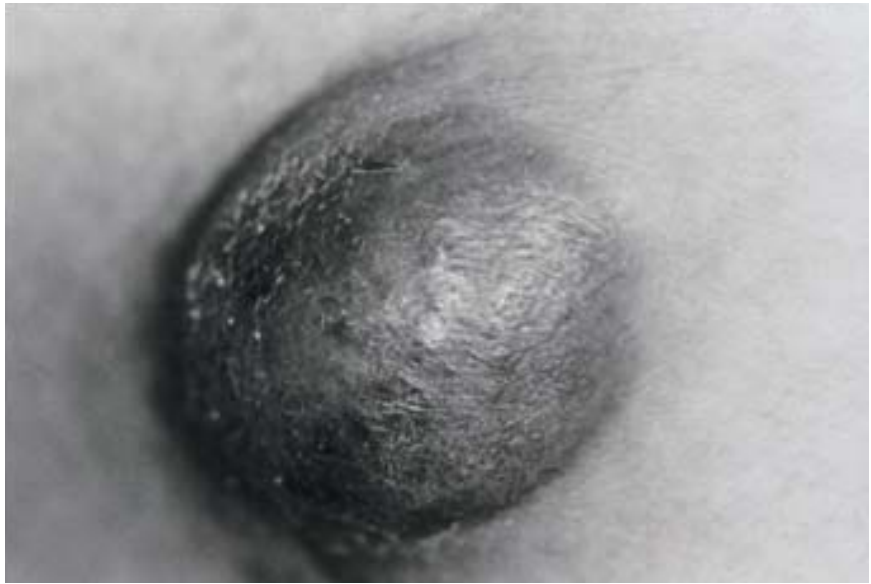

Figure 1. A purplish-red dome-shaped tumor on the right hypogastric region.

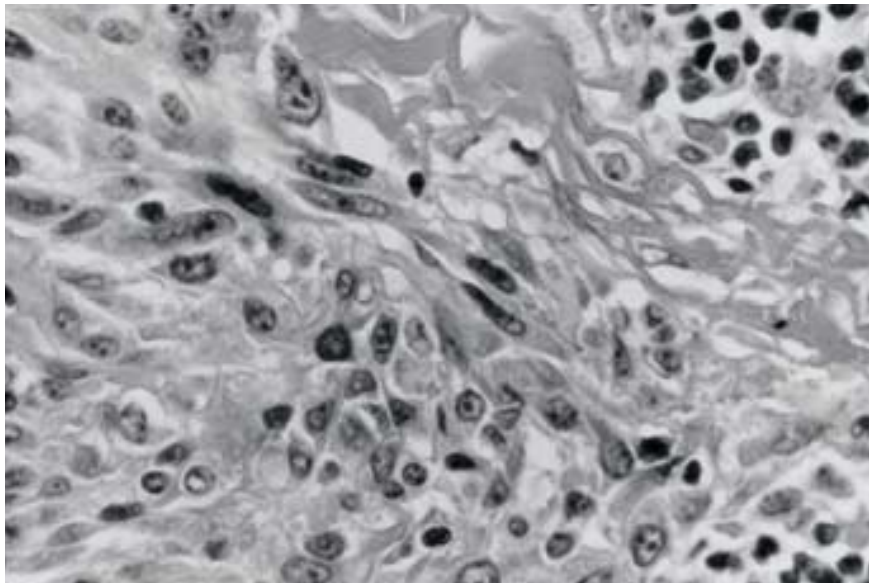


Figure 2. The superficial and middle region of the tumor with spindle-like and histiocytelike malignant cells embedded in the collagenous stroma (H&E, original magnification $\times 200$).

giant cells was observed in a deep region of the tumor facing the cavity that contained the bloody contents (Figure 3). In addition, an area where proliferating vessels and corpuscular components were particularly evident was observed in a deep region of the tumor (Figure 4). The results of immunohistochemical analyses were negative for S-100 protein, desmins, cytokeratins, and α -smooth muscle actin.

Despite the above findings, biochemical tests on serum and general tumor examinations did not reveal any abnormalities, including immunologic dysfunction.

Comment

The present case involves a patient with a dermal and subcutaneous tumor. Results of hematoxylin-

eosin stains showed that the structural cells of the tumor were embedded in the stroma without forming a capsule. Because the tumor showed malignant cells with a widely divergent range of characteristics, it was concluded to be a pleomorphic malignant tumor.^{7,8} No clear signs of differentiation with epithelial or muscular tissue were observed, and the findings from the immunohistologic examination were negative, thus eliminating the possibility of epithelial or muscular tumor. Although dermatofibrosarcoma protuberans was considered,⁹ the storiform pattern was not pronounced and did not cover the entire tumor. Furthermore, because the tumor was highly pleomorphic, the patient was diagnosed as having

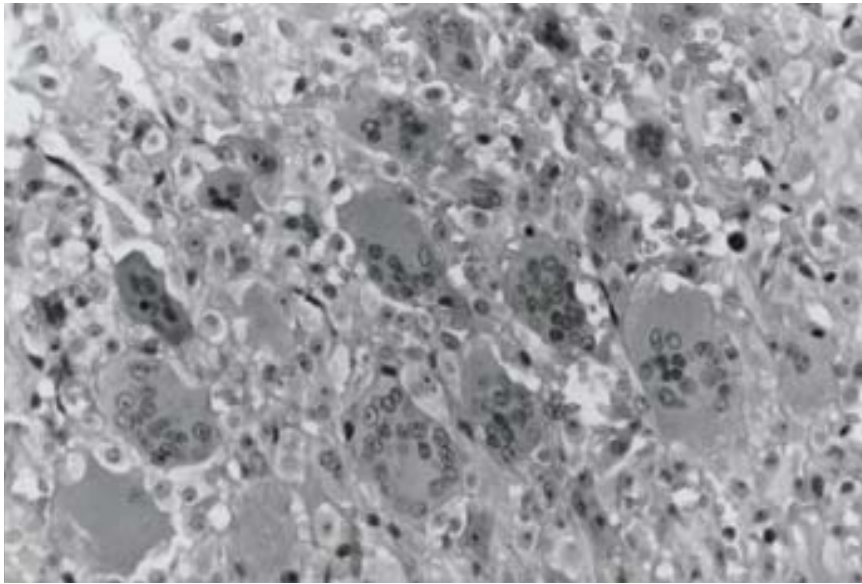


Figure 3. A deep region of the tumor where multinucleated giant cells account for most cellular components (H&E, original magnification $\times 100$).

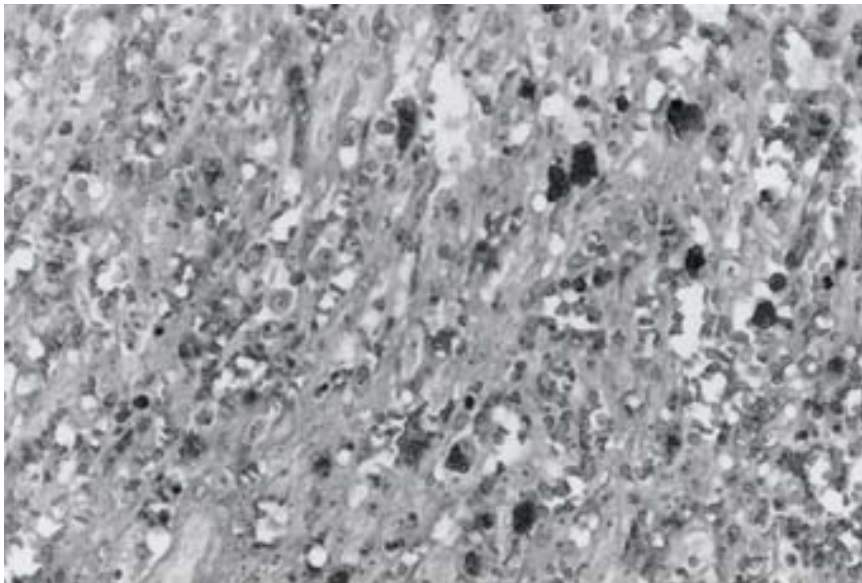


Figure 4. A deep region of the tumor rich in vascular and corpuscular components (H&E, original magnification $\times 100$).

cutaneous MFH. It is known that MFH includes the following subtypes or variants: storiform-pleomorphic, myxoid, giant cell, inflammatory types, and angiomatoid fibrous histiocytoma.⁶ In our patient, fibroblastlike and histiocytelike cells coexisted between the superficial and middle layers, thus strongly suggesting a storiform-pleomorphic subtype in the region.¹⁰ However, in a deep region of the tumor, multinucleated giant cells were noticeable, and an area occupied primarily by multinucleated cells rich in cytoplasm with similar size nuclei was noted. These findings are characteristic of the giant cell type.¹¹ In addition, the tumor resembled a capsulated bloody cyst that reached as far as the subcutaneous tissue, and an

area with pronounced vascularization was observed histopathologically, all of which were characteristic of an angiomatoid fibrous histiocytoma.^{12,13}

Based on these clinical and histopathologic findings, the tumor was diagnosed as cutaneous MFH, with the characteristics of different variants. Furthermore, the patient also had a unique form of the tumor, exhibiting the characteristics associated with angiomatoid fibrous histiocytoma, a disease that normally affects young people.

REFERENCES

1. O'Brien JE, Stout AP. Malignant fibrous xanthomas. *Cancer*. 1964;17:1445-1458.

Malignant Fibrous Histiocytoma

2. Weiss SW, Enzinger FM. Malignant fibrous histiocytoma: an analysis of 200 cases. *Cancer*. 1978;41:2250-2266.
3. Kearney MM, Soule EH, Ivins JC. Malignant fibrous histiocytoma. *Cancer*. 1980;45:167-178.
4. Berth-Jones J, Fletcher A, Graham-Brown R. Cutaneous malignant fibrous histiocytoma: a rare but serious malignancy. *Acta Derm Venereol*. 1990;70:254-256.
5. Ichikawa E, Asano S, Okabe S, et al. A case of cutaneous malignant fibrous histiocytoma. *J Dermatol*. 1996;23:535-538.
6. Heenan PJ. Tumors of the fibrous tissue involving the skin. In: Elder D, Elenitsas R, Jaworsky C, et al, eds. *Lever's Histopathology of the Skin*. 8th ed. Philadelphia, Pa: Lippincott-Raven; 1997:847-887.
7. Fu YS, Gabbiani G, Kaye GI, et al. Malignant soft tissue tumors of probable histiocytic origin (malignant fibrous histiocytomas): general considerations and electron microscopic and tissue culture studies. *Cancer*. 1975;35:176-198.
8. Hardy TJ, An T, Brown PW, et al. Postirradiation sarcoma (malignant fibrous histiocytoma) of axilla. *Cancer*. 1978;42:118-124.
9. Murphy GF, Elder DE. Fibrohistiocytic tumors. In: Rosai J, Sobin LH, eds. *Non-Melanotic Tumors of the Skin*. Washington, DC: Armed Forces Institute of Pathology; 1991:223-236.
10. Weiss SW. Malignant fibrous histiocytoma: a reaffirmation. *Am J Surg Pathol*. 1982;6:773-784.
11. Guccion JG, Enzinger FM. Malignant giant cell tumor of soft parts: an analysis of 32 cases. *Cancer*. 1972;29:1518-1529.
12. Enzinger FM. Angiomatoid malignant fibrous histiocytoma: a distinct fibrohistiocytic tumor of children and young adults simulating a vascular neoplasm. *Cancer*. 1979;44:2147-2157.
13. Grossman LD, White RR 4th, Arber DA. Angiomatoid fibrous histiocytoma. *Ann Plast Surg*. 1996;36:649-651.