

# Centrifugal Lipodystrophy Presenting With Serpiginous Erythema and Alopecia

Yoshitaka Hagari, MD; Akiko Ikehara, MD; Kiyofumi Nuno, MD; Motoyuki Mihara, MD

*We describe serpiginous erythema with alopecia developing on the scalp of a 10-year-old boy during follow-up of centrifugal lipodystrophy. Because the clinical and histopathologic features of these lesions were identical to those of centrifugal lipodystrophy, we conclude that involvement of a hairy region by this disorder could cause alopecia and that the hair loss might be an indirect effect of interstitial inflammatory infiltrates around the hair follicles and in the subcutaneous fat.*

**C**entrifugal lipodystrophy (lipodystrophia centrifugalis abdominalis infantilis) is a rare disorder seen mainly in children. This disease affects the subcutaneous fat of the trunk and is characterized by a centrifugal extension of lesions with an erythematous border and a depression of the involved skin because of loss of fatty tissue.<sup>1-3</sup> Previously, we reported an unusual case of centrifugal lipodystrophy of the face on a 4-year-old boy.<sup>4</sup> In this patient, the initial lesion appeared on the face, then extended downward to the upper trunk. This created an emaciated facies and depression of the affected skin, simulating progressive lipodystrophy (partial lipodystrophy), as well as serpiginous erythema at the advancing border, a condition that is typical of centrifugal lipodystrophy.<sup>4</sup> In this report, we describe an additional peculiar manifestation of this disorder not previously described, which was observed during the follow-up of this patient.

## Case Report

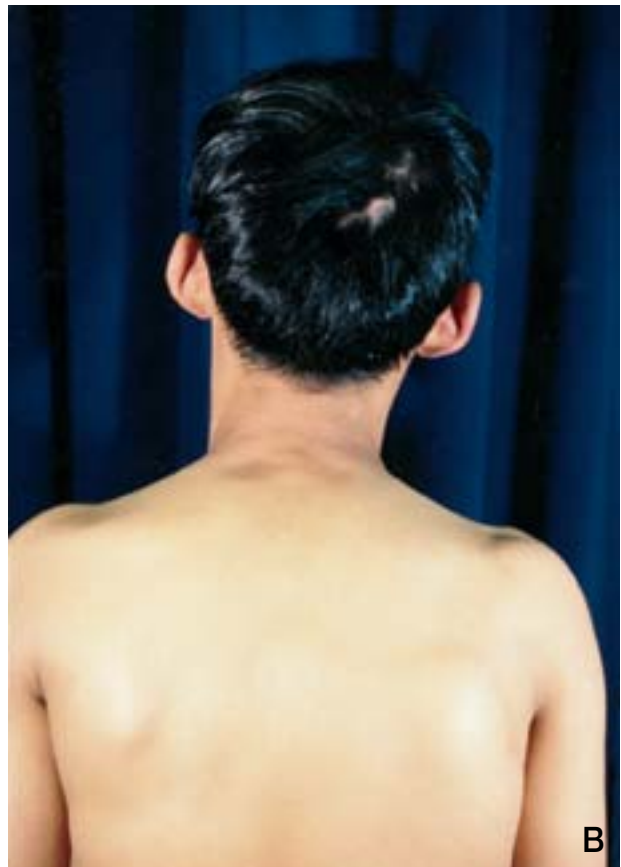
In April 1997, 6 years after the previous consultation, the 10-year-old boy again was referred to our

hospital for serpiginous erythema with alopecia on the scalp. His mother reported that the serpiginous erythema on the trunk had stopped extending and faded gradually 2 years after the previous consultation. Two weeks earlier, however, she noticed the erythema with alopecia on his scalp. The boy's mental and physical development had been otherwise uneventful.

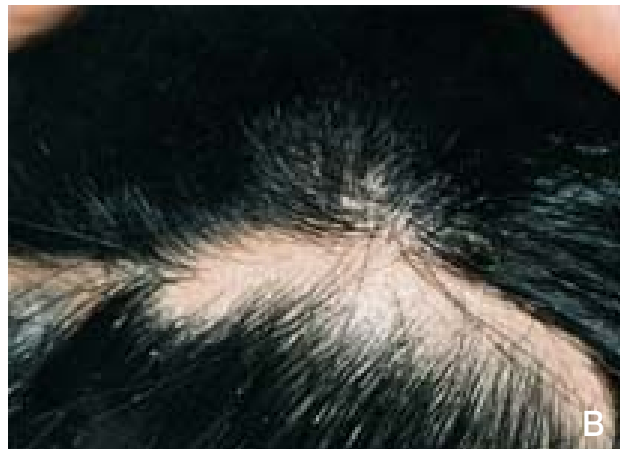
On physical examination, the patient was 153.5 cm in height and 47.5 kg in weight and still showed an emaciated facies (Figure 1A). Serpiginous erythema on the upper trunk, which had been observed on the previous consultation, had disappeared completely, leaving a depression of the involved area covered by normal-appearing skin (Figure 1B). On the scalp, serpiginous dull-pink erythema with alopecia and small amounts of fine scales, measuring approximately 1 cm in width, extended from the forehead to the right parietal region (Figure 2). The portion of serpiginous erythema on the forehead was inconspicuous and adjacent to the depressed lesion above the right eyebrow observed during a previous consultation when the patient was 20 months old.<sup>4</sup> Biopsy results of the scalp lesion indicated that inflammatory cell infiltrates—mainly in the upper portion of fatty tissue and sparsely in the dermis—were composed of lymphocytes, histiocytes, and a few plasma cells. These inflammatory cell infiltrates tended to condense around the hair follicles or eccrine glands but did not enter the hair follicles (Figure 3). The patient was treated once a month with a local triamcinolone acetonide injection into the scalp lesion. Although the lesion had almost healed—with regrowth of hair and slight residual depression of the skin without scarring—after 3 to 4 injections, erythema on the forehead became prominent (Figure 4); a similar serpiginous erythema with alopecia developed in the left temporal region adjacent to the previously affected site in the parietal region. Thereafter, new lesions on the scalp

---

Drs. Hagari, Ikehara, and Mihara are from the Department of Dermatology, Faculty of Medicine, Tottori University, Yonago, Japan. Dr. Nuno is from the Dermatologic Clinic, Kurayoshi, Japan. Reprints: Yoshitaka Hagari, MD, Department of Dermatology, Faculty of Medicine, Tottori University, 36-1 Nishi-machi, Yonago, 683-8504, Japan (e-mail: yohagari@grape.med.tottori-u.ac.jp).



**Figure 1.** An emaciated facies (A) and depression of the skin on the upper trunk (B).



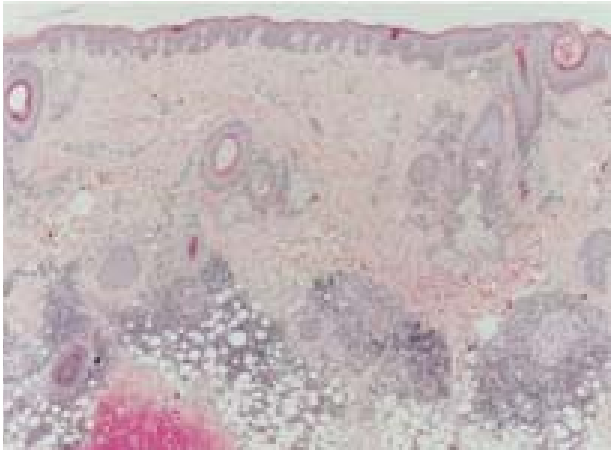
**Figure 2.** Serpiginous erythema with alopecia extends from the forehead to the right parietal region (A). A close-up view (B). Small amounts of fine scales are visible.

developed; these lesions seemed to start as erythema, becoming associated with alopecia soon thereafter.

**Comment**

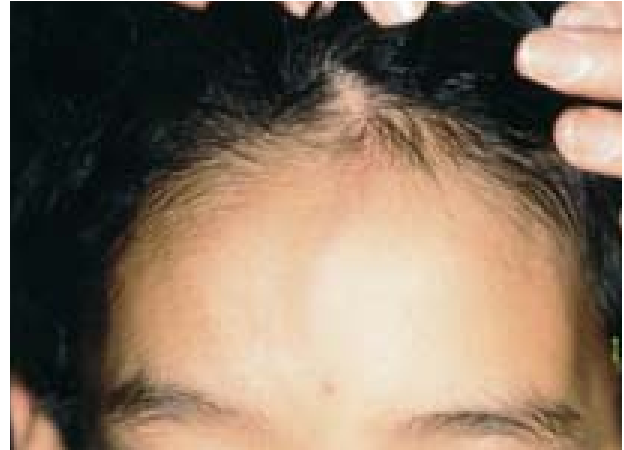Because the features (serpiginous configuration of the lesion, inflammatory cell infiltrates in fatty

tissue, and depression of the healed lesion) were identical to those of centrifugal lipodystrophy,<sup>1-3</sup> we considered these new lesions to be a further manifestation of this disorder. The observed alopecia was nonscarring. Although the involved area left a depression of the skin due to the loss of fatty



**Figure 3.** Histology of a biopsy taken from the scalp lesion. Inflammatory cell infiltrates composed of lymphocytes, histiocytes, and a few plasma cells in the upper part of the fatty tissue. The infiltrate tends to condense around the adnexal structures but does not enter the hair follicles (H&E, original magnification  $\times 25$ ).

tissue, the overlying skin appeared normal, and regrowth of hair occurred as the lesions healed. A manifestation such as the involvement of the scalp and face has not been observed previously, except in this patient. Based on histopathologic findings, we conclude that involvement of a hairy region by this disease could cause alopecia and that the hair loss might be an indirect effect caused by interstitial inflammatory cell infiltrates rather than a direct attack on the hair follicles. Treatment with local injections of corticosteroid may have been beneficial but did not seem to prevent the extension of the disease.



**Figure 4.** Erythema on the forehead became prominent after treatment of the scalp lesion.

## REFERENCES

1. Imamura S, Yamada M, Ikeda T. Lipodystrophia centrifugalis abdominalis infantilis. *Arch Dermatol.* 1971;104:291-298.
2. Imamura S, Yamada M, Yamamoto K, et al. Lipodystrophia centrifugalis abdominalis infantilis. *Hautarzt.* 1979;30:360-364.
3. Imamura S, Yamada M, Yamamoto K. Lipodystrophia centrifugalis abdominalis infantilis: a follow-up study. *J Am Acad Dermatol.* 1984;11:203-209.
4. Hagari Y, Sasaoka R, Nishiura S, et al. Centrifugal lipodystrophy of the face mimicking progressive lipodystrophy. *Br J Dermatol.* 1992;127:407-410.