

Aquatic Antagonists: *Catalaphyllia jardinei* Sting

Joseph W. Burnett, MD; Richard Pfau, MD



Figure 1. The green color of the tentacles and base of *Catalaphyllia* is seen in the animal located in the upper mid third of the photograph.

Catalaphyllia jardinei is a blue-green soft coral whose red-violet tipped tentacles have made it a very colorful, popular animal prized by amateur aquarists (Figure 1). Its normal habitat is the Indo-Pacific area from Seychelles through Vanuatu and from Northern Australia to Southern Japan. It is regarded as mildly venomous. However, to our knowledge, no reports exist on its sting's effects on man.

From the Department of Dermatology, University of Maryland, School of Medicine, Baltimore.

Reprints: Joseph W. Burnett, MD, 405 W Redwood St, 6th Floor, Baltimore, MD 21202-1703.

Case Report

A 48-year-old healthy woman was hand feeding aquarium animals when her arm came in contact with *Catalaphyllia* soft corals. She had immediate pain and an erythematous eruption. The following day, she was started on ciprofloxacin tablets, 500 mg twice daily. One week after the sting, multiple papules and small nodules, many arranged in a linear pattern, appeared on the mid third of the right volar forearm. Ciprofloxacin was discontinued, and therapy was initiated with minocycline 200 mg daily, ibuprofen 800 mg twice daily, and clobetasol cream applied topically under plastic occlusion for 2 hours twice daily. The minocycline



Figure 2. Multiple reddish-brown papules, some of which are in linear pattern, on the volar forearm.

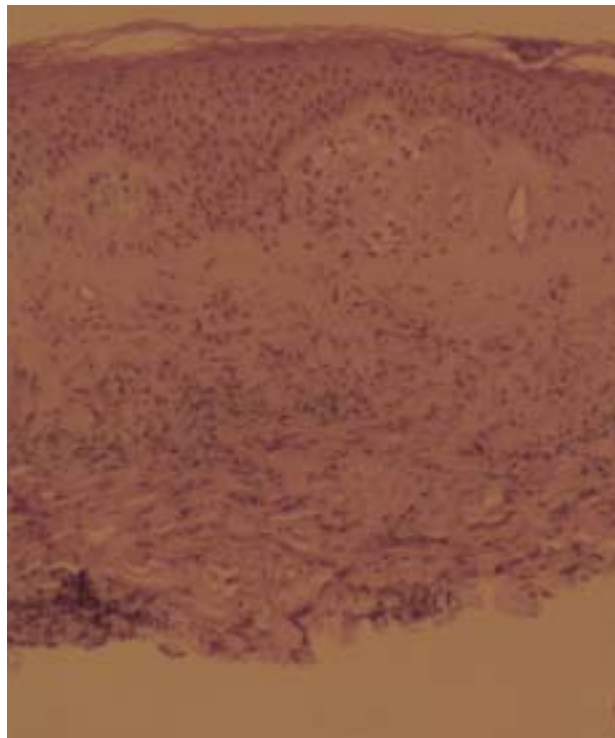


Figure 3. Biopsy obtained 21 days post-sting reveals degeneration of the papillary dermal collagen, with edema and a mixed inflammatory infiltrate (H&E, original magnification $\times 10$).

was administered for its effect on cellular migration, ibuprofen for inhibition of prostaglandins, and plastic occlusion for assistance with clobetasol penetration. The patient's itching diminished within 2 days.

Three weeks after the sting, the patient's eruption was more lichenoid and brownish-purple (Figure 2). Biopsy readings revealed focal epidermal necrosis with papillary dermal edema and degenerative changes. Mild dermal fibrosis with perivascular mononuclear cell inflammation, including eosinophil infiltration, also was detected. The dermal inflammatory infiltrate was T cell (CD 3+)(Figure 3). No significant B cells or Ki-1 cells were present. The eruption gradually diminished over the next 6 weeks. The above therapy was ineffective except for relieving pruritus.

This case report illustrates 2 points. First, a dramatically effective therapeutic program for coral stings is not presently available. Natural evolution of some of these eruptions requires many weeks. Second, *Catalaphyllia* corals are indeed venomous.

REFERENCE

1. Veron JEN. *Corals of Australia and the Indo-Pacific*. Honolulu, Hawaii: University of Hawaii Press; 1993.