

Acne Vulgaris, I: Pathogenesis and Diagnosis

Steve S. Oberemok, MD; Alan R. Shalita, MD

GOAL

To describe the pathogenic mechanisms associated with acne and the variable clinical presentation

OBJECTIVES

Upon completion of this activity, dermatologists and general practitioners should be able to:

1. Discuss the morphologic changes that give rise to acne lesions.
2. Outline the role of sebum and *Propionibacterium acnes* in the production of acne.
3. Describe the clinical presentation, range of lesion severity, and differential diagnosis for acne.

CME Test on page 97.

This article has been peer reviewed and approved by Michael Fisher, MD, Professor of Medicine, Albert Einstein College of Medicine. Review date: July 2002.

This activity has been planned and implemented in accordance with the Essential Areas and Policies of the Accreditation Council for Continuing Medical Education through the joint sponsorship of Albert Einstein College of Medicine and Quadrant HealthCom, Inc. The Albert Einstein College of

Medicine is accredited by the ACCME to provide continuing medical education for physicians.

Albert Einstein College of Medicine designates this educational activity for a maximum of 1.0 hour in category 1 credit toward the AMA Physician's Recognition Award. Each physician should claim only those hours of credit that he/she actually spent in the educational activity.

This activity has been planned and produced in accordance with ACCME Essentials.

Acne vulgaris is a chronic inflammatory disease of the pilosebaceous units. It is a pleomorphic disorder with multifactorial pathogenesis. The many expressions of acne rarely present a diagnostic challenge, but correct classification of acne is crucial in choosing the appropriate therapies. Although previous research has provided a better understanding of the pathogenic factors, there is still a great deal to be learned.

From the Department of Dermatology, State University of New York Downstate Medical Center, Brooklyn. Dr. Oberemok is a Clinical Assistant Instructor. Dr. Shalita is a Distinguished Teaching Professor and Chairman.

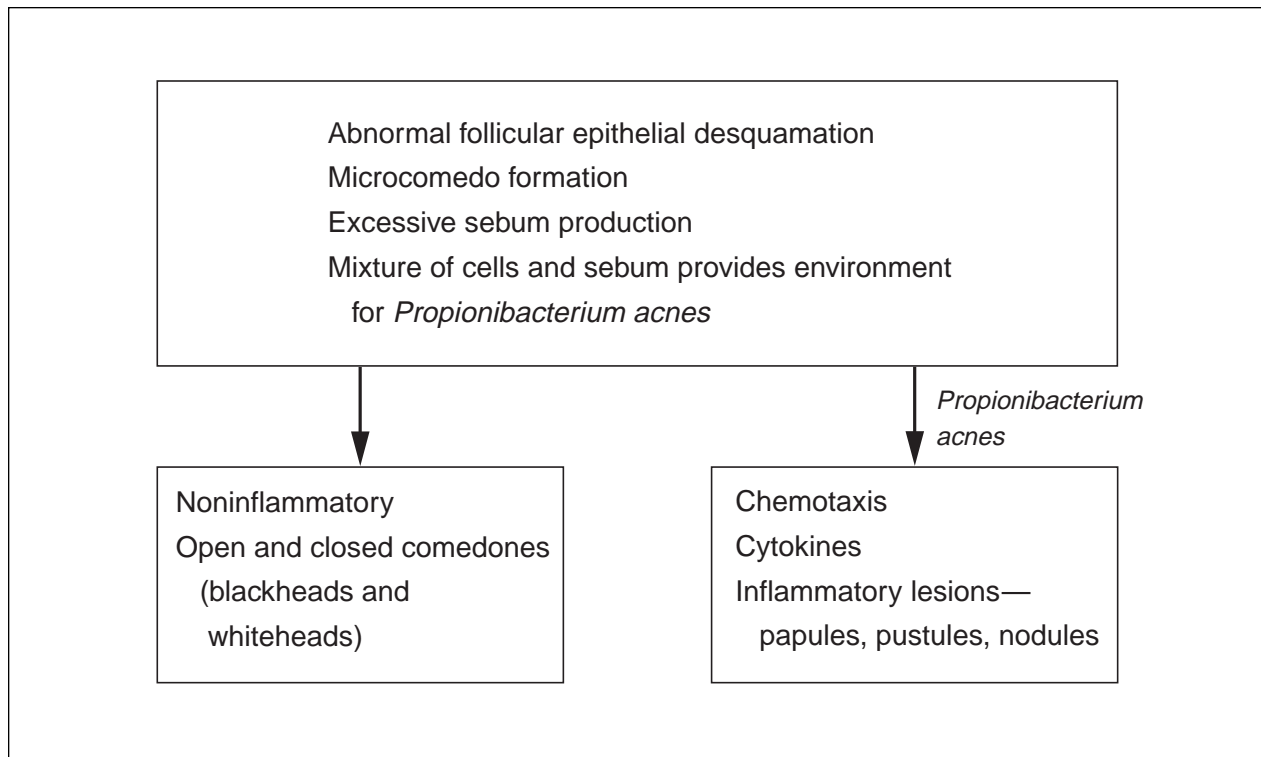
Reprints: Alan R. Shalita, MD, Department of Dermatology, SUNY Downstate Medical Center, 450 Clarkson Ave, Brooklyn, NY 11203 (e-mail: ashalita@downstate.edu).

Perspective

Acne vulgaris, the most common skin disorder, affects virtually all individuals at least once. Incidence peaks in 18-year-olds, but substantial numbers of 20- to 40-year-olds also develop the disease. The effects of acne should not be underestimated. It can persist for years; produce disfigurement and permanent scarring; and have significant psychosocial consequences, including diminished self-esteem, embarrassment, social withdrawal, depression, and unemployment.¹ The extent and severity of these effects underline the importance of providing adequate therapy, which produces satisfactory results in most cases.

Pathogenesis

Acne is a complex disease with multifactorial pathogenesis and considerable variation in severity. Thus,



Pathogenesis of acne.

therapy can be directed at multiple factors and modified for individual patients.

Acne is a disorder of the sebaceous follicles, which are special pilosebaceous units located on the face, neck, chest, upper back, and upper arms. These units consist of relatively large sebaceous glands associated with small hair follicles. Acne arises from the interaction of 4 factors:

1. Comedogenesis—sebaceous follicle obstruction arising from increased cohesiveness of follicular epithelial cells, hyperproliferation of ductal keratinocytes, or both.²
2. Excessive sebum production caused by androgenic stimulation of sebaceous glands at or around adrenarche or later.
3. Proliferation of *Propionibacterium acnes*, an anaerobic diphtheroid that populates sebaceous follicles and is a normal constituent of cutaneous flora. *P. acnes* produces chemotactic factors and proinflammatory mediators that may lead to inflammation.³
4. Inflammation is a direct or indirect result of *P. acnes* proliferation. Follicular rupture and extension of inflammation into the dermis result in formation of the inflammatory lesions of acne vulgaris—papules, pustules, and nodules (Figure).

The earliest morphologic change or primary pathologic event is sebaceous follicle obstruction giving rise to microcomedones, precursors of all acne lesions. The mechanism of microcomedo formation is unclear, but reasonable evidence supports hyperproliferation of ductal keratinocytes.⁴ This mechanism was identified immunohistochemically using a monoclonal antibody to Ki-67, a nuclear marker expressed by actively cycling cells. In subjects with acne but not in normal control subjects, Ki-67 showed increased labeling by basal keratinocytes of the follicular epithelium of both comedones and microcomedones. In addition, suprabasal expression of keratin K16, a marker of hyperproliferation and abnormal differentiation, occurs in ductal keratinocytes of acne lesions.

Some “normal follicles” of acne-prone skin also may show overexpression of Ki-67 and K16⁵—which underscores the need for topical treatment of all acne-prone skin that shows early clear evidence of microcomedo formation. Increased keratinocyte cohesion as a primary event has been questioned as a factor in comedogenesis, as there is no clear evidence of abnormality of ductal desmosomes.

Some evidence, however, shows that the composition of sebaceous lipids becomes altered and that such alteration may cause follicular cells to adhere to one another more. Increases in free fatty

acids,⁶ squalene, and squalene oxide⁷ and a decrease in sebaceous linoleic acid could all trigger abnormal cohesion of cells in sebaceous follicles. According to another hypothesis, hyperkeratosis in sebaceous follicles is the result of a local deficiency of vitamin A.⁸ Androgens may have an important role in controlling ductal hyperproliferation either directly or indirectly through stimulation of sebaceous glands. More recently, cytokines proved to have an important controlling effect.⁹ In the *in vitro* model used in the study, comedones were produced under the influence of interleukin-1 α (IL-1 α), and this process can be inhibited by adding IL-1 α receptor antagonist to the system.

Sebum, the lipid-rich secretion of sebaceous glands, has a central role in the pathogenesis of acne and provides a growth medium for *P. acnes*. Enlargement of sebaceous glands and increased production of sebum are stimulated by increased production of adrenal and gonadal androgens—a change preceding clinical onset of puberty. Interestingly, sebum production rates are inversely proportional to the concentration of linoleic acid in skin-surface lipids; subjects with acne and normal control subjects are marked by a difference in sebum composition. According to a current explanation of acne pathogenesis, follicular epithelium differentiation may be influenced by a lower concentration of linoleate in sebum. The relation between acne and sebum overproduction has long been acknowledged, as has been the correlation between acne severity and sebum production rates.

Androgenic hormones control sebaceous gland secretions. Testosterone is the main circulating androgen. In women, however, the adrenal gland and its main androgens dehydroepiandrosterone (DHEA) and sulfate salt of DHEA (DHEAS) have important roles in androgen control of sebaceous glands. Testosterone is assumed to convert to dihydrotestosterone, which then binds to a high-affinity specific cytoplasmic receptor protein that is transported to the cell nucleus where the DNA-driven events occur.

Even though free testosterone levels may be elevated in women with acne compared with women without acne, actual values fall within the normal range.¹⁰ Given the efficacy of antiandrogen treatments, however, the sebaceous glands of patients with acne are likely to be hypersensitive to androgens. In men, the association of acne and high androgen concentrations is less consistent.¹¹ To be sure, there are no reports of conclusive reproducible studies supporting a consistent mechanism involved in sebum overproduction as it relates to androgen production.

P. acnes is the predominant organism in sebaceous follicles, where it grows in a relatively anaerobic lipid-rich environment of microcomedones. *P. acnes* counts on the skin of teenage subjects with acne and *P. acnes* counts on the skin of age-matched control subjects differ significantly. *P. acnes*, however, is not essential for comedogenesis, as was confirmed by research involving children with early acne. *P. acnes* produces an extracellular lipase that hydrolyzes sebum triglycerides to glycerol, used by the bacteria as a growth substrate, and to free fatty acids, which may possess comedogenic and/or proinflammatory qualities.¹² Inhibition of bacterial lipase alone, however, failed to improve inflammatory acne.¹³ The initial event in acne inflammation may be the disruption of follicular epithelium, which allows microcomedones to come into contact with inflammatory systems. Early, apparently intact comedones contain neutrophils, which suggests that soluble inflammatory factors may diffuse from comedones. Lee et al¹⁴ found that *P. acnes* also produced high-molecular-weight chemotactic factors, one of which was the lipase itself. In subsequent studies, *P. acnes* may have simultaneously produced both high- and low-molecular-weight chemoattractants, and the majority of neutrophil chemotactic activity in *P. acnes* culture supernatant was less than 2 kd.¹⁵ In another study, the role of cellular immunity in initiation of acne lesions was explored.¹⁶ Not surprisingly, CD4⁺ lymphocytes were prominent in early acne lesions. This finding, which is consistent with elevation of anti-*P. acnes* cellular immunity in patients with severe acne, is significant, as antibody titers to *P. acnes* parallel acne severity.¹⁷ These antibodies are required to activate the classic pathway of complement. On the other hand, the alternative pathway is activated by *P. acnes* wall carbohydrate.

The comedo also may contain other inflammatory factors. Allaker and Greenman¹⁸ showed that *P. acnes* produces compounds that engage in histaminelike activity. Ingham et al¹⁹ found significant levels of IL-1–like activity and tumor necrosis factor–like molecules in a majority of open comedones. The origins and actual structures of these factors have yet to be defined.

When neutrophils arrive at the comedo, *P. acnes*, already opsonized by C3b or immunoglobulins, is ingested. This interaction releases intracellular hydrolytic enzymes but does not kill *P. acnes*. These lysosomal enzymes degrade the follicular epithelium, which leads to rupture of the follicular wall and extrusion of follicular epithelium, sebaceous lipids, *P. acnes*, and hair into the dermis, which in turn causes inflammation. Several *P. acnes*–produced

Acne Classification by Severity of Inflammatory Lesions

Severity	Papules/Pustules	Nodules
Mild	Few to several	None
Moderate	Several to many	Few to several
Severe	Numerous to extensive	Many

extracellular enzymes (eg, hyaluronidase, protease) also may be important in inflammation.²⁰

Clearly, the immune response in acne is not protective. Inappropriately activated immunity seems likely to lead to propagation of inflammatory lesions and subsequent scarring.

Diagnosis

Acne is generally limited to areas where sebaceous glands are largest and most abundant—the face, neck, chest, upper back, and upper arms. Individual lesions are centered about sebaceous follicles.

Correct classification of lesion type (Table) is essential for choosing the most effective therapy. At the 1990 Consensus Conference on Acne Classification,²¹ a global evaluation of lesions and their complications (eg, drainage, hemorrhage, pain) was proposed. Psychosocial impact, failure to respond to previous therapies, and occupational disability are 3 additional factors used in grading acne.

Noninflammatory acne lesions are either closed or open comedones. Acne that manifests as non-inflammatory lesions is not classified *severe* unless the number, size, and extent of such lesions are so overwhelming as to warrant the designation.

Inflammatory acne lesions are papules, pustules, and nodules. These lesions are classified as papulopustular, nodular, or both. The severity grades assigned (mild, moderate, severe) are based on lesion count approximations (Table).

The term *cystic acne* should probably be abandoned, as there are no true cysts in acne (on rare occasion, these cysts develop as a residual effect of acne lesion healing). The term *severe acne* may be applied if ongoing scarring or persistent lesion-drainage is involved or if sinus tracts are present. In addition, the most destructive forms of acne—acne conglobata, acne fulminans, follicular occlusion triad—are classified as *very severe*.

Differential Diagnosis

Although most acne diagnoses present no difficulties, certain conditions or overlapping conditions may be confusing. Differential diagnosis may be stimulated by this noninclusive list: rosacea, ulerythema ophryogenes, gram-negative folliculitis, steatocystoma multiplex, steroid acne, drug eruptions, perioral dermatitis, iododermas, verruca vulgaris, verruca plana, bromodermas, syringomas, sarcoidosis, trichoepitheliomas, follicular mucinosis, angiofibromas, infectious folliculitis, and keratosis pilaris.

REFERENCES

1. Koo J. The psychological impact of acne: patient's perceptions. *J Am Acad Dermatol*. 1995;32:S26-S30.
2. Plewig G, Fulton JE, Kligman AM. Cellular dynamics of comedo formation in acne vulgaris. *Arch Dermatol Forsch*. 1971;242:12-29.
3. Vowels BR, Yang S, Leyden JJ. Induction of proinflammatory cytokines by a soluble factor of *P acnes*: implications for chronic inflammatory acne. *Infect Immun*. 1995;63:3158-3165.
4. Knaggs HE, Holland DB, Morris C, et al. Quantification of cellular proliferation in acne using the monoclonal antibody Ki-67. *J Soc Invest Dermatol*. 1994;102:89-92.
5. Cunliffe WJ, Holland DB, Clark SM, et al. Comedogenesis: some new aetiological, clinical and therapeutic strategies. *Br J Dermatol*. 2000;142:1084-1091.
6. Kligman AM, Katz AC. Pathogenesis of acne vulgaris. *Arch Dermatol*. 1968;98:53-57.
7. Motoyoshi K. Enhanced comedo formation in rabbit ear skin by squalene and oleic acid peroxides. *Br J Dermatol*. 1983;109:191-198.
8. Kealey T. Hypovitaminosis A of follicular duct as a cause of acne vulgaris [letter]. *Lancet*. 1988;2:449.
9. Guy R, Greem MR, Kealey T. Modeling acne in vitro. *J Invest Dermatol*. 1996;106:176-182.

10. Thiboutot D, Gilliland K, Light J, et al. Androgen metabolism in sebaceous glands from subjects with and without acne. *Arch Dermatol*. 1999;135:1041-1045.
11. Pochi PE, Strauss JS, Rao RS, et al. Plasma testosterone excretion and sebum production in males with acne vulgaris. *J Clin Endocrinol Metab*. 1965;51:287-291.
12. Shalita AR, Lee WL. Inflammatory acne. *Dermatol Clin*. 1983;1:361-364.
13. Weeks JG, McCarty L, Black T, et al. The inability of a bacterial lipase inhibitor to control acne vulgaris. *J Invest Dermatol*. 1977;69:236-243.
14. Lee WL, Shalita AR, Suntharalingam K, et al. Neutrophil chemotaxis by *Propionibacterium acnes* lipase and its inhibition. *Infect Immun*. 1982;35:71-78.
15. Webster GF, Leyden JJ. Characterization of serum-independent polymorphonuclear leukocyte chemotactic factors produced by *Propionibacterium acnes*. *Inflammation*. 1980;4:261-269.
16. Norris JFB, Cunliffe WJ. A histological and immunocytochemical study of early acne lesions. *Br J Dermatol*. 1988;118:651-659.
17. Puhvel SM, Barfatani M, Warnick M. Study of antibody levels to *Corynebacterium acnes*. *Arch Dermatol*. 1964;90:421-427.
18. Allaker RP, Greenman S. The production of inflammatory compounds by *Propionibacterium acnes* and other skin organisms. *Br J Dermatol*. 1987;117:175-183.
19. Ingham E, Eady EA, Goodwin CE, et al. Proinflammatory levels of IL-1-like bioactivity are present in the majority of open comedones in acne vulgaris. *J Invest Dermatol*. 1992;98:895-901.
20. Puhvel SM, Hoffman LK. The production of hyaluronidase by *Corynebacterium acnes*. *J Invest Dermatol*. 1972;58:66-70.
21. Report of the Consensus Conference on Acne Classification. *J Am Acad Dermatol*. 1991;24:495-500.

DISCLAIMER

The opinions expressed herein are those of the authors and do not necessarily represent the views of the sponsor or its publisher. Please review complete prescribing information of specific drugs or combination of drugs, including indications, contraindications, warnings, and adverse effects before administering pharmacologic therapy to patients.

FACULTY DISCLOSURE

The Faculty Disclosure Policy of the College of Medicine requires that faculty participating in a CME activity disclose to the audience any relationship with a pharmaceutical or equipment company that might pose a potential, apparent, or real conflict of interest with regard to their contribution to the program. It is required by the Accreditation Council for Continuing Medical Education that each author of a CME article disclose to the participants any discussion of an unlabeled use of a commercial product or device or an investigational use not yet approved by the Food and Drug Administration.

Dr. Oberemok reports no conflict of interest. Dr. Shalita is a consultant for Allergan, Inc; Dermik Laboratories; Medicis Pharmaceutical Corporation; and Stiefel Laboratories, Inc. He also has received research grants from and served on speakers bureaus for Allergan, Inc; Collagenx Pharmaceuticals, Inc; Connetics Corporation; Dermik Laboratories; Galderma Laboratories, LP; Medicis Pharmaceutical Corporation; and Stiefel Laboratories, Inc. Dr. Fisher reports no conflict of interest.