

# *Candida albicans* Intralesional Injection Immunotherapy of Warts

Robert J. Signore, DO

*Often, the treatment of verrucae is frustrating for both the physician and patient. Treatment may be painful, scarring, ineffective, and costly. The object of this study was to compare the clinical outcomes and safety of Candida albicans intralesional injection immunotherapy (CI) versus conventional wart treatment. The results of a prospective, nonrandomized, open-label, comparison study are presented. CI is a novel, simple, and inexpensive modality for the treatment of verruca vulgaris (VV), including the planar wart (PW) type. CI appears safe and well tolerated and is well suited for multiple warts on hands and fingers, PWs, and recalcitrant warts. Uninjected warts also may regress during CI. The new phenomenon of postimmunotherapy-revealed cicatrix (PIRC) is described. CI represents an off-label usage of Candida extract.*

The treatment of patients with multiple, recalcitrant, or recurrent verrucae continues to be a formidable task for both primary care physicians and dermatologists.<sup>1</sup> Treatment with currently available modalities, such as cryosurgery, laser surgery, electrosurgery, bleomycin, curettage, and topical acid application, is not always successful and may be associated with adverse effects, such as painful scars,<sup>2</sup> discomfort,<sup>3</sup> nerve damage,<sup>4</sup> and rarely, frostbite with subsequent loss of a toe.<sup>5</sup> Even when existing warts are successfully eradicated, patients may develop new warts in other areas. Thus, recalcitrant wart disease is often frustrating for the physician and patient.<sup>6</sup>

Contact immunotherapy of warts has been performed with dinitrochlorobenzene<sup>7</sup> (DNCB),

diphenylcyclopropanone (DCP), squaric acid dibutylester<sup>8</sup> (SADBE), poison oak, poison ivy,<sup>7</sup> and tuberculin jelly.<sup>9</sup> Autologous vaccine therapy of condyloma acuminatum<sup>10</sup> and common warts<sup>11</sup> has been reported. Direct injection of smallpox vaccine<sup>12</sup> into warts also has been described. The efficacy and recurrence rates of immunotherapy of condyloma acuminatum with intralesional interferon injection are comparable to other treatment modalities.<sup>13</sup>

However, the use of these immunotherapeutic agents has its drawbacks. DNCB is difficult to use<sup>7</sup> and has been shown to be mutagenic by the Ames test. Severe urticarial reaction to DCP therapy for alopecia areata has been reported.<sup>14</sup> In addition, an erythema multiforme–like reaction following DCP treatment of plane warts has been noted.<sup>15</sup> Pigmentary disturbance (dyschromia in confetti) has been reported in patients with alopecia areata treated with DCP.<sup>16</sup> Side effects of topical SADBE include acute contact dermatitis and persistent hypopigmentation.<sup>8</sup> The possibility for future contact with poison ivy makes this agent less than desirable.<sup>17</sup> Tuberculin jelly apparently is safer than DNCB.<sup>9</sup> However, it requires a long treatment period and a patient population in which tuberculin sensitivity is high. Subcutaneous injection of an autologous killed–virus vaccine obtained from wart tissue has been very effective in treating condyloma acuminatum.<sup>10</sup> There is concern, however, regarding the use of DNA viruses containing oncogenes.<sup>17</sup> Injection of smallpox vaccine into warts is associated with the risk of permanent scarring and severe systemic reaction, curtailing its usage.<sup>12,18</sup> Interferon therapy of condyloma acuminatum is not recommended for routine use because of inconvenience of administration, frequent office visits, and high frequency of systemic adverse effects.<sup>13</sup> Therefore, a safe, effective, simple, and inexpensive immunotherapeutic agent would be a welcome addition to the clinician's armamentarium.

Spontaneous clinical regression of warts is thought to occur as a result of cell-mediated immunity.<sup>19-23</sup> *Candida albicans* is the predominant pathogenic

From private practice in Tinley Park, Illinois.

The author has no commercial, proprietary, or financial interest in the products or companies described in this article.

Presented in part at the Summer Meeting of the American Academy of Dermatology, Anaheim, California, July 30, 2001.

Reprints: Robert J. Signore, DO, 17730 S Oak Park Ave, Suite C, Tinley Park, IL 60477.

yeast in the skin. Defense against *C albicans* primarily involves the delayed hypersensitivity immune system.<sup>24</sup> Delayed-type hypersensitivity to *C albicans* is present in 60% to 78% of healthy adults.<sup>25</sup> Therefore, intralesional injection of *C albicans* extract into a wart might elicit a host cell-mediated immune response capable of inducing wart regression. The results of a prospective, open-label, nonrandomized comparison study of *C albicans* intralesional injection immunotherapy (CI) and traditional wart therapy are presented in this study.

### Patients and Methods

This clinical investigation was done in accordance with the Declaration of Helsinki research guidelines.<sup>26</sup> Oral and written informed consents were obtained. Written consent was drawn up according to the American Medical Association Council on Ethical and Judicial Affairs Code of Medical Ethics (1998–1999 edition).

Two hundred seventy-seven nonrandomized patients with warts were treated in a private community-based dermatology office from December 17, 1998, to May 23, 2001. Patients were treated for verruca vulgaris (VV), plantar warts (PWs), flat warts, or condyloma acuminatum. One hundred patients received CI. One hundred seventy-seven patients received traditional treatment, most frequently consisting of liquid nitrogen cryosurgery, topical salicylic acid 17% in flexible collodion, and electrodesiccation and curettage. Less frequently used were topical in-office application of salicylic acid 30% podophyllum resin 10% in flexible collodion, salicylic acid 30% podophyllum resin 5% and cantharidin 1% in flexible collodion, salicylic acid 40% plaster (Mediplast®), warm water soaks, excision, topical retinoic acid (Retin-A®), retinol cream, imiquimod 5% cream (Aldara®), and podofilox topical solution 0.5% (Condylox®). Bleomycin injection and laser ablation were not used in this study. Inclusion criteria included patients 6 years and older. Exclusion criteria included patients who were pregnant or breast-feeding; those with uncontrolled urticaria, known active or recent yeast infection, uncontrolled asthma, known severe hypersensitivity to *C albicans*, or acute febrile illness; and those receiving concomitant treatment for warts by another physician. There was no treatment washout period before enrollment.

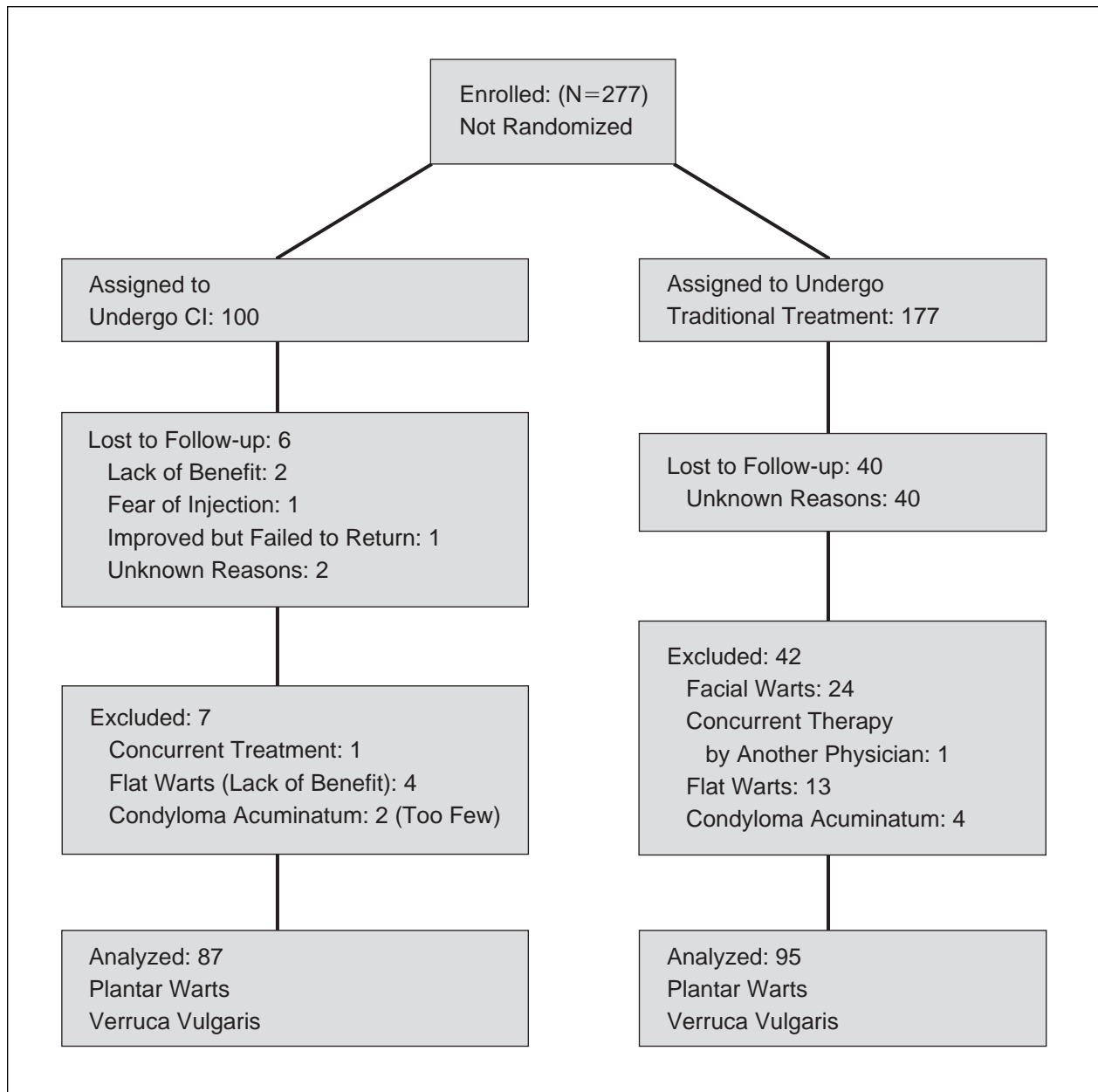
Beginning with CI patient 65, a scratch test was performed 15 minutes before the first CI treatment to identify patients with severe, immediate hypersensitivity to *C albicans*. The oldest, and usually the largest, wart (the “mother wart” [MW]) in CI

patients 1 through 5 was injected with 0.1 mL *C albicans* skin test antigen (CAST)(Candin®) diluted with 0.1 mL 1% plain lidocaine solution. The MW in CI patients 6 through 21 was injected with 0.1 mL undiluted CAST. The MW of CI patients 22 through 100 was injected with 0.1 mL *C albicans* allergenic extract (CAE [1:1000]). The warts were injected intralesionally, using a one-piece BD 1-mL U-100 insulin syringe with a 0.36×13-mm needle. The syringe was held parallel with the skin surface, and the needle was injected with the bevel facing upward. CI patients were instructed to wait in the office for 15 to 30 minutes after injection to observe for signs and symptoms of immediate hypersensitivity. CI patients were instructed to discontinue all other wart treatments during the study. Traditional treatment patients, however, were allowed to use more than one wart treatment concurrently, if prescribed by the clinical investigator. CI and traditional treatment patients were allowed to take their usual medications during the study period. CI patients were instructed to return in 2 days for a recheck of the injection site. Redness and tenderness to palpation at the injection site were assessed and recorded as either present or absent. CI patients 1 through 5, 6 through 21, and 22 through 100 were instructed to return for reassessment in 4 weeks, 6 weeks, and 8 weeks, respectively.

At follow-up visits, the MW was injected again if it was still present. If little or no clinical improvement was seen in the patients’ other warts, some patients received intralesional injection of one or more warts, in addition to MW injection. CI and traditional treatment patients received from 1 to 3 in-office treatment sessions. Total wart counts of CI patients were performed at office visits (excluding 2-day rechecks), except for CI patients with numerous flat warts. A mosaic wart was counted as one wart, regardless of size.

Complete clearing (CC) was defined as total resolution of all warts present at the beginning of the study. Partial clearing was defined as decrease in number and/or decrease in apparent size. No improvement was defined as no decrease in number and no decrease in apparent size. To be eligible for final data analysis, subjects were required to complete at least one office treatment session and one clinical follow-up examination and were allowed up to 3 office treatment sessions.

The Fisher exact test was used to analyze all parameters in Tables 1, 2, and 3, except age and number of warts, where the *t* test was used. STATA 7.0 software was used for the Fisher exact test. SAS software was used for logistic regression and *t* test.



**Figure 1.** *Candida albicans* intralesional injection immunotherapy (CI) versus traditional treatment of warts.

## Results

The flowchart (Figure 1) depicts the course of enrolled patients. Table 1 shows the outcome of patients treated for VV, including the plantar type. Of the 87 CI patients, 44 (51%) had complete clearing of all originally present warts, 35 (40%) had partial clearing, and 8 (9%) had no improvement. Fifty-one (59%) had CC of their initially injected wart (ie, MW) and 27 (31%) had clearing or improvement of uninjected warts. Nine of the 56 (16%) CI patients with multiple warts had CC

of all warts after just one wart was injected. Of the 87 CI patients, 39 (45%) were children aged 6 through 18 years. Of these children, 20 (51%) had CC, 16 (41%) had partial clearing, and 3 (8%) had no improvement (Figure 2). The follow-up period for CI patients ranged from 6 to 109 weeks. CI patients with VV and/or PWs received an average of 2.3 treatment sessions. The follow-up period for traditional treatment patients ranged from 1 to 102 weeks. Traditional treatment patients with VV and/or PWs received an average

Table 1.

**Outcome of Treatment in Patients With Plantar Warts and Verruca Vulgaris\*†**

No. of Patients	CI (n=87)	Traditional Treatment (n=95)
Complete clearing (%)	44 (51)	46 (48)
Partial clearing (%)	35 (40)	44 (46)
No improvement (%)	8 (9)	5 (5)

\*CI indicates *Candida albicans* intralesional injection immunotherapy.  
†P value for the Fisher exact test of no difference in outcome is 0.528.

of 1.6 treatment sessions. Findings from all CI patients who received scratch tests before immunotherapy were negative for immediate-type hypersensitivity to *Candida*.

A comparison of the clinical parameters of the patients with PWs and/or VV is shown in Table 2. The 2 patient groups were similar regarding sex, history of atopy, and wart duration. However, mean age of patients in the CI group was significantly lower than the traditional treatment group ( $P=.005$ ). Patients in the CI group also had a higher number of warts on average (mean of 4.6 vs 3.1 in the traditional treatment group,  $P=.016$ ) and were more likely to be recalcitrant to previous therapy ( $P<.001$ ). The percentage of patients with PWs in the CI group was greater than that in the traditional treatment group, but the difference was not significant ( $P=.071$ ). Adverse effects in subjects with PWs and/or VV are shown in Table 3.

The impact of these factors on treatment success (ie, CC) was examined further, using separate multivariate logistic regression analyses of the CI and traditional treatment groups. Surprisingly, no patient parameters predicted probability of CC in the CI group. Outcome of CI patients did not correlate with size of the injected wart, age, or history of atopy. However, clinical stigmata of atopy were not examined. While the final outcome of pediatric patients was virtually identical to that of the entire CI group (Figure 3), clinical resolution of warts occurred sooner in children.

Logistic regression of traditional treatment data revealed a significantly lower likelihood of CC among younger subjects ( $P$  for age = .011) and those with PWs ( $P=.037$ ). The number of warts was a negative predictor of CC when included as a continuous variable, but it was not significant ( $P=.066$ ). How-

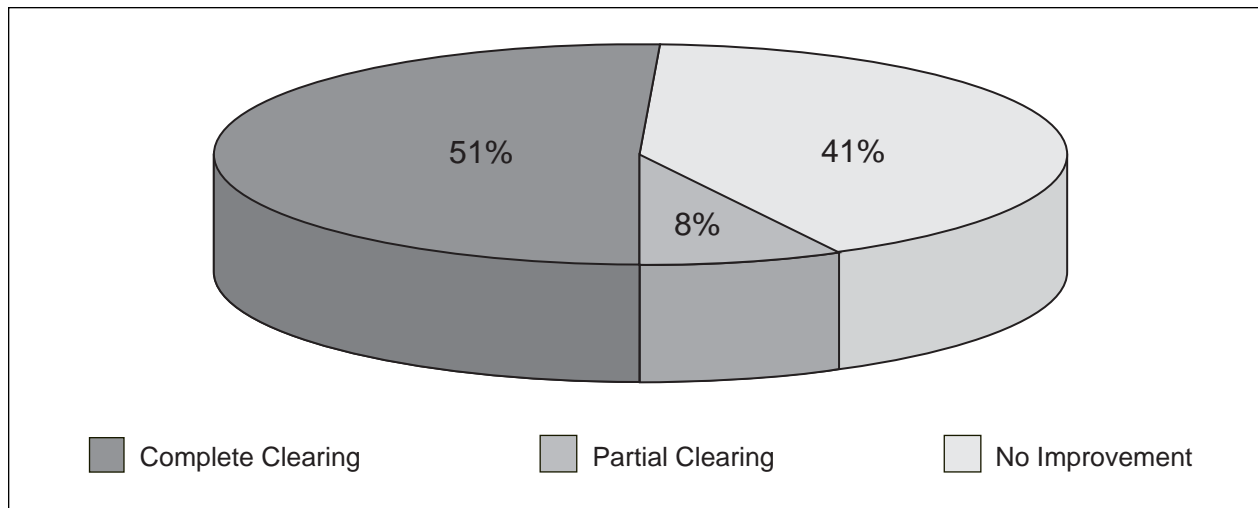
ever, when included as a set of categorical variables (1 wart, 2–4 warts,  $\geq 5$  warts), the number of warts was a significant predictor of outcome (ie, patients with 1 wart were much more likely to have CC in comparison to those with 2 or more).

In one case, a 10-year-old boy underwent CI for recalcitrant common warts on his knee of 2 years' duration. An incidental hemangioma, approximately 2 cm in diameter, was present several centimeters away from the CI injection site. According to the mother, the hemangioma had been present since early infancy. It had already involuted and stopped improving. Results of physical examination revealed an oval, purplish, fibrotic, flat plaque, consistent with the residual connective tissue remnant of a hemangioma. After 3 CI injection sessions, the hemangioma that had not been injected flattened and completely resolved, except for postinflammatory hyperpigmentation.

### Comment

In 1979, Harada<sup>27</sup> documented in the Japanese literature the efficacy of *Candida* vaccination in the treatment of warts. At the University of Minnesota, Bolton and Ricker<sup>28</sup> performed a double-blind, placebo-controlled study to demonstrate the efficacy of CI in the treatment of recalcitrant warts using CAE (1:100). This stronger concentration of *Candida* antigen was associated with rapid tissue sloughing.<sup>28</sup> However, Bolton's previous study using CAE (1:1000) yielded a 71% cure rate, with no significant side effects.<sup>28</sup>

In the present study, side effects were uncommon. Two CI patients exhibited the phenomenon of postimmunotherapy-revealed cicatrix (PIRC). One 13-year-old girl had multiple plantar scars, resulting from previous electrosurgery under general anesthe-



**Figure 2.** Outcome of *Candida albicans* intralesional injection immunotherapy in children aged 6 to 18 years (n=39).

Table 2.

**Patient Characteristics (Plantar Warts and Verruca Vulgaris)\*†**

No. of Patients	CI (n=87)	Traditional Treatment (n=95)	P
Sex, male (%)	35 (40)	42 (44)	.653
Age, mean, y	23.7	31.4	.005‡
History of atopy (%)	35 (40)	47 (49)	.233
Recalcitrant to previous therapy (%)	73 (84)	52 (55)	<.001‡
Wart duration ≥2 y (%)	33 (38)	28 (30)	.273
No. of warts, mean	4.6	3.1	.016‡
Patients with plantar warts (%)	30 (34)	21 (22)	.071

\*CI indicates *Candida albicans* intralesional injection immunotherapy.

†The Fisher exact test was used for all parameters except age and number of warts, for which the *t* test was used.

‡Significant.

sia by a general surgeon. Another 13-year-old girl had a single scar on her finger from a thermal burn sustained in early childhood. However, the scars from these 2 patients were completely obscured by their warts and were only visible after their warts resolved following CI. Fortunately, both patients volunteered detailed histories of their preceding scars. Nevertheless, clinicians should be aware of this PIRC phenomenon for medicolegal reasons. It would be prudent to document incidental disease or

history of previous treatments that may suggest the original source of PIRC.

No serious adverse effects occurred in the CI group (Table 3). Four patients reported pain and flu-like symptoms, which were short-lived. Two of these patients experienced flulike symptoms on their first treatment and the other 2 on their third treatment. According to the manufacturer's product information, immunotherapy should be administered with caution to patients receiving  $\beta$ -blocker therapy

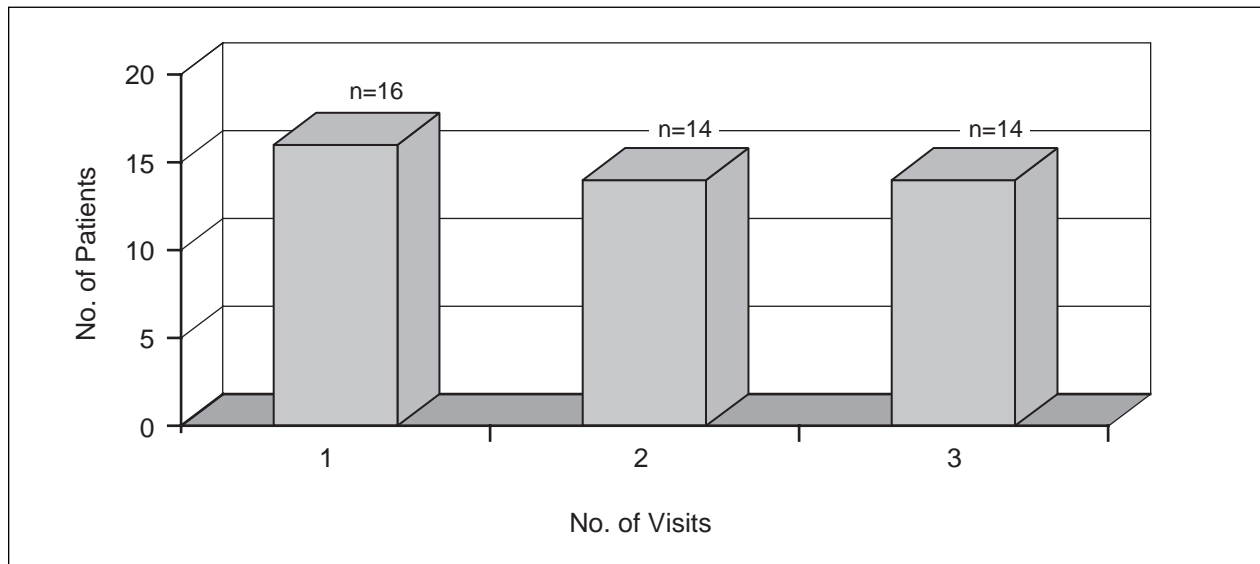
Table 3.

**Adverse Effects (Plantar Warts and Verruca Vulgaris)\***

Adverse Effect, No. of Patients (%)	CI (n=87)	Traditional Treatment (n=95)	P
Hypertrophic scar	0	9 (9)	.003†
Milia	1 (1)	0	.478
Chills, myalgia, or arthralgia	4 (5)	0	.05†
Headache	1 (1)	0	.478
Severe pain	2 (2)	0	.227
Tenderness for 1 wk	1 (1)	0	.478
Localized wheal at injection site	3 (3)	NA	NA
Digital edema	2 (2)	0	.227
Herpes zoster	1 (1)	0	.478

\*CI indicates *Candida albicans* intralesional injection immunotherapy; NA, not applicable.

†Significant using the Fisher exact test.



**Figure 3.** Number of patients receiving *Candida albicans* intralesional injection immunotherapy who achieved complete clearing (n=44) per number of treatment sessions needed.

because they may be unresponsive to epinephrine in the event of anaphylaxis.<sup>29</sup> No patients experienced scarring from CI. However, almost one third of the 31 traditional patients treated with electrodesiccation developed hypertrophic scars. One of these patients developed a flexion contracture of the finger as a result of his hypertrophic scar.

CAST is approved by the US Food and Drug Administration for use as a recall antigen for detecting delayed-type hypersensitivity to *C albicans* by intracutaneous (intralesional) testing.<sup>25</sup> CAE (1:1000) is FDA approved for the diagnosis and treatment of patients with immediate hypersensitivity allergy to *C albicans*.<sup>29</sup> There was no signifi-

cant difference in the outcomes between the first 13 PW and/or VV patients who were treated with CAST, and subsequent PW and/or VV patients who received CAE (1:1000). However, the cost of CAST is approximately 20 times higher than CAE (1:1000).

Results of logistic regression may have potential implications for choosing either traditional treatment or CI. Negative predictors of response to traditional treatment were younger patients, those with PWs, and those with multiple warts.

There are obvious limitations to an open non-randomized study, including selection bias, investigator bias, and patient bias. Spontaneous regression of warts cannot be ruled out. However, 35 of 74 (47%) CI patients with previously recalcitrant PWs and/or VV had CC. Furthermore, 11 of 44 (25%) of the patients with PWs and/or VV who experienced CC with CI had wart duration greater than or equal to 2 years, making spontaneous regression less likely. Nevertheless, this is the first study to compare the outcomes and adverse effects of CI with standard wart therapies other than liquid nitrogen cryosurgery.

It can be speculated that warts may produce one or more biologically active substances capable of local immunosuppression, allowing verrucae to escape attack by the cell-mediated immune system. Indeed, Freed and Eyres<sup>30</sup> reported the case of a 41-year-old woman with numerous recalcitrant common warts of 20 years' duration that contained a soluble factor that blocked local expression of cellular immunity without affecting systemic immune responsiveness. Perhaps warts produce increasing amounts of such blocking factors with longer duration. This might render them highly resistant to therapeutic intervention. Similarly, factors interfering with immunologic rejection of tumors also have been described.<sup>31</sup>

CI patient 18, a 10-year-old boy, was noted to have an involuted hemangioma, with residual connective tissue remnant adjacent to the injection site. During the course of CI, it regressed completely, despite not being injected directly. This may have been the result of spontaneous regression. However, CI may have potential for the treatment of infantile hemangiomas. Further studies are warranted.

The mechanism of action of CI is unknown. Presumably, intradermal injection of *C albicans* extract causes nonspecific inflammation that attracts a cell-mediated immune response, which then becomes active against human papillomavirus-infected keratinocytes. Four CI patients reported herein developed transient chills, myalgia, or arthralgia within 24 hours of injection, suggesting the possibility of

systemic cytokine release. In an open study of 55 patients treated for warts with either *Candida* or mumps injection immunotherapy, Johnson and colleagues<sup>32</sup> reported 6 subjects who experienced flu-like symptoms within 12 hours of treatment. All resolved by 24 hours, responding to nonsteroidal anti-inflammatory medications. Similarly, Phillips et al<sup>33</sup> reported transient flulike symptoms in 2 of 104 patients treated with *Candida* antigen injection. In the present study, only one CI patient declined further treatment because of flulike symptoms.

Thirty-nine of the 87 CI subjects (45%) were children ranging in age from 6 to 18 years. Surprisingly, *Candida* injections were well tolerated by most children. Many of these pediatric patients were quite embarrassed by their warts and thus very motivated to undergo CI. In the present study, the physician pinched up the surrounding skin immediately before injection to decrease pain perception. One patient used a eutectic mixture of lidocaine 2.5% and prilocaine 2.5% cream (EMLA<sup>®</sup>), and one patient applied ice before treatment to make the injection more tolerable. Injection of thin-skinned areas, such as the dorsal hand, was less painful than thick-skinned areas, such as the palms and soles.

## Conclusion

CI is a novel therapeutic approach for the treatment of PWs and VV; it is a simple, effective, and well-tolerated modality in selected patients. A significant difference in outcome was not detected between the CI and traditional treatment groups. Also, the CI group had significantly more recalcitrant patients, higher number of warts per patient, and younger patients. It is possible that CI might have shown clinical superiority in a more closely matched study. This new form of treatment appears helpful for patients with numerous warts and difficult-to-treat lesions, such as periungual warts and PWs. No scarring resulted from CI in any of the patients observed in this study. Also, CI is quite inexpensive. One treatment, consisting of 0.1 mL of CAE (1:1000), alcohol preparation pad, examination gloves, and insulin syringe, costs less than \$1. CI could be useful in areas of the world that cannot afford costly medical care.

Randomized controlled trials are needed to further assess the efficacy of CI and to determine optimum dosing and length of time between injections.<sup>34</sup> Immunohistochemical studies are needed to elucidate the mechanisms of action of CI. Studies comparing the efficacy of CI with intralesional bleomycin, SADBE contact immunotherapy, and laser ablation also would be useful to the clinician.

*Acknowledgments*—The author gratefully acknowledges Kurt D. Gillis, PhD, for statistical support and helpful comments regarding statistical analysis; Ms. Deborah A. Scheff for administrative excellence; Mss. Kristen A. Riley and Dawn E. Clesson for clinical support; and all referring physicians and participating patients.

CAE (1:1000) was purchased from Greer Laboratories, Inc., Lenoir, North Carolina.

## REFERENCES

- Rogers C, Gibney M, Siegfried E, et al. Cimetidine therapy for recalcitrant warts in adults: is it any better than placebo? *J Am Acad Dermatol.* 1999;41:123-127.
- Dover JS, Arndt KA, Geronemus RG, et al, eds. *Illustrated Cutaneous Laser Surgery: A Practitioner's Guide.* Norwalk, Conn: Appleton & Lange; 1990:36.
- Hurwitz S. Viral diseases of the skin. In: Hurwitz S. *Clinical Pediatric Dermatology.* Philadelphia, Pa: WB Saunders; 1981:247-253.
- Lowy DR, Androphy EJ. Warts. In: Freedberg IM, Eisen AZ, Wolff K, et al, eds. *Fitzpatrick's Dermatology in General Medicine.* 5th ed. New York, NY: McGraw-Hill; 1999:2484-2497.
- Matsumoto Y, Adachi A, Banno S, et al. Prominent hyperkeratotic plantar and palmar warts. *Cutis.* 1999;63:91-94.
- Bender ME. Concepts of wart regression. *Arch Dermatol.* 1986;122:644-647.
- Arndt KA. Warts. In: Arndt KA, Bernhardt MS. *Dermatologic Therapeutics With Essentials of Diagnosis.* 4th ed. Boston, Mass: Little Brown & Co Inc; 1989.
- Lee A, Mallory S. Contact immunotherapy with squaric acid dibutylester for the treatment of recalcitrant warts. *J Am Acad Dermatol.* 1999;41:595-599.
- Lahti A, Hannuksela M. Topical immunotherapy with tuberculin jelly for common warts. *Arch Dermatol Res.* 1982;273:153-154.
- Abcarian H, Sharon N. Long-term effectiveness of the immunotherapy of anal condyloma acuminatum. *Dis Colon Rectum.* 1982;25:648-651.
- Yurdakok M, Yurdakok K. Vaccine therapy of warts in children. *Turk J Pediatr.* 1985;27:87-94.
- Committee on Cutaneous Health and Cosmetics. Treatment of verrucae with smallpox vaccine. *JAMA.* 1968;206:117.
- Centers for Disease Control and Prevention. 1998 guidelines for treatment of sexually transmitted diseases. *MMWR Morb Mortal Wkly Rep.* 1998;47(RR-1):88-91.
- Alam M, Gross E, Savin R. Severe urticarial reaction to diphenylcyclopropanone therapy for alopecia areata. *J Am Acad Dermatol.* 1999;40:110-111.
- Puig L, Alegre M, Cuatrecasas M, et al. Erythema multiforme-like reaction following diphenylcyclopropanone treatment of plane warts. *Int J Dermatol.* 1994;33:201-203.
- van der Steen P, Happle R. 'Dyschromia in confetti' as a side effect of topical immunotherapy with diphenylcyclopropanone. *Arch Dermatol.* 1992;128:518-520.
- Bolton RA. Nongenital warts: classification and treatment options. *Am Fam Physician.* 1991;43:2049-2056.
- Allyn B. Treatment of verruca with vaccinia [letter]. *JAMA.* 1968;203:807.
- Brown TJ, Yen-Moore A, Tyring SK. An overview of sexually transmitted diseases—part II. *J Am Acad Dermatol.* 1999;41:661-677.
- Iwatsuki K, Tagami H, Takigawa M, et al. Plane warts under spontaneous regression. *Arch Dermatol.* 1986;122:655-659.
- Tagami H, Oku T, Iwatsuki K. Primary tissue culture of spontaneously regressing flat warts. *Cancer.* 1985; 55:2437-2441.
- Berman A, Winkelmann RK. Involuting common warts. *J Am Acad Dermatol.* 1980;3:356-362.
- Berman A, Winkelmann RK. Flat warts undergoing involution. *Arch Dermatol.* 1977;113:1219-1221.
- Dahl MV. Host defense: fungus. In: Dahl MV. *Clinical Immunodermatology.* Chicago, Ill: Year Book Medical Publishing Inc; 1988:171-184.
- Candin [package insert]. San Diego, Calif: Allered Laboratories, Inc; 1998.
- Sanbar SS, Gibofsky A, Firestone MH, et al, eds. Appendix 50-2 The Declaration of Helsinki. *Legal Medicine.* 5th ed. St Louis, Mo: Mosby; 2001:608.
- Harada S. Clinical application of fungus extracts and its culture filtrate in the treatment of skin diseases; (3) *Candida* vaccine in the treatment of warts. *Nippon Hifuka Gakkai Zasshi.* 1979;89:397-402.
- Warts refractory to conventional therapy yield to *Candida* antigen. Leawood, Kan: *Am Acad Fam Phys \*90 Clinical Perspectives.*
- Allergenic extracts [package insert]. Lenoir, NC: Greer Laboratories, Inc; 1998.
- Freed DLJ, Eyres KE. Persistent warts protected from immune attack by a blocking factor. *Br J Dermatol.* 1979;100:731-733.
- Baldwin RW, Robins RA. Factors interfering with immunological rejection of tumours. *Br Med Bull.* 1976;32:118-123.
- Johnson SM, Roberson PK, Horn TD. Intralesional injection of mumps or *Candida* skin test antigens—a novel immunotherapy for warts. *Arch Dermatol.* 2001;137:451-455.
- Phillips RC, Ruhl TS, Pfenniger JL, et al. Treatment of warts with *Candida* antigen injection. *Arch Dermatol.* 2000;136:1274-1275.
- Haller KH. *Candida* antigen injection proves effective treatment for warts. Available at: <http://www.aafp.org/afp/20000115/conference.html>. Accessed April 30, 2000.