

# Trichosporon beigelii Infection Presenting as White Piedra and Onychomycosis in the Same Patient

Lt Col Kathleen B. Elmer, USAF; COL Dirk M. Elston, MC, USA; COL Lester F. Libow, MC, USA

*Trichosporon beigelii* is a fungal organism that causes white piedra and has occasionally been implicated as a nail pathogen. We describe a patient with both hair and nail changes associated with *T beigelii*.

**T***richosporon beigelii* is a basidiomycetous yeast, phylogenetically similar to *Cryptococcus*.<sup>1</sup> *T beigelii* has been found on a variety of mammals and is present in soil, water, decaying plants, and animals.<sup>2</sup> *T beigelii* is known to colonize normal human skin, as well as the respiratory, gastrointestinal, and urinary tracts.<sup>3</sup> It is the causative agent of white piedra, a superficial fungal infection of the hair shaft and also has been described as a rare cause of onychomycosis.<sup>4</sup> *T beigelii* can cause endocarditis and septicemia in immunocompromised hosts.<sup>5</sup> We describe a healthy patient with both white piedra and *T beigelii*-induced onychomycosis.

## Case Report

A 62-year-old healthy man who worked as a pool maintenance employee was evaluated for thickened, discolored thumb nails (Figure 1). He had been aware of progressive brown-to-black discoloration of the involved nails for 8 months. In addition, soft, light yellow-brown nodules were noted along the shafts of several axillary hairs (Figure 2). Microscopic analysis of the hairs revealed nodal concretions along the shafts (Figure 3). No pubic, scalp, eyebrow, eyelash, or beard hair involvement was present. Cultures of thumb nail clippings on Sabouraud dextrose agar

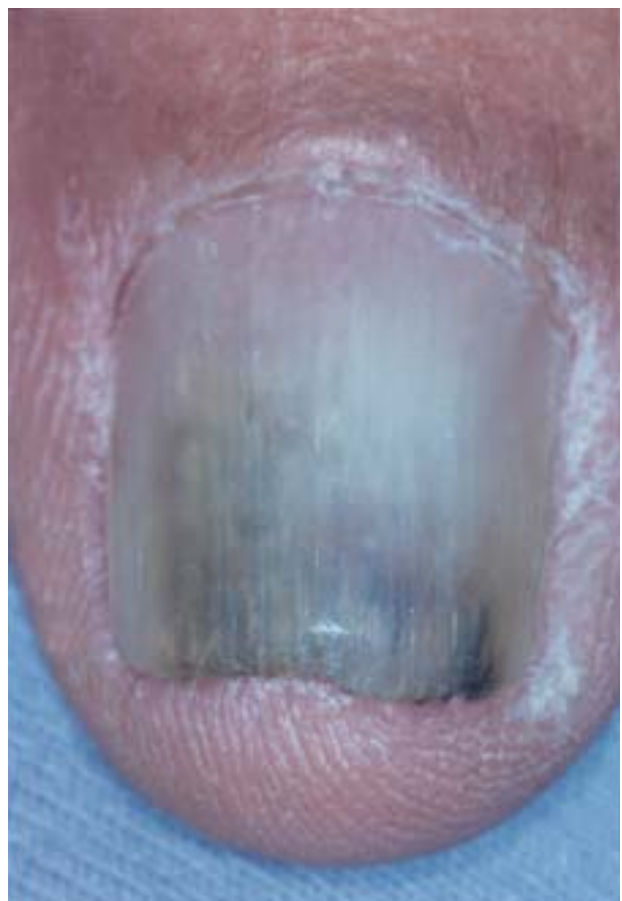


Figure 1. Onychomycotic thumb nail.

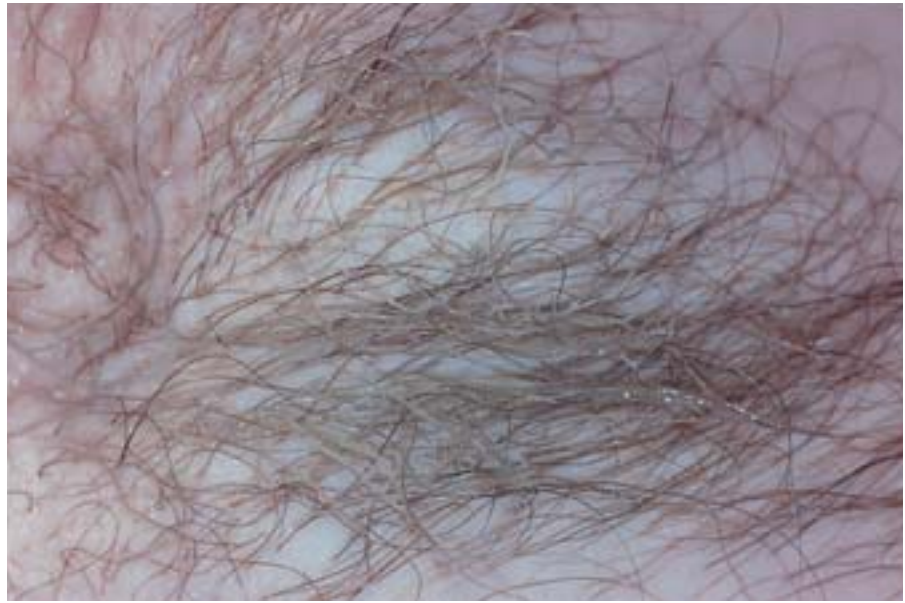grew *T beigelii* and *Candida parapsilosis*. Culture of the nail several weeks later revealed *Trichophyton* species and bacterial overgrowth.

The patient was treated with pulse itraconazole, 400 mg/d for 1 wk/mo for 3 months, as well as topical clotrimazole for the axillary regions. Four months after treatment was initiated, he reported significant improvement of the nails, as well as resolution of the axillary hair infection.

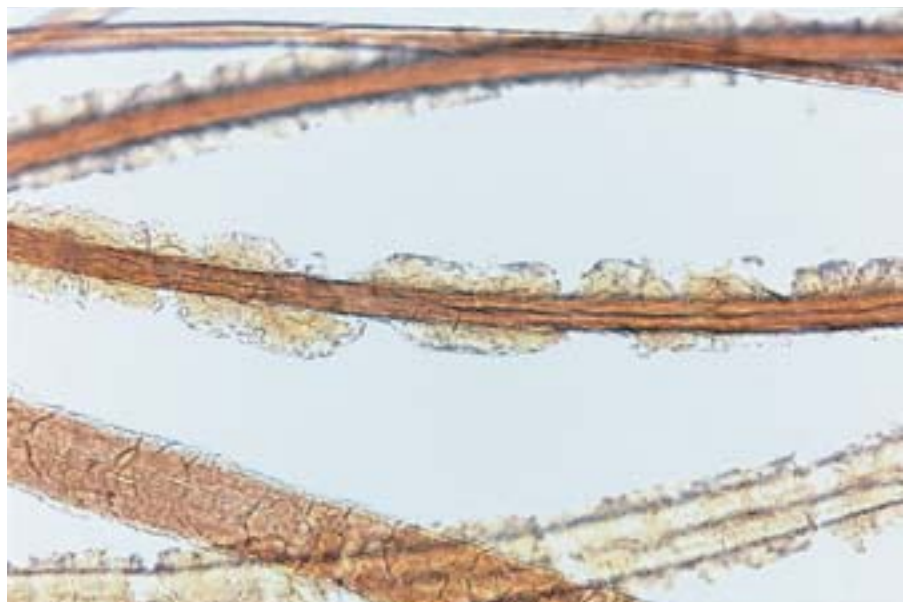
---

From the Department of Dermatology, Brooke Army Medical Center and Wilford Hall Medical Center, San Antonio, Texas. The opinions expressed are those of the authors and should not be construed as official or as representing those of the Army Medical Department, the United States Air Force, or the Department of Defense.

Reprints: Dirk M. Elston, MD, Department of Dermatology, Geisinger Medical Center, 100 N Academy Ave, Danville, PA 17822-1406 (e-mail: delston@geisinger.edu).



**Figure 2.** Axillary hair with white piedra.



**Figure 3.** Concretions of white piedra along an axillary hair shaft (original magnification  $\times 100$ ).

### Comment

*T beigelii* is an asexual yeastlike fungus named for Beigel, who first described white piedra in 1865. White piedra mainly affects the hair of the scalp, beard, moustache, and, less frequently, the eyelash, eyebrow, axillary, and genital hair. White-to-tan concretions attached to the terminal hair shaft are noted.<sup>2</sup> Although initially considered rare in the United States and predominately a tropical disease, a 40% prevalence rate of patients living in Houston was noted in 1986.<sup>6</sup> White piedra has cosmetic and clinical implications, with patients complaining of hair scale and pruritus in the affected area.<sup>7,8</sup>

*T beigelii* has been associated with onychomycosis and linked to both tinea pedis and onychomycosis in Korea.<sup>9,10</sup> In 15.4% of cases of tinea pedis in a Korean study, *T beigelii* alone was the causative organism; in another 15.4% of cases in this same study, *T beigelii* was a contributing organism with *Trichophyton rubrum*.<sup>10</sup> Similarly, *T beigelii* was the second most commonly identified fungus in onychomycotic nails in another Korean study.<sup>9</sup> Out of 1009 singularly identified isolates of fungal onychomycoses, *T beigelii* was identified in 21% of the cases. In 21 of 30 cases of mixed infections, *T beigelii* was combined with *T rubrum*.<sup>9</sup> In a study

from Hong Kong, *T beigelii* was the cause of single organism nail infection in 7.2% of patients studied.<sup>11</sup> These studies suggest a pathogenic role for *T beigelii* in nail infections.

With the increase in immunocompromised individuals, *T beigelii* has become an important factor in disseminated disease, as well as localized cutaneous disease.<sup>12,13</sup> After dissemination occurs, fatalities are common, and, therefore, even cutaneous disease should be treated in these individuals.

The treatment of choice for white piedra is the removal of infected hair by shaving or clipping. If additional treatment is desired or if hair removal is unacceptable to the patient, topical antifungals such as the imidazoles, 2% selenium sulfide, and pyrrithione zinc may be used.<sup>14</sup> Onychomycosis caused by *T beigelii* requires systemic treatment if eradication is desired. Because dermatophytes are the major cause of onychomycosis, much of the data on onychomycosis treatment are based on the response of known dermatophyte infections or of mixed infections (dermatophyte plus non-dermatophyte).<sup>15</sup> Itraconazole is generally effective for *T beigelii*-infected nails in immunocompetent individuals.<sup>16</sup> In immunocompromised patients, imidazoles, especially fluconazole, combined with amphotericin B, are felt to be the most appropriate therapy.<sup>3,13,17</sup>

## REFERENCES

1. Guého E, Improvisi L, de Hoog GS, et al. *Trichosporon* on humans: a practical account. *Mycoses*. 1994;37:3-10.
2. Kalter DC, Tschen JA, Cernoch PL, et al. Genital white piedra: epidemiology, microbiology, and therapy. *J Am Acad Dermatol*. 1986;14:982-993.
3. Keay S, Denning DW, Stevens DA. Endocarditis due to *Trichosporon beigelii*: in vitro susceptibility of isolates and review. *Rev Infect Dis*. 1991;13:383-386.
4. Fusaro RM, Miller NG. Onychomycosis caused by *Trichosporon beigelii* in the United States. *J Am Acad Dermatol*. 1984;11:747-749.
5. McBride ME, Kalter DC, Wolf JE Jr. Antifungal susceptibility testing of *Trichosporon beigelii* to imidazole compounds. *Can J Microbiol*. 1988;34:850-854.
6. Ellner KM, McBride ME, Kalter DC, et al. White piedra: evidence for a synergistic infection. *Br J Dermatol*. 1990;123:355-363.
7. Mostafa WZ, al Jabre SH. White piedra in Saudi Arabia. *Int J Dermatol*. 1992;31:501-502.
8. Thérizol-Ferly M, Kombila M, Gomez de Diaz M, et al. White piedra and *Trichosporon* species in equatorial Africa, II: clinical and mycological associations: an analysis of 449 superficial inguinal specimens. *Mycoses*. 1994;37:255-260.
9. Han MH, Choi JH, Sung KJ, et al. Onychomycosis and *Trichosporon beigelii* in Korea. *Int J Dermatol*. 2000;39:266-269.
10. Jang KA, Chi DH, Choi JH, et al. Tinea pedis in Korean children. *Int J Dermatol*. 2000;39:25-27.
11. Kam KM, Au WF, Wong PY, et al. Onychomycosis in Hong Kong. *Int J Dermatol*. 1997;36:757-761.
12. Nahass GT, Rosenberg SP, Leonardi CL, et al. Disseminated infection with *Trichosporon beigelii*: report of a case and review of the cutaneous and histologic manifestations. *Arch Dermatol*. 1993;129:1020-1023.
13. Yoss BS, Sautter RL, Brenker HJ. *Trichosporon beigelii*: a new neonatal pathogen. *Am J Perinatol*. 1997;14:113-117.
14. Drake LA, Dinehart SM, Farmer ER, et al. Guidelines of care for superficial mycotic infections of the skin: piedra. *J Am Acad Dermatol*. 1996;34:122-124.
15. Ellis DH, Watson AB, Marley JE, et al. Non-dermatophytes in onychomycosis of the toenails. *Br J Dermatol*. 1997;136:490-493.
16. Ruhnke M. Therapy of yeast-associated infections. *Contrib Microbiol*. 2000;5:79-97.
17. Tashiro T, Nagai H, Nagaoka H, et al. *Trichosporon beigelii* pneumonia in patients with hematologic malignancies. *Chest*. 1995;108:190-195.