

Wells Syndrome

Vince Afsahi, MD; Carolyn Kassabian, MD

GOAL

To understand Wells syndrome

OBJECTIVES

Upon completion of this activity, dermatologists and general practitioners should be able to:

1. Describe the presentation of Wells syndrome.
2. Discuss the inciting factors for Wells syndrome.
3. Explain the treatment options for Wells syndrome.

CME Test on page 208.

This article has been peer reviewed and approved by Michael Fisher, MD, Professor of Medicine, Albert Einstein College of Medicine. Review date: August 2003.

This activity has been planned and implemented in accordance with the Essential Areas and Policies of the Accreditation Council for Continuing Medical Education through the joint sponsorship of Albert Einstein College of Medicine and Quadrant HealthCom, Inc. Albert Einstein College of Medicine

is accredited by the ACCME to provide continuing medical education for physicians.

Albert Einstein College of Medicine designates this educational activity for a maximum of 1 category 1 credit toward the AMA Physician's Recognition Award. Each physician should claim only that hour of credit that he/she actually spent in the activity.

This activity has been planned and produced in accordance with ACCME Essentials.

Drs. Afsahi and Kassabian report no conflict of interest. The authors report no discussion of off-label use. Dr. Fisher reports no conflict of interest.

Wells syndrome, or eosinophilic cellulitis, is a rare disorder characterized by erythematous plaques evolving into dermal or subcutaneous masses. The histopathology shows degenerative collagen, histiocytes, and eosinophils. Although most cases of Wells syndrome occur in adults, we present a child with these clinical and histopathologic findings.

Cutis. 2003;72:209-212.

Accepted for publication August 4, 2003.

Dr. Afsahi is in private practice in Orange County, California, and is a Clinical Instructor of Dermatology at the University of Southern California and University of California at Los Angeles/Olive View Medical Center. Dr. Kassabian is a dermatology resident at the University of Southern California School of Medicine, Los Angeles.

Reprints: Vince Afsahi, MD, 6000 E Silverspur Trail, Anaheim, CA 92807 (e-mail: drafsahi@yahoo.com).

Wells syndrome, or eosinophilic cellulitis, is a rare inflammatory dermatosis first described by Wells in 1971.^{1,2} More than 100 clinical cases have been described in the medical literature, but only 18 of these cases have occurred in children.³ The syndrome is characterized by recurrent cutaneous erythema and edema, peripheral eosinophilia, and a typical histopathology.

Case Report

A 17-month-old child presented with a 2-month recurrent cutaneous rash on all 4 extremities. The eruption consisted of red and painful papules that progressively increased in size and evolved over a period of 7 days into thickened nodules. Lesions of various stages of development were present at the same time. The patient was irritable during this time, but not febrile. Before presenting to us, the

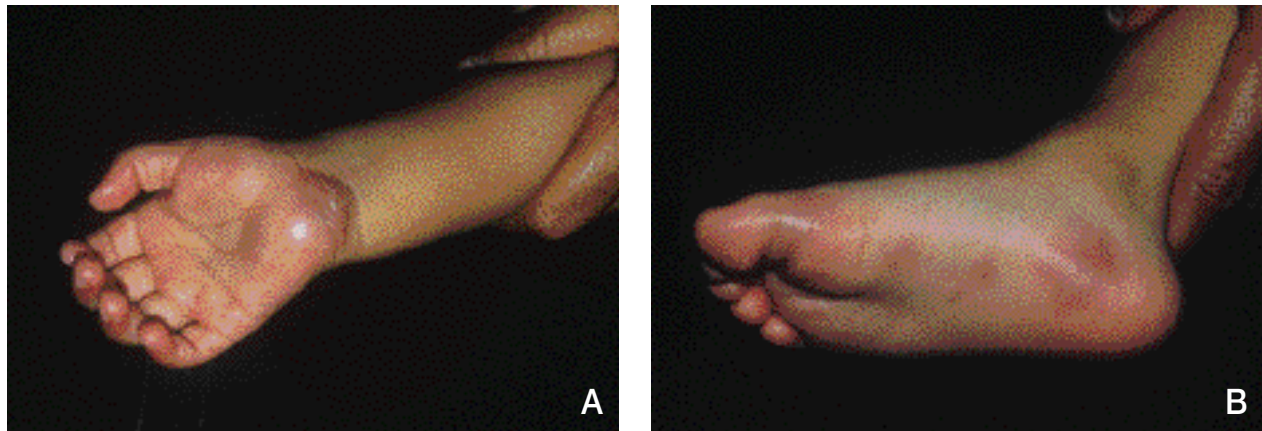


Figure 1. Palms (A) and soles (B) showing erythematous and edematous plaques characteristic of Wells syndrome.

patient had been treated with oral antibiotics, which proved to be ineffective.

Physical examination revealed mildly fluctuant, violaceous, indurated plaques on the palms and soles bilaterally and on the dorsum of the left foot (Figure 1). All lesions were tender to palpation. Significant laboratory findings included a white blood cell count of $15.9 \times 10^3/\mu\text{L}$ with 14% eosinophils. Biopsy results of the 5×5 -mm plaque on the dorsum of the left foot showed mixed dermal infiltrate with marked eosinophilia and collagen degenerative changes with flame figures (Figure 2). Eosinophilic cellulitis was diagnosed, and the patient was started on prednisone 1 mg/kg daily. The lesions resolved after 3 weeks of corticosteroid therapy.

Comment

Although the etiology of Wells syndrome is not clearly defined, it is believed to be a hypersensitivity reaction to various triggering agents (Table).¹⁻¹⁴ In the majority of cases, however, the inciting agent remains unknown, as was the case with our patient. Some authors define Wells syndrome as a clinical entity,⁹ while others view it strictly as a histopathologic reaction pattern.^{5,12}

Patients with eosinophilic cellulitis present with focal edema and annular or circinate, erythematous, infiltrated plaques with a sharp, rosy, or violaceous border. The lesions, commonly located on the extremities and trunk, may progress to vesicles and bullae. Pruritus, pain, and a burning sensation can be present before or during the presence of the lesions; however, systemic symptoms (malaise, fever) are rare.⁹ Peripheral eosinophilia is detected in approximately half of the patients.^{1,2} After a period of days to several weeks, these lesions evolve to bluish gray, indurated lesions, and the

skin eventually returns to normal without scar formation. In most cases, new lesions erupt after the initial outbreak.

At their onset, the lesions of Wells syndrome may be clinically mistaken for erysipelas or infectious cellulitis; however, a course of antibiotics will fail to treat the symptoms. Less common diseases, such as allergic granulomatosis of Churg-Strauss and hypereosinophilic syndromes, also may be suspected. The absence of necrotizing vasculitis on biopsy and a negative serum antineutrophilic cytoplasmic antibody, however, excludes the diagnosis of Churg-Strauss syndrome.¹⁵ A diagnosis of hypereosinophilic syndrome requires evidence of visceral involvement and a sustained eosinophilia for more

Inciting Factors of Wells Syndrome

- Atopic dermatitis⁴
- Fungal infections²
- Insect bites^{2,3,5}
- Malignancies⁶
- Medications^{1,2,7,8}
- Mumps²
- Myeloproliferative disorders^{1,7,9}
- Parasitic infections^{10,11}
- Raynaud disease⁷
- Surgery⁸
- Urticaria¹²
- Vaccines (tetanus)¹³
- Varicella¹⁴

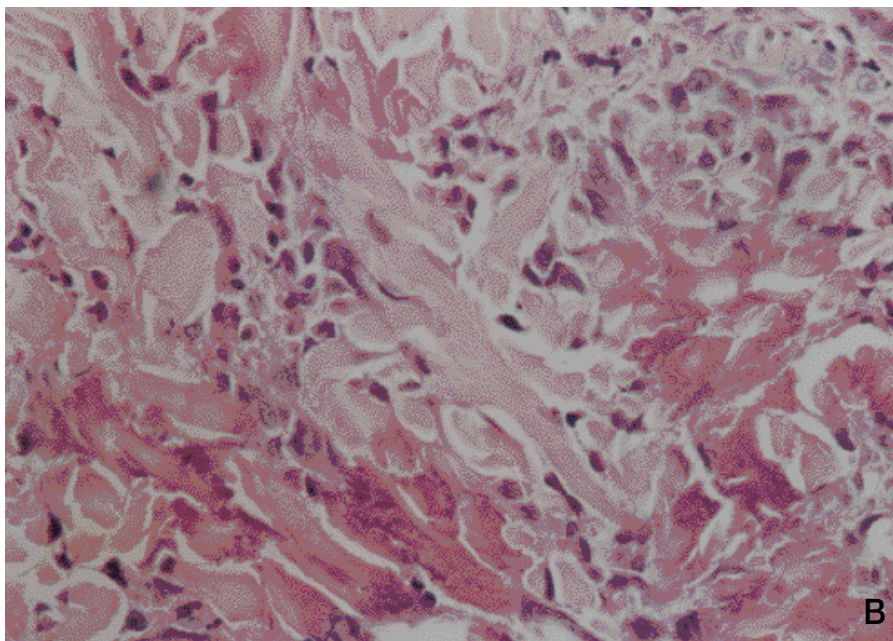
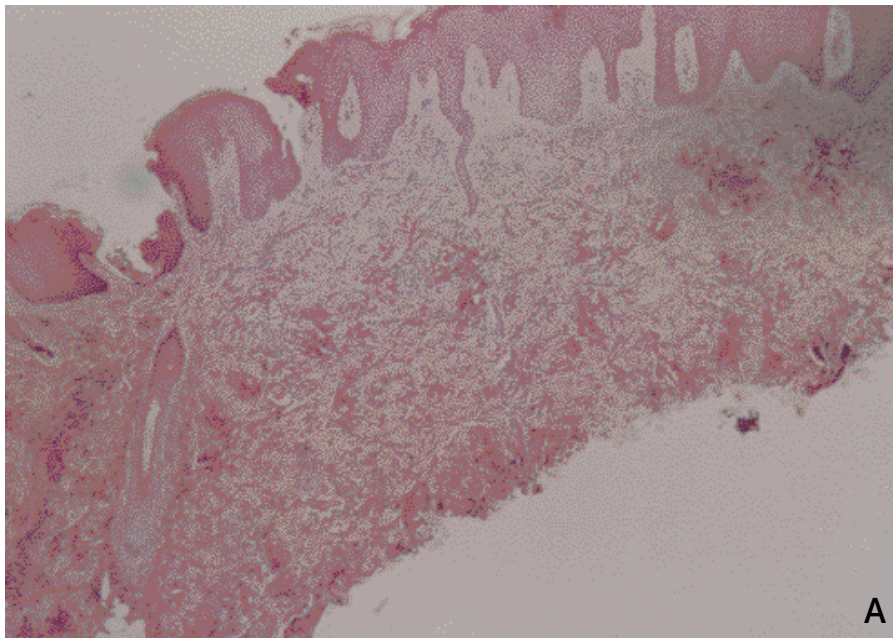


Figure 2. Biopsy results of patient's lower extremity shows collagen degeneration and flame figures (A and B)(H&E, original magnifications $\times 10$ and $\times 40$).

than 6 months.¹⁶ The hyperpigmented and indurated lesions of late-stage Wells syndrome may resemble the appearance of morphea.

The diagnosis of Wells syndrome usually is made by skin biopsy. Wells^{1,17} described 3 sequential histopathologic stages of the syndrome. The acute, or cellulitic, stage is identified by both edema and an eosinophilic infiltrate (interstitially and perivascularly) in the dermis, especially the reticular dermis. The subacute stage, also known as granulomatous dermatitis, is characterized by the

formation of flame figures, which are collections of eosinophils, histiocytes, and foreign body giant cells encircling a core of degenerated collagen fibers in a background of granulomatous inflammation. Immunofluorescence localizes major basic protein within the flame figures, indicating eosinophilic degranulation.⁷ Although highly characteristic of Wells syndrome, flame figures are not pathognomonic for the disease and also can be seen in bullous pemphigoid, gestational herpes, insect bites, and fungal and parasitic infections.^{2,5,18}

The last stage is the resolution stage, which shows decreased numbers of eosinophils within the granulomatous inflammation.

The recommended treatment for Wells syndrome is a tapering course of systemic corticosteroids, usually prednisone at a dose of 10 to 80 mg/day.^{1,3,8,19} One study reported that even low-dose (5 mg) prednisone every other day was efficacious in the treatment of Wells syndrome.²⁰ On rare occasions, patients treated with dapsone have shown clinical improvement.²¹ Most recently, psoralen-UVA phototherapy has had initial success in clearing the lesions of Wells syndrome.²² The effectiveness of treatment is confounded by the fact that the lesions resolve within 6 to 8 weeks with or without therapy. Although the syndrome recurs sporadically, spontaneous resolution occurs in all patients after a period of months to several years.^{9,20}

REFERENCES

1. Wells GC. Recurrent granulomatous dermatitis with eosinophilia. *Trans St Johns Hosp Dermatol Soc.* 1971;57:46-56.
2. Wells GC, Smith NP. Eosinophilic cellulitis. *Br J Dermatol.* 1979;100:101-109.
3. Anderson CR, Jenkins D, Tron V, et al. Wells' syndrome in childhood: case report and review of literature. *J Am Acad Dermatol.* 1995;33:857-864.
4. Brehmer-Anderson E, Kaaman T, Skog E, et al. The histopathogenesis of the flame figures in Wells' syndrome based on five cases. *Acta Derm Venereol.* 1986;66:213-219.
5. Schorr WF, Tauscheck AL, Dickson KB, et al. Eosinophilic cellulitis Wells' syndrome: histologic and clinical features in arthropod bite reactions. *J Am Acad Dermatol.* 1984;11:1043-1049.
6. Varotti C, Tosti A, Gobbi M, et al. Eosinophilic cellulitis: a new case. *Dermatologica.* 1982;164:404-406.
7. Peters MS, Schroeter AL, Gleich GJ. Immunofluorescence identification of eosinophil granule major basic protein in the flame figures of Wells' syndrome. *Br J Dermatol.* 1983;109:141-148.
8. Spigel GT, Winkelmann RK. Wells' syndrome. *Arch Dermatol.* 1979;115:611-613.
9. Aberer W, Konrad K, Wolff K. Wells' syndrome is a distinctive disease entity and not a histologic diagnosis. *J Am Acad Derm.* 1988;18:105-114.
10. Tsuda S, Tanaka K, Miyasoto M, et al. Eosinophilic cellulitis (Wells' syndrome) associated with ascariasis. *Acta Derm Venereol.* 1994;74:292-294.
11. van den Hoogenband HM. Eosinophilic cellulitis as a result of onchocerciasis. *Clin Exp Dermatol.* 1983;8:405-408.
12. Dijkstra JWE, Bergeld WF, Steck WD, et al. Eosinophilic cellulitis associated with urticaria. *J Am Acad Dermatol.* 1986;14:32-38.
13. Moreno M, Luelmo J, Monteagudo M, et al. Wells' syndrome related to tetanus vaccine. *Int J Dermatol.* 1997;36:524-525.
14. Reichel M, Isseroff RR, Vogt PJ, et al. Wells' syndrome in children: varicella infection as a precipitating event. *Br J Dermatol.* 1991;124:187-190.
15. Schwartz RA, Churg J. Churg-Strauss syndrome. *Br J Dermatol.* 1992;127:199-204.
16. Hardy WR, Anderson RE. The hypereosinophilic syndromes. *Ann Intern Med.* 1968;68:1220-1229.
17. Wells GC. Eosinophilic cellulitis. In: Wolff K, Winkelmann RK, eds. *Vasculitis.* London, England: Lloyd-Luke; 1980:317-321.
18. Wood C, Miller AC, Jacobs A, et al. Eosinophilic infiltration with flame figures. a distinctive tissue reaction seen in Wells' syndrome and other diseases. *Am J Dermatopathol.* 1986;8:186-193.
19. Tassava T, Rusonis P, Whitmore SE. Recurrent vesiculobullous plaques. *Arch Dermatol.* 1997;133:1579-1584.
20. Coldiron BM, Robinson JK. Low-dose alternate-day prednisone for persistent Wells' syndrome. *Arch Dermatol.* 1989;125:1625-1626.
21. Marks R. Eosinophilic cellulitis—a response to treatment with dapsone: case report. *Australas J Dermatol.* 1980;21:10-12.
22. Diridle E, Honigsmann H, Tanew A. Wells' syndrome responsive to PUVA therapy. *Br J Dermatol.* 1997;137:479-481.

DISCLAIMER

The opinions expressed herein are those of the authors and do not necessarily represent the views of the sponsor or its publisher. Please review complete prescribing information of specific drugs or combination of drugs, including indications, contraindications, warnings, and adverse effects before administering pharmacologic therapy to patients.

FACULTY DISCLOSURE

The Faculty Disclosure Policy of the Albert Einstein College of Medicine requires that faculty participating in a CME activity disclose to the audience any relationship with a pharmaceutical or equipment company that might pose a potential, apparent, or real conflict of interest with regard to their contribution to the activity. Any discussions of unlabeled or investigational use of any commercial product or device not yet approved by the US Food and Drug Administration must be disclosed.