

Cutaneous Histoplasmosis in Patients With Acquired Immunodeficiency Syndrome

Joshua David Rosenberg, BA; Noah S. Scheinfeld, MD, JD

GOAL

To understand the presentation, diagnosis, and treatment of cutaneous manifestations of histoplasmosis in patients with acquired immunodeficiency syndrome (AIDS)

OBJECTIVES

Upon completion of this activity, dermatologists and general practitioners should be able to:

1. Discuss the clinical manifestations of cutaneous histoplasmosis in patients with AIDS.
2. Recognize the histopathologic findings of cutaneous histoplasmosis.
3. Describe the appropriate treatment of AIDS patients with cutaneous histoplasmosis.

CME Test on page 438.

This article has been peer reviewed and approved by Michael Fisher, MD, Professor of Medicine, Albert Einstein College of Medicine. Review date: November 2003.

This activity has been planned and implemented in accordance with the Essential Areas and Policies of the Accreditation Council for Continuing Medical Education through the joint sponsorship of Albert Einstein College of Medicine and Quadrant HealthCom, Inc. Albert Einstein College of Medicine

is accredited by the ACCME to provide continuing medical education for physicians.

Albert Einstein College of Medicine designates this educational activity for a maximum of 1 category 1 credit toward the AMA Physician's Recognition Award. Each physician should claim only that hour of credit that he/she actually spent in the activity.

This activity has been planned and produced in accordance with ACCME Essentials.

Dr. Scheinfeld reports no conflict of interest. The authors report discussion of off-label use of itraconazole. Dr. Fisher reports no conflict of interest.

Since 1987, the US Centers for Disease Control and Prevention has considered disseminated histo-

plasmosis an acquired immunodeficiency syndrome (AIDS)-defining illness. Cutaneous manifestations of disseminated disease are diverse and often present as a nondescript rash with systemic complaints. Diagnosis is best established by histopathologic examination with appropriate stains for fungal organisms. Skin lesions often resolve within weeks of initiating treatment. We detail a case of cutaneous histoplasmosis and review its epidemiology, common presentations, diagnosis, and treatment options.

Cutis. 2003;72:439-445.

Accepted for publication October 31, 2003.

Mr. Rosenberg is a medical student at Albert Einstein College of Medicine, Bronx, New York. Dr. Scheinfeld is Assistant Clinical Professor of Dermatology, Columbia University College of Physicians and Surgeons, New York, New York, and Director of the consultation service at St. Luke's-Roosevelt Hospital Center and Beth Israel Medical Center, New York, New York.

Reprints: Noah S. Scheinfeld, MD, JD, Department of Dermatology, St. Luke's-Roosevelt Hospital Center, 1090 Amsterdam Ave, Suite 11D, New York, NY 10025 (e-mail: scheinfeld@earthlink.com).

Infection with *Histoplasma capsulatum*, the dimorphic fungus that causes histoplasmosis, usually results from inhalation of its spores, which live in soil, bird droppings, and bat guano. *H capsulatum* is found in a variety of locations throughout the world. In the United States, the Ohio and Mississippi River valleys are endemic regions.¹ The fungus also is prevalent throughout Puerto Rico.² Infection can result in pulmonary disease of varying length and severity. Many cases of infection are asymptomatic. Other manifestations of histoplasmosis include disseminated infection resulting in systemic disease. The cutaneous manifestations of histoplasmosis most often occur secondary to disseminated disease, though rare cases of primary skin infection resulting from direct inoculation have been reported.

Case Report

A 32-year-old Hispanic man, seropositive for the human immunodeficiency virus (HIV) with a recent absolute CD4 cell count of 23/ μ L and a viral load of 350×10^3 / μ L, was admitted to the hospital with a 2-week history of a pruritic erythematous papular rash, fever, 8-pound weight loss, dysphagia, lethargy, and confusion. The patient started lamivudine and nevirapine 2 weeks earlier, after which he developed the rash and then his other symptoms. He was not taking any other medications.

The patient's medical history was significant for HIV diagnosed 2 years prior, oral thrush, human papillomavirus anal warts, and a positive rapid plasma reagin test that resulted in treatment with intramuscular penicillin. The patient had a history of multiple sexual partners and intravenous drug use, which he stopped approximately 2 months prior to admission. The patient was born in Los Angeles, California, and was living in Brooklyn, New York, at the time of admission. He had traveled to Puerto Rico several years prior. He did not have any pets and denied any medication allergies.

Physical examination revealed distinct, well-circumscribed papules 2 to 4 mm in diameter on his face (Figure 1), trunk, extremities, palms, and soles. Oral examination was significant for petechiae on soft and hard palates without any white plaques. No lymphadenopathy was noted. Verrucous plaques were noted around the anus.

A chest x-ray demonstrated an opacity in the base of the right lung that the radiologist interpreted to be of indeterminate significance. The patient's laboratory values were notable for a pancytopenia with a hemoglobin level of 7.7 g/dL (reference range, 13.5–17.5 g/dL), a hematocrit level of 22.5% (reference range, 39%–49%), a white blood cell count




Figure 1. Well-circumscribed red papules due to cutaneous histoplasmosis on the face of a patient with AIDS with disseminated disease.

of 3300/ μ L (reference range, 4500–1100/ μ L), and a platelet count of 61×10^3 / μ L (reference range, 150–450/ $\times 10^3$ / μ L). His serum sodium level was 125 mEq/L (reference range, 135–145 mEq/L), his serum chloride level was 93 mEq/L (reference range, 60–100 mEq/L), and his blood urea nitrogen level was elevated at 22 mg/dL (reference range, 7–18 mg/dL). His serum creatinine and other electrolyte levels were all within reference range. The patient had a total calcium level of 6.3 mg/dL (reference range, 8.4–10.2 mg/dL) that was corrected to 8.3 mg/dL secondary to an albumin level of 1.5 g/dL (reference range, 3.5–5.5 g/dL). His total protein level was 5.6 g/dL (reference range, 6.0–8.0 g/dL). His liver function tests were notable for an aspartate aminotransferase level of 111 U/L, an alanine aminotransferase level of 53 U/L, and an alkaline phosphatase level of 458 U/L (reference ranges, 7–40 U/L, 7–40 U/L, and 38–126 U/L, respectively). The patient's total and conjugated

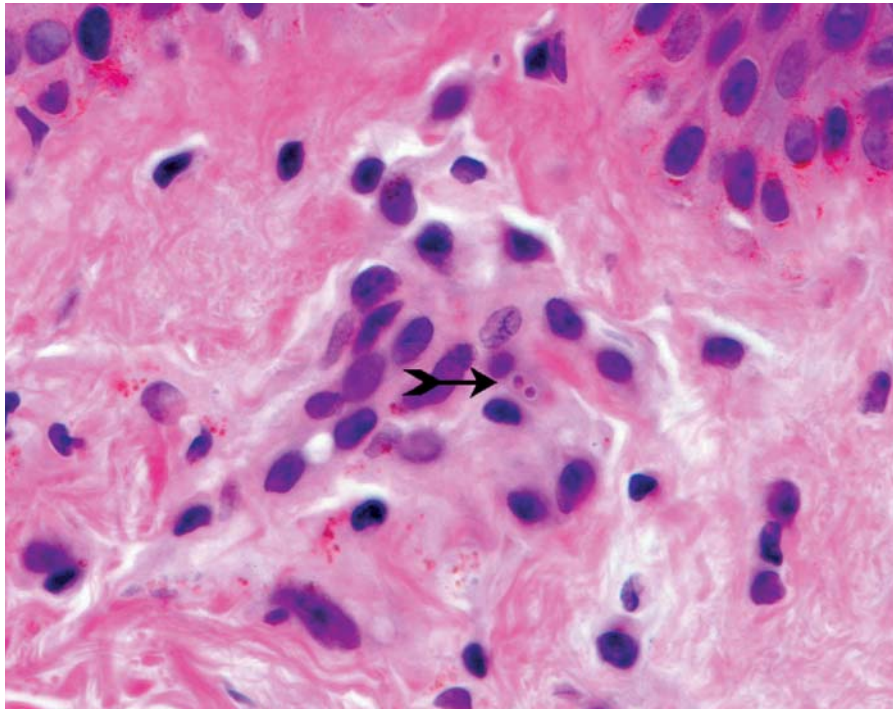


Figure 2. Parasitized histiocytes containing round to oval yeast forms of *Histoplasma capsulatum* (H&E, original magnification $\times 400$).

bilirubin levels were normal, but his lactate dehydrogenase level was elevated at 398 U/L (reference range, 90–190 U/L). Initial differential diagnoses included a drug hypersensitivity reaction, secondary syphilis, bacillary angiomatosis, a deep fungal infection, and miliary tuberculosis.

Sections of a skin biopsy stained with hematoxylin and eosin demonstrated perivascular, perifollicular, perineuronal, and intraneuronal infiltrate of parasitized histiocytes containing round to oval organisms 2 to 3 μm in diameter, suggestive of *H capsulatum* (Figure 2). Free organisms were present in the dermis and arrector pili muscles. Positive periodic acid–Schiff and Gomori methenamine silver stains showed oval fungal forms as well. Results of a urine *H capsulatum* antigen test also were positive. A diagnosis of disseminated histoplasmosis was made, and the patient was treated with intravenous amphotericin B 1 mg/kg daily over 3 weeks. His symptoms, including the rash, began to resolve, and the patient was discharged with a therapeutic regimen of oral itraconazole 200 mg twice daily.

Comment

Although disseminated histoplasmosis is found in approximately 1 in 2000 exposed immunocompetent individuals, increased risk for disseminated disease generally is characterized by extremes of

age or immunosuppression.³ Before the HIV epidemic, disseminated histoplasmosis was most prevalent among patients with congenital immune defects or those receiving chronic steroids or other immunosuppressive therapies. Since the advent of amphotericin B therapy, reports of disseminated disease had been in a steady decline.⁴ As a result of the HIV epidemic, however, disseminated histoplasmosis has made a resurgence. Since 1987, disseminated histoplasmosis has been considered an AIDS-defining illness by the US Centers for Disease Control and Prevention.⁵ Estimates of the incidence of disseminated histoplasmosis in HIV patients vary, but the number generally has been placed at about 5% of patients infected with HIV in endemic areas.⁶

Although *H capsulatum* is endemic to specific regions, a diagnosis of disseminated histoplasmosis should be considered in all patients with AIDS with unusual dermatologic findings, regardless of where the patients reside. Controversy exists as to whether disseminated histoplasmosis in patients with AIDS is a new infection or a reactivation of a latent infection. To our knowledge, no definitive data supporting either theory has been reported to date. Additionally, it has been noted that patients exposed to possible microfoci of *H capsulatum* in places such as construction sites, bat-infested caves, chicken coops, and farms in both endemic

and nonendemic areas may be at an increased risk of infection.⁷ AIDS-related disseminated histoplasmosis in nonendemic areas such as New York City may be the result of a reactivation of a latent infection acquired in an endemic region or the result of exposure to local microfoci of *H capsulatum*.⁸ In our patient, infection may have resulted from a reactivation of a previous infection that perhaps was acquired while traveling in Puerto Rico, a known endemic area, or from a more recent exposure to microfoci of the fungus, like those that have been described in New York City.

Fever and weight loss are the most common presenting symptoms (81% and 52%, respectively) in patients with AIDS with disseminated histoplasmosis. Because *H capsulatum* spores are engulfed by macrophages and disseminated throughout the body via the reticuloendothelial system, common signs of disseminated disease are hepatomegaly and splenomegaly (31% and 19%, respectively).^{9,10} Cutaneous manifestations of disseminated histoplasmosis occur in approximately 11% of patients with AIDS and disseminated histoplasmosis.¹¹ The manifestations are more common in AIDS-related disseminated histoplasmosis than in non-AIDS-related disseminated histoplasmosis in which the manifestations are estimated to occur in approximately 6% of affected patients.¹² The lack of findings on chest x-rays should not exclude a diagnosis of histoplasmosis because only 50% to 70% of reported cases of disseminated histoplasmosis with cutaneous manifestations had this finding.¹³ Lesions are most commonly found on the face, trunk, legs, and arms. Less common locations include the hands, feet, back, and chest. Cutaneous lesions also have been reported on the penis and in the perianal area.

The dermatologic manifestations of disseminated histoplasmosis can be quite varied in patients with AIDS (Table).^{7,10,11,14-28} Papules, macules, nodules, erythematous patches, and mucosal ulcers are the most common findings. Less common presentations include plaques, pustules, and cutaneous ulcers.¹³ Additionally, the immunologic derangements wrought by HIV allow for the atypical presentation of cutaneous infection. Accordingly, there have been numerous reports of a variety of cutaneous manifestations of disseminated histoplasmosis ranging from verrucous plaques to nonspecific reactive dermatoses such as erythema multiforme.

Although cutaneous manifestations of histoplasmosis secondary to disseminated disease are an uncommon finding, primary cutaneous histoplasmosis is exceedingly rare. To our knowledge, only one case of primary cutaneous histoplasmosis has

been reported in a patient with AIDS.²¹ Other reports of primary cutaneous histoplasmosis have been in immunocompetent and immunosuppressed adults and a young child.^{29,30} Most of the reported cases of primary cutaneous histoplasmosis involved single or multiple ulcerated lesions that were either pustular or nodular and that occurred at the site of a previous trauma, which was thought to be the inoculating event.³¹ Manifestations such as cellulitis, erysipelas, and ulcerated plaques also have been described.^{22,28} The one reported case of primary cutaneous histoplasmosis in a patient with AIDS presented as an erythematous painless nodule with a central crater resembling a "giant molluscum contagiosum." There was no history of trauma at the site, and the patient had no evidence of disseminated disease. A diagnosis of primary cutaneous histoplasmosis should be reserved for patients with biopsy-proven cutaneous histoplasmosis and an absence of any signs or symptoms of pulmonary or systemic disease after thorough examination.^{30,31}

Fungal culture is considered the "gold standard" in the diagnosis of cutaneous histoplasmosis (primary or secondary). Culture on Sabouraud agar media at 30°C will show hyphae with either tuberculate macroconidia or microconidia. However, due to the length of time a culture takes to reveal growth (2–3 weeks) and the high mortality rate associated with untreated disseminated histoplasmosis, a culture generally is used to confirm the results of a biopsy, which provides rapid diagnosis. The classic histologic findings of histoplasmosis are characterized by necrotizing granulomas with epithelioid cells, giant cells, lymphocytes, and plasma cells in acute pulmonary infection, and the presence of intracellular yeast forms in macrophages without granulomas or obvious inflammatory response in disseminated disease. Along with the varied dermatologic manifestations of cutaneous histoplasmosis, the histologic manifestations also can be highly variable. The histologic picture in patients infected with HIV with cutaneous manifestations of disseminated histoplasmosis ranges from abundant parasitized histiocytes in the dermis, similar to the patient reported above, to a predominantly extracellular pattern of free organisms in the dermis, perivascular infiltrate, and karyorrhexis (numerous nuclear fragments).^{18,32} The latter pattern has been described as resembling an "atypical leukocytoclastic vasculitis."¹³

Special stains (periodic acid–Schiff, Gomori methenamine silver) play an important role in establishing a diagnosis of histoplasmosis. For biopsy results with a pattern of predominantly intracellular organisms, special stains will differentiate

Mucocutaneous Manifestations of Histoplasmosis

Etiology	Morphology
Secondary cutaneous	Papules and nodules ^{11,14-19} Macules and patches ^{11,16,17,20} Ulcers ^{7,14,16,21} Plaques ^{7,11,16} Pustules ^{11,16} Erythema multiforme ¹⁴ Verrucous plaques ²² Rosacealike ²³ Eczematous dermatitis ²⁰ Panniculitis* ²⁴ Cellulitis* ²⁵ Abscesses* ²⁶ Pyoderma ²⁷
Secondary mucosal	Ulcers ¹⁶ Nodules ¹⁰
Primary cutaneous	Nodules ²¹ Plaques* ²² Cellulitis* ²⁸

*Cases reported are of patients who do not have acquired immunodeficiency syndrome.

between *H capsulatum* and other causes of parasitized histiocytes including Chagas disease, granuloma inguinale, rhinoscleroma, and leishmaniasis. The latter etiologies will not stain on periodic acid–Schiff. Additionally, some reports have noted difficulty visualizing the organism on sections stained with hematoxylin and eosin, especially those with a pattern of predominately extracellular organisms.¹⁸ For this reason, before histoplasmosis can be ruled out in a patient with HIV with systemic symptoms and dermatologic findings, use of alternate staining methods may be indicated to visualize previously undetected organisms. Additional diagnostic tools that may raise or lower the index of suspicion include a radioimmunoassay to detect histoplasmosis antigen in the urine or

blood, a complement-fixation test, and an immunodiffusion test.

Cutaneous manifestations of disseminated histoplasmosis generally resolve within days to weeks of initiating treatment.¹³ Because cutaneous infection usually is found within the context of disseminated disease, appropriate treatment is aimed at the disseminated infection. According to the current management guidelines for patients with histoplasmosis, treatment of patients with HIV with disseminated histoplasmosis should be divided into a 12-week induction phase and a lifelong maintenance phase to prevent relapse. For patients with severe disease who require hospitalization, amphotericin B 0.8 to 1.0 mg/kg daily is recommended for induction.³³ There is no published data on the use of newer lipid preparations of amphotericin B or newer antifungals such as caspofungin for the treatment of histoplasmosis. For patients with mild disease who initially do not require hospitalization or patients with severe disease who have improved to the point where they no longer require hospitalization, itraconazole 200 mg twice daily can be used to complete the induction phase. Fluconazole 400 mg twice daily may be an adequate alternative for patients who cannot tolerate itraconazole, though it appears to be less effective.

For long-term maintenance therapy, itraconazole 200 mg once or twice daily for life is the treatment of choice, though intravenous amphotericin B 50 mg once weekly or fluconazole 400 to 800 mg daily can be used as alternatives.³³ In endemic areas, prophylaxis with itraconazole may be recommended for patients with AIDS. Prophylactic itraconazole 200 mg daily demonstrated a 2-fold reduction in the incidence of histoplasmosis in patients with CD4 cell counts less than 150/ μ L compared with placebo.³⁴ Fluconazole is not an acceptable alternative for prophylaxis.

Because primary cutaneous histoplasmosis is a rare event, especially in the context of AIDS, there are no specific treatment recommendations. Kronic et al²¹ reported the management of a patient based on the guidelines for patients with AIDS with disseminated histoplasmosis, including long-term maintenance therapy. The patient's skin lesion resolved; however, though the patient died about 6 months later, the death did not appear to be the result of disseminated histoplasmosis. Based on the high morbidity and mortality of disseminated infection, treating any patient with primary cutaneous histoplasmosis and AIDS as if there is a disseminated infection would appear to be the best course of action.

The presentation of our patient's eruption was not uncommon for a patient with AIDS and disseminated

histoplasmosis with cutaneous manifestations. In addition to a rash, his chief complaints included fever and weight loss, 2 of the most common complaints among patients with disseminated histoplasmosis. Laboratory tests revealed elevated liver function levels that were believed to be the result of disseminated histoplasmosis involvement in the liver. The patient's oral petechiae were an interesting finding. They were thought to be secondary to the patient's thrombocytopenia and a possible coagulopathy, both of which have been reported in patients with disseminated histoplasmosis.⁷ It is interesting to note that although the patient's travel history included travel to an endemic area (Puerto Rico), the visit had taken place many years in the past. As mentioned earlier, it is not known whether disseminated histoplasmosis in patients with AIDS represents a reactivation of an old infection or a new infection. Based on our patient's travel history, the cause of his infection could not be known. Our patient was treated according to the guidelines set forth by Wheat et al³³ and improved within a matter weeks.

Although our patient's presentation was "typical," his nondescript rash and systemic complaints may have resulted from any number of infections known to occur in patients with AIDS including secondary syphilis, miliary tuberculosis, and bacillary angiomatosis. Given the prevalence of histoplasmosis in patients with AIDS and its diverse cutaneous presentations, it should be included on the list of differential diagnoses with evidence of systemic disease and unusual cutaneous findings. A skin biopsy with special stains for fungal organisms and urine/serologic tests for histoplasmosis should be performed as part of any diagnostic workup.

REFERENCES

- Mandell GL, Bennett JE, Dolin R. *Principles and Practice of Infectious Diseases*. Vol 1. Philadelphia, Pa: Churchill Livingstone; 2000.
- Cahn P. AIDS in Latin America. *Infect Dis Clin North Am*. 2000;14:185-209.
- Wheat LJ. Histoplasmosis in Indianapolis. *Clin Infect Dis*. 1992;14:91-99.
- Chanda JJ, Callen JP. Isolated nodular cutaneous histoplasmosis. *Arch Dermatol*. 1978;114:1197-1198.
- Centers for Disease Control and Prevention. Revision of the CDC surveillance case definition for the acquired immunodeficiency syndrome. *MMWR Morb Mortal Wkly Rep*. 1987;36:1S.
- Hajjeh RA. Disseminated histoplasmosis in persons infected with human immunodeficiency virus. *Clin Infect Dis*. 1995;21:108-110.
- Wheat JL, Connolly-Stringfield PA, Baker RL, et al. Disseminated histoplasmosis and the acquired immunodeficiency syndrome: clinical findings, diagnosis and treatment, and review of the literature. *Medicine*. 1990;60:361-373.
- Huang CT, McGarry T, Cooper S, et al. Disseminated histoplasmosis in the acquired immunodeficiency syndrome. *Arch Intern Med*. 1987;47:1181-1184.
- Johnson PC, Khardori N, Najjar A, et al. Progressive disseminated histoplasmosis in patients with acquired immunodeficiency syndrome. *Am J Med*. 1988;85:152-158.
- Cole MC, Grossman ME. Disseminated histoplasmosis presenting as tongue nodules in a patient infected with human immunodeficiency virus. *Cutis*. 1995;55:104-106.
- Cohen PR, Bank DE, Silvers DN, et al. Cutaneous lesions of disseminated histoplasmosis in human immunodeficiency virus-infected patients. *J Am Acad Dermatol*. 1990;23:422-428.
- Studdard J, Sneed WF, Taylor MR, et al. Cutaneous histoplasmosis. *Am Rev Respir Dis*. 1976;113:689-693.
- Cohen PR, Grossman ME, Silvers DN. Disseminated histoplasmosis and human immunodeficiency virus infection. *Int J Dermatol*. 1991;30:614-622.
- Angius AG, Viviani MA, Muratori S, et al. Disseminated histoplasmosis presenting with cutaneous lesions in a patient with acquired immunodeficiency syndrome. *J Eur Acad Dermatol Venereol* 1998;10:182-185.
- Bellman B, Berman B, Saska H, et al. Cutaneous histoplasmosis in AIDS patients in south Florida. *Int J Dermatol*. 1997;36:599-603.
- Barton EN, Roberts L, Ince WE, et al. Cutaneous histoplasmosis in the acquired immune deficiency syndrome—a report of three cases from Trinidad. *Trop Geogr Med*. 1988;40:153-157.
- Chaker MB, Cockerell CJ. Concomitant psoriasis, seborrheic dermatitis, and disseminated cutaneous histoplasmosis in a patient infected with human immunodeficiency virus. *J Am Acad Dermatol*. 1993;29:311-313.
- Eidbo J, Sanchez RL, Tschen JA, et al. Cutaneous manifestations of histoplasmosis in the acquired immune deficiency syndrome. *Am J Surg Pathol*. 1993;17:110-116.
- Hazelhurst JA, Vismer HF. Histoplasmosis presenting with unusual skin lesions in acquired immunodeficiency syndrome (AIDS). *Br J Dermatol*. 1985;113:345-348.
- Greenberg RG, Berger TG. Progressive disseminated histoplasmosis in acquired immune deficiency syndrome: presentation as a steroid-responsive dermatosis. *Cutis*. 1989;43:535-538.
- Krunic A, Calonje E, Jevtovic D, et al. Primary localized cutaneous histoplasmosis in a patient with acquired immunodeficiency syndrome. *Int J Dermatol*. 1995;34:558-562.
- Cohen PR, Held JL, Grossman ME, et al. Disseminated histoplasmosis presenting as an ulcerated verrucous plaque in a human immunodeficiency virus-infected

- man: report of a case possibly involving human-to-human transmission of histoplasmosis. *Int J Dermatol*. 1991;30:104-108.
23. Wasserteil V, Jimenez-Acosta FJ, Kerdel FA. Disseminated histoplasmosis presenting as a rosacea-like eruption in a patient with the acquired immunodeficiency syndrome. *Int J Dermatol*. 1990;29:649-650.
 24. Silverman AK, Gilbert SC, Watkins D, et al. Panniculitis in an immunocompromised patient. *J Am Acad Dermatol*. 1991;24:912-914.
 25. Farr B, Beacham BE, Atuk NO. Cutaneous histoplasmosis after renal transplantation. *South Med J*. 1981;74:635-637.
 26. Lucas AO. Cutaneous manifestations of African histoplasmosis. *Br J Dermatol*. 1970;82:435-447.
 27. Odom RB, James WD, Berger TG, eds. *Andrew's Diseases of the Skin*. Philadelphia, Pa: WB Saunders Co; 2000:394-395.
 28. Giessel M, Rau JM. Primary cutaneous histoplasmosis: a new presentation. *Cutis*. 1980;25:152-154.
 29. Tosh PE, Balhuzien J, Yates JL. Primary cutaneous histoplasmosis. *Arch Intern Med*. 1964;114:118-119.
 30. Tesh RB, Schneidau JD Jr. Primary cutaneous histoplasmosis. *N Engl J Med*. 1966;275:597-599.
 31. Cott GR, Smith TW, Hinthorn DR, et al. Primary cutaneous histoplasmosis in immunosuppressed patient. *JAMA*. 1979;242:456-457.
 32. Ramdial PK, Mosam A, Ncoza DC, et al. Disseminated cutaneous histoplasmosis in patients infected with human immunodeficiency virus. *J Cutan Pathol*. 2002;29:215-225.
 33. Wheat J, Sarosi G, McKinsey D, et al. Practice guidelines for the management of patients with histoplasmosis. Infectious Disease Society of America. *Clin Infect Dis*. 2000;30:688-695.
 34. McKinsey DS, Wheat LJ, Cloud GA, et al. Itraconazole prophylaxis for fungal infections in patients with advanced human immunodeficiency virus infection: randomized, placebo-controlled, double-blind study. National Institute of Allergy and Infectious Diseases Mycoses Study Group. *Clin Infect Dis*. 1999;28:1049-1056.

DISCLAIMER

The opinions expressed herein are those of the authors and do not necessarily represent the views of the sponsor or its publisher. Please review complete prescribing information of specific drugs or combination of drugs, including indications, contraindications, warnings, and adverse effects before administering pharmacologic therapy to patients.

FACULTY DISCLOSURE

The Faculty Disclosure Policy of the Albert Einstein College of Medicine requires that faculty participating in a CME activity disclose to the audience any relationship with a pharmaceutical or equipment company that might pose a potential, apparent, or real conflict of interest with regard to their contribution to the activity. Any discussions of unlabeled or investigational use of any commercial product or device not yet approved by the US Food and Drug Administration must be disclosed.