

Cutaneous Sarcoidosis at Sites of Previous Laser Surgery

Tanya Kormeili, MD; Victor Neel, MD, PhD; Ronald L. Moy, MD

A 33-year-old patient was referred for evaluation and treatment of enlarging scars in areas where full-face carbon dioxide (CO₂) laser resurfacing had been performed previously. The patient denied any systemic illness and was in good health at the time of presentation. This is a case report of isolated sarcoidosis limited to the skin associated with CO₂ laser resurfacing.

Cutis. 2004;73:53-55.

Case Report

A 33-year-old white man initially presented with hypertrophic scars on his left glabellar region and left upper lip, which had been sustained in an automobile accident several years ago. The patient also had facial scars secondary to a childhood eruption of varicella. He underwent CO₂ laser resurfacing to reduce the appearance of the facial scars. However, 2 years after treatment, the scars on his forehead enlarged, and the patient returned for further treatment.

The patient's medical history was remarkable only for keloids. He had no systemic illnesses. Findings from the physical examination revealed an aggregate of several erythematous indurated plaques, with minor scaling on the left glabellar region, nose, cheek, and periorbital area at the sites of the previous scars (Figure 1). Unfortunately for the patient, serial intralesional injections with triamcinolone proved ineffective for the treatment of his scars.

Subsequently, a biopsy of one of the lesions was performed and revealed a dense, diffuse aggregation of histiocytes arranged into discrete tubercles with surrounding mononuclear cells, consistent with a diagnosis of cutaneous sarcoidosis (Figure 2). Polarizing microscopy and stains for acid-fast bacillus, periodic acid–Schiff, Fite, and Giemsa all provided negative results.

Laboratory studies failed to demonstrate any evidence of systemic sarcoidosis. Serum angiotensin-converting enzyme levels were within reference range, and hilar lymphadenopathy was not detected on chest radiograph.

Comment

The diagnosis of sarcoidosis is one of exclusion, where infectious etiologies including fungi, mycobacteria, and spirochetes have been ruled out. The differential diagnosis for sarcoidosis also includes tuberculoid leprosy, Crohn disease, rosacea, as well as foreign body granulomatous diseases such as silicosis.¹⁻⁵

Sarcoidosis has been documented at sites of previous scars due to venipuncture, folliculitis, ritualistic scarification, tattoos, and surgeries.⁶⁻¹⁶ Sarcoidal tissue also has been found at sites of scarring due to herpes zoster.¹⁷ Most patients who present with scar sarcoidosis also have systemic sarcoidosis, mostly with pulmonary involvement including bilateral hilar lymphadenopathy and restrictive pulmonary disease. These patients also demonstrate laboratory evidence of systemic sarcoidosis, such as elevated serum angiotensin-converting enzyme levels, as well as hypercalcemia.

To the best of our knowledge, this is the first reported case of scar sarcoidosis secondary to laser resurfacing of the skin. The mechanisms by which the use of laser can reactivate previous scars and stimulate the process of sarcoid granuloma formation are unclear. In addition, this case is unique and unusual in that no evidence of systemic involvement has been identified. Only 2 cases of isolated cutaneous involvement of sarcoidosis have

Accepted for publication March 27, 2003.

Dr. Kormeili is from the UCLA School of Medicine, Los Angeles, California. Dr. Neel is from the Division of Dermatologic Surgery, Massachusetts General Hospital, and Harvard Medical School, both in Boston. Dr. Moy is from the Veteran's Administration Medical Center and UCLA School of Medicine, both in Los Angeles.

The authors report no conflict of interest.

Reprints: Ronald L. Moy, MD, 100 UCLA Medical Plaza, Suite 590, Los Angeles, CA 90073 (e-mail: rmoy@ucla.edu).




Figure 1. Erythematous plaques on the left glabella, periorbital regions, and nose.

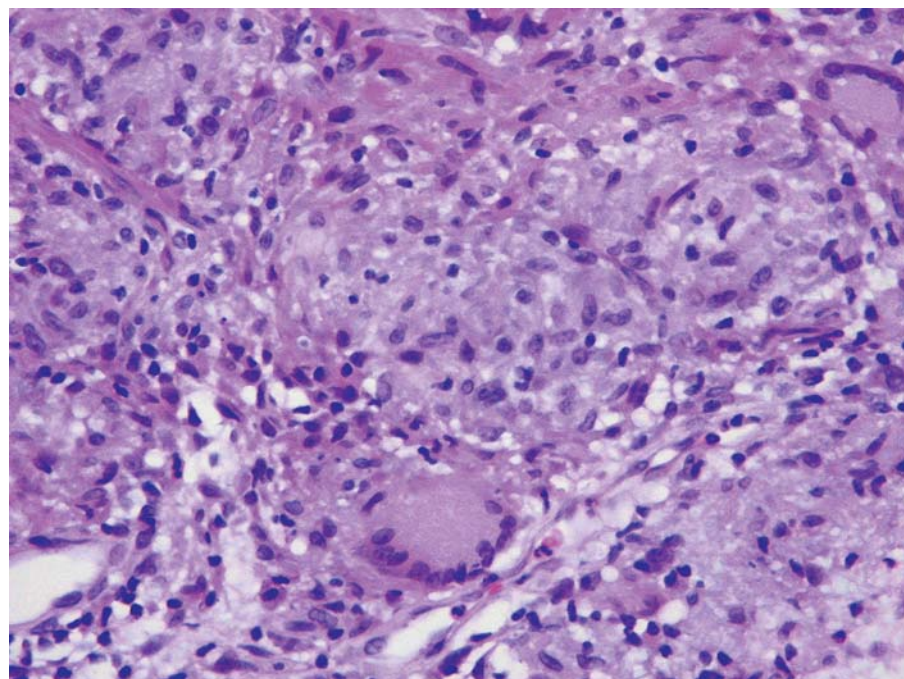


Figure 2. Aggregation of histiocytes arranged into discrete tubercles with surrounding mononuclear cells, consistent with a diagnosis of cutaneous sarcoidosis (H&E, original magnification $\times 200$).

been documented. In 1978, Condon and O'Sullivan¹⁸ described the case of a 34-year-old man with a scar on his upper lip since childhood, who had noticed swelling and enlargement of this scar for some years before presentation. Although results of a biopsy of the lesion were consistent with sarcoidosis, no other evidence of systemic disease was noted. Bisaccia et al¹⁷ described a second case, in which a 70-year-old woman presented with several erythematous-to-violaceous papules along a C5-C6 dermatomal distribution, 2 to 3 mm in diameter,

2 months after contracting brachial palsy as a result of herpes zoster. All clinical and laboratory studies, as well as results from chest radiography and liver ultrasonography, were within reference range. In addition, no osteolytic lesions of the hands and feet were detected on radiographs. Spirometry and ophthalmologic consultations did not reveal any abnormalities. Results of Mantoux test and other skin tests were all negative.¹⁹

It is not clear whether previously inactive scars develop features of sarcoidosis as a result of primary

systemic sarcoidosis, or whether isolated cases of sarcoidosis to the skin without any systemic involvement are a separate entity. Further studies are needed to better understand the pathophysiology and progression of cutaneous sarcoidosis.

Moreover, cutaneous and systemic sarcoidosis should be considered as a contraindication to laser resurfacing of the face. If a previously existing facial scar enlarges, biopsy might be indicated to rule out cutaneous sarcoidosis.

REFERENCES

1. Sharma OP. Cutaneous manifestations of disease in other organ systems. In: Fitzpatrick TB, Austen KF, Wolff K, et al, eds. *Dermatology in General Medicine*. 4th ed. New York, NY: McGraw-Hill Inc; 1993:2221-2228.
2. Mehregan A, Hashimoto K, Mehregan D, et al. Predominately mononuclear granulomas. In: *Pinkus' Guide to Dermatohistopathology*. 6th ed. East Norwalk, Conn: Appleton & Lange Inc; 1995:312-316.
3. Hood AF, Kwan TH, Mihm MC, et al. Granulomas and granulomatous inflammation. In: *Primer of Dermatopathology*. 2nd ed. Toronto, Canada: Little, Brown & Co; 1993:258-259.
4. Mutasim D. Subepidermal bullous diseases. In: Farmer ER, Hood AF, eds. *Pathology of the Skin*. 2nd ed. New York, NY: McGraw-Hill Inc; 2000:249-273.
5. Domonkos AN, Arnold HL, Odom RB. Reticulosis. In: *Andrew's Diseases of the Skin: Clinical Dermatology*. Philadelphia, Pa: WB Saunders Co; 1982:882-909.
6. Cutaneous sarcoidosis in venipuncture sites. *Br Med J*. 1973;1:547.
7. Hancock BW. Cutaneous sarcoidosis in blood donation venipuncture sites. *Br Med J*. 1972;4:706-708.
8. Burgdorf WH, Hoxtell EO, Bart BJ. Sarcoid granulomas in venipuncture sites. *Cutis*. 1979;24:52-53.
9. Caro I. Scar sarcoidosis. *Cutis*. 1983;32:531-533.
10. Ingber A, Klinken V. Scar sarcoidosis [letter]. *Clin Exp Dermatol*. 1984;9:532.
11. Alabi GO, George AO. Cutaneous sarcoidosis and tribal scarifications in West Africa. *Int J Dermatol*. 1989;28:29-31.
12. Nayar M. Sarcoidosis on ritual scarification. *Int J Dermatol*. 1993;32:116-118.
13. Murdoch SR, Fenton DA. Sarcoidosis presenting as nodules in both tattoos and scars. *Clin Exp Dermatol*. 1997;22:254-255.
14. Norton SA, Chesser RS, Fitzpatrick JE. Scar sarcoidosis in pseudofolliculitis barbae. *Mil Med*. 1991;156:369-371.
15. Healsmith MF, Hutchinson PE. The development of scar sarcoidosis at the site of desensitization injections. *Clin Exp Dermatol*. 1992;17:369-370.
16. Manz LA, Rodman OG. Reappearance of quiescent scars: sarcoidosis. *Arch Dermatol*. 1993;129:105-108.
17. Bisaccia E, Scarborough DA, Carr RD. Cutaneous sarcoid granuloma formation in herpes zoster scars. *Arch Dermatol*. 1983;119:788-789.
18. Condon KC, O'Sullivan D. Sarcoidosis in long standing facial scars. *Br J Plast Surg*. 1978;31:266-267.
19. Corazza M, Bacilieri S, Strumia R. Post-herpes zoster scar sarcoidosis [letter]. *Acta Derm Venereol*. 1999;79:95.