

# Kaposi's Varicelliform Eruption: A Case Report and Review of the Literature

Sasha C. Kramer, MD; Chadwick J. Thomas, MD; William B. Tyler, MD; Dirk M. Elston, MD

## GOAL

To gain a thorough understanding of Kaposi's varicelliform eruption

## OBJECTIVES

Upon completion of this activity, dermatologists and general practitioners should be able to:

1. Recognize Kaposi's varicelliform eruption.
2. Distinguish herpetic from vaccine-associated forms of Kaposi's varicelliform eruption.
3. Manage Kaposi's varicelliform eruption in affected patients.

**CME** Test on page 123.

This article has been peer reviewed and approved by Michael Fisher, MD, Professor of Medicine, Albert Einstein College of Medicine. Review date: January 2004.

This activity has been planned and implemented in accordance with the Essential Areas and Policies of the Accreditation Council for Continuing Medical Education through the joint sponsorship of Albert Einstein College of Medicine and Quadrant HealthCom, Inc. Albert Einstein College of Medicine

is accredited by the ACCME to provide continuing medical education for physicians.

Albert Einstein College of Medicine designates this educational activity for a maximum of 1 category 1 credit toward the AMA Physician's Recognition Award. Each physician should claim only that hour of credit that he/she actually spent in the activity.

This activity has been planned and produced in accordance with ACCME Essentials.

Drs. Kramer, Thomas, Tyler, and Elston report no conflict of interest. The authors report discussion of off-label use for intravenous vaccinia immune globulin under an investigational new drug protocol. Dr. Fisher reports no conflict of interest.

*Disseminated herpes or vaccinia in the setting of underlying skin diseases is known as Kaposi's varicelliform eruption (KVE). Patients typically present with disseminated vesicopustules in the areas of the most severe involvement of their underlying skin disease. We report a case of*

*eczema herpeticum in a woman with a long-standing history of atopic dermatitis (AD). This report also reviews the literature on eczema herpeticum and eczema vaccinatum (EV), summarizes clinical and histopathologic characteristics and treatment, and discusses the recommendations of the Centers for Disease Control and Prevention for smallpox vaccination.*

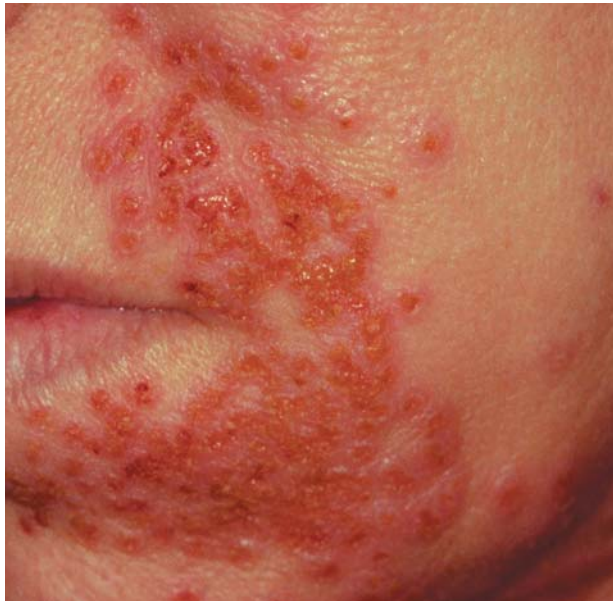*Cutis.* 2004;73:115-122.

Accepted for publication December 23, 2003.

Drs. Kramer and Thomas are residents from the Department of Dermatology, Dr. Tyler is an Associate in Pathology, and Dr. Elston is an Associate in Dermatology and Laboratory Medicine from the Departments of Dermatology and Pathology, Geisinger Medical Center, Danville, Pennsylvania.

Reprints: Dirk M. Elston, MD, Department of Dermatology, Geisinger Medical Center, MC 14-06, 100 N Academy Ave, Danville, PA 17822 (dmelston@geisinger.edu).

Patients with chronic inflammatory skin diseases, particularly atopic dermatitis (AD), are at risk for dissemination of cutaneous viral infections. Infection is most commonly caused by herpes simplex virus (HSV); however, it also may

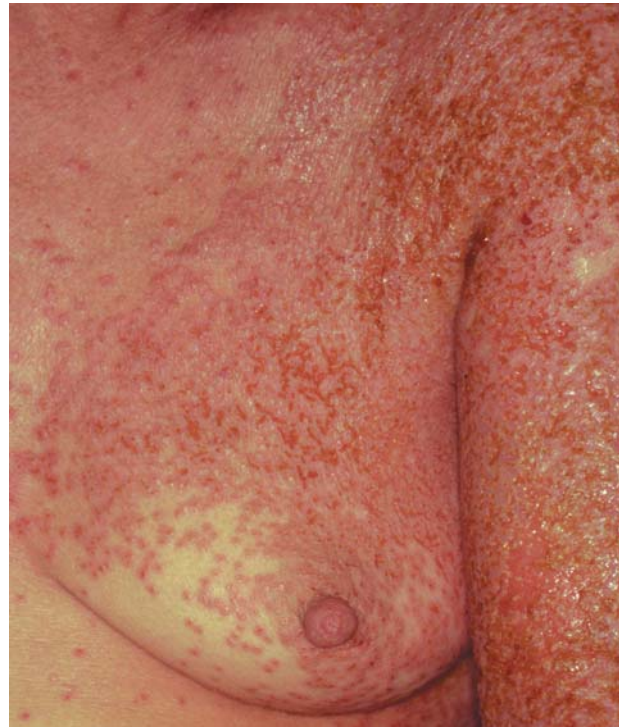

**Figure 1.** Confluent eroded vesicopapules on the cheek and chin.

occur with coxsackievirus or vaccinia. The term *Kaposi's varicelliform eruption* (KVE) is used synonymously with *eczema herpeticum* when HSV infects eczematous skin. When KVE occurs in a patient who has received or has come in close contact with someone who has received the smallpox vaccination, it also is referred to as *eczema vaccinatum* (EV). The pathogenesis of KVE may be related to impaired immune surveillance or simply may represent a mechanical phenomenon secondary to decreased epithelial barrier function. As the threat of bioterrorism with smallpox increases, physicians must address the question of safety when vaccination is considered in individuals with a history of atopy.

### Case Report

A 40-year-old woman with long-standing AD presented with a 5-day history of painful vesicles that had started on her right arm and gradually spread to involve the rest of her body. She had been evaluated by a physician and had been placed on prednisone, cephalexin, and triamcinolone without improvement. The patient did not have any preceding history of oral ulcerations or erosions but did report a history of intermittent "cold sores." On examination, her face, chest, arms, abdomen, back, and upper thighs were packed with confluent vesicopapules; some areas were eroded and weeping a yellow serous fluid (Figures 1 through 3). Direct fluorescent antibody (DFA) test yielded positive results of HSV-1 and HSV-2. A diagnosis of *eczema herpeticum* was made, and treatment with valacyclovir and cephalexin was initiated.



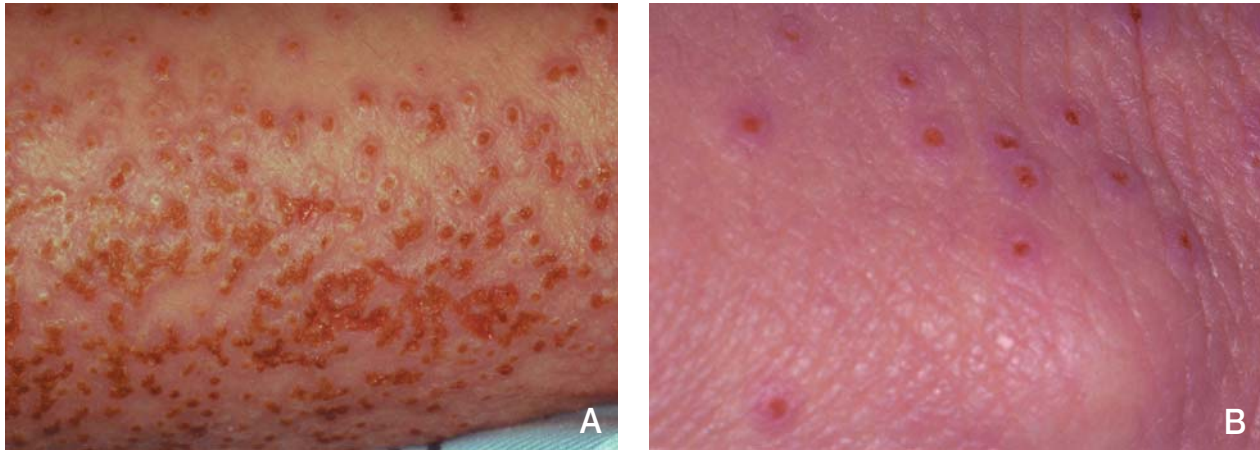
**Figure 2.** Numerous vesicles with prominent erosion and crusting present on the trunk.

Results of a bacterial culture yielded *Staphylococcus* and *Streptococcus* species. Biopsy results confirmed cytopathic changes diagnostic of herpesvirus infection with focal keratinocyte necrosis and acantholysis (Figures 4 and 5).

### Comment

KVE was first described in 1887 by Moritz Kaposi who was Professor and Chairman of Dermatology at the University of Vienna School of Medicine.<sup>1</sup> Kaposi initially thought the condition was secondary to a fungal infection, but the discovery of inclusion bodies histologically suggested a viral etiology.<sup>2</sup> The term KVE is now used to describe disseminated herpes simplex, vaccinia, or coxsackievirus in the setting of certain underlying skin diseases.<sup>1</sup>

*Eczema herpeticum* is a term often used synonymously with HSV-associated KVE because eczema is the most common underlying skin condition seen in KVE.<sup>1</sup> KVE also has been reported to occur in the setting of Darier disease,<sup>3,4</sup> cutaneous T-cell lymphoma,<sup>5</sup> pityriasis rubra pilaris,<sup>6</sup> familial benign chronic pemphigus,<sup>7</sup> congenital ichthyosiform erythroderma, seborrheic dermatitis, Wiskott-Aldrich syndrome,<sup>8</sup> psoriasis, and lupus erythematosus.<sup>9</sup> Additionally, KVE has been reported in patients who have disruption of the epidermal barrier either as a result of irritant contact dermatitis caused by vigorous scrubbing



**Figure 3.** Individual umbilicated vesicopustules (A and B).

of the face with a facial cleanser,<sup>10</sup> following a skin graft,<sup>11</sup> in the setting of second-degree burns,<sup>12</sup> or after dermabrasion.<sup>2</sup> It also has been reported to occur in the setting of multiple myeloma.<sup>13</sup>

The literature presents conflicting data regarding immunologic defects in response to herpesvirus infection in patients with AD. Although it has been suggested that patients with AD have depressed cell-mediated immunity to HSV, studies have failed to confirm this.<sup>14,15</sup> Some authors have postulated that decreased numbers of circulating natural killer cells and a decrease of IL-2 receptors cause patients with atopic eczema to be more susceptible to herpetic infection.<sup>15</sup> It may be that the spread of infection is related purely to mechanical factors rather than to immune surveillance.

KVE can present in a primary form or a recurrent form.<sup>16</sup> The primary form presents with clusters of umbilicated vesicles and vesicopustules that usually occur in areas where skin has been most affected by the underlying skin disease.<sup>17</sup> The lesions gradually spread and are accompanied by systemic symptoms such as fever, malaise, and lymphadenopathy.<sup>1</sup> Milder cases may have lesions limited to the head and neck.<sup>16</sup> Over time, the vesicles may become hemorrhagic and later develop into erosions that can become secondarily infected.<sup>17</sup> More severe cases can result in scarring. Recurrent cases usually are more limited with fewer systemic symptoms.<sup>16</sup>

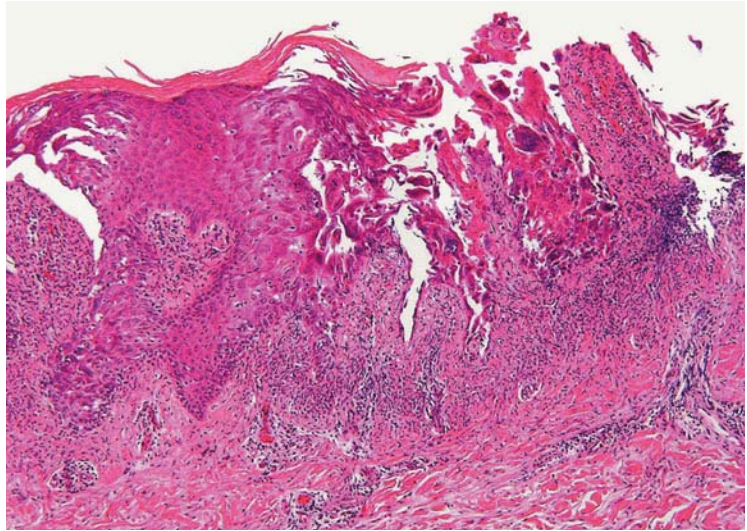
Herpetic keratitis is a serious ocular sequela. Fortunately, despite the frequent involvement of vesicopustules on the face, ocular herpetic infection is rare in the setting of KVE.<sup>18</sup> One study reported 3 patients with KVE with positive HSV conjunctival culture results but no visible ocular disease.<sup>8</sup> KVE can be associated with viremia and involvement of the lungs, liver, brain, and gastrointestinal tract.<sup>1</sup>

Prior to the availability of antiviral therapy, deaths occurred secondary to rhabdomyolysis and renal failure.<sup>18</sup> Bacterial infection of the eroded skin can progress to bacterial sepsis.

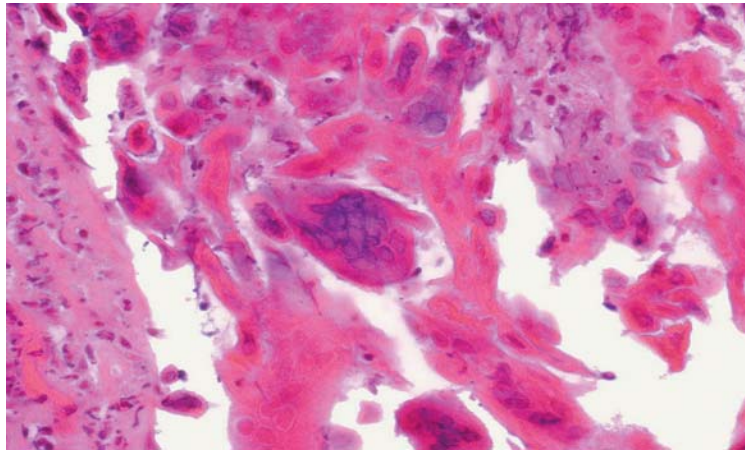
### Differential Diagnosis and Diagnosis

The differential diagnosis of eczema herpeticum includes impetigo, varicella-zoster virus, and EV.<sup>1</sup> A diagnosis of eczema herpeticum should be considered in the presence of multiple umbilicated papules, vesicopustules, or erosions in a patient with underlying skin disease. The presence of herpesvirus infection often can be confirmed by the presence of ballooning degeneration and nuclear cytopathic effect in multinucleated cells seen on a Tzanck test. The characteristic nuclear cytopathic effect includes peripheral margination of nucleoplasm so that it creates a basophilic rim at the edge of the nucleus. When possible, samples should be obtained from the floor of a freshly unroofed vesicopustule.<sup>19</sup> More specific identification of the causative agent can be confirmed by viral culture or DFA testing of a smear. Smears for DFA testing generally are obtained with a No. 15 blade from the floor of a fresh vesicle. A round smear requires fewer drops of reagent than a long thin smear and is therefore more cost-effective. DFA results generally can be obtained within 1 to 4 hours.

Biopsy results of eczema herpeticum will show changes characteristic of herpesvirus infection; namely ballooning degeneration of keratinocytes with multinucleated epithelial cells and nuclear cytopathic effect.<sup>19</sup> Polymerase chain reaction from tissue or smears may be performed to extract herpes DNA to distinguish among the herpes subtypes. Immunostaining also can be performed using monoclonal antibodies directed against HSV-1 and HSV-2.<sup>19</sup>



**Figure 4.** Epidermal acanthosis with acantholytic change in eczema herpeticum (H&E, original magnification  $\times 100$ ).



**Figure 5.** A multinucleated epithelial cell with nuclear molding and ground glass chromatin characteristic of the cytopathic changes of herpesvirus infection in eczema herpeticum (H&E, original magnification  $\times 400$ ).

## Treatment

The mainstay of therapy for eczema herpeticum is oral therapy with nucleoside analogue antiviral medications such as acyclovir, valacyclovir, and famciclovir (Table). The activation of acyclovir requires a thymidine kinase that is specific for the herpesvirus family. The drug is triphosphorylated to a form that inhibits viral DNA polymerase, resulting in irreversible viral DNA chain termination.<sup>20</sup> Absorption of oral acyclovir is unreliable in neonates.

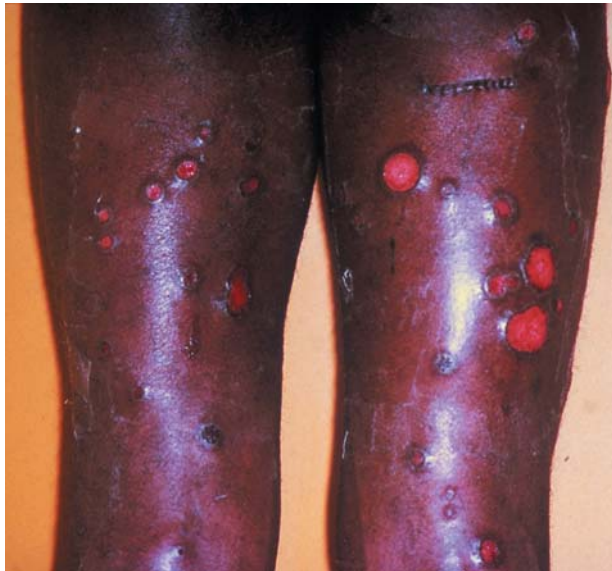Valacyclovir is an ester prodrug of acyclovir that has a bioavailability 3 to 5 times greater than oral acyclovir. Oral dosing of valacyclovir can result in blood levels similar to those obtained with parenteral acyclovir.<sup>20</sup> Valacyclovir generally is dosed twice daily for herpes simplex and 3 times daily for herpes zoster.<sup>20</sup> Famciclovir is a prodrug of penciclovir that also must be triphosphorylated to become active. It too has greater bioavailability than acyclovir and generally is dosed 3 times daily. Parenteral therapy may be preferred over oral therapy in the case of immunosuppression or inability to take oral medication.

Intravenous acyclovir has been reported to cause phlebitis and reversible renal insufficiency from crystalline nephropathy. This risk can be minimized with intravenous fluid hydration.<sup>21</sup> Acyclovir-resistant herpes can be treated with foscarnet, which is not a nucleoside analogue but instead acts by blocking pyrophosphate-binding sites on viral polymerases.<sup>20</sup>

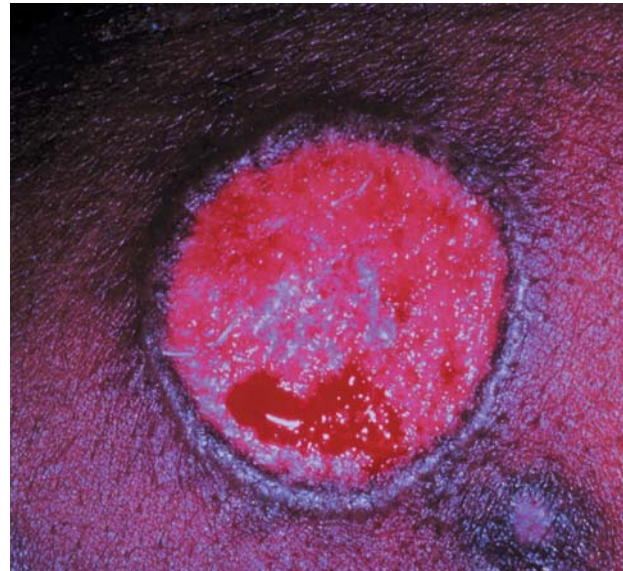Secondary bacterial infection is common in eczema herpeticum and should be treated with appropriate antibiotics. Most infections are caused by staphylococcal and streptococcal species. Despite the rare occurrence of herpetic keratitis, some authors recommend that patients with eczema herpeticum be treated with a topical ophthalmic antiviral medication in addition to systemic antiviral therapy; however, oral acyclovir alone has been shown to be beneficial in the treatment of HSV keratitis.<sup>8,22</sup>

## Eczema Vaccinatum

In the early 1970s, the United States ended routine vaccination for smallpox because of the eradication of naturally occurring disease. With the emerging threat



**Figure 6.** Generalized vaccinia. Reprinted with permission from Len Sperling, MD.



**Figure 7.** A closer view of an individual lesion of vaccinia. Reprinted with permission from Len Sperling, MD.

### Oral Dosing Regimen for Eczema Herpeticum in Immunocompetent Patients (Dosing as in Herpes Zoster)\*

#### Acyclovir

800 mg 5 times daily for 7–10 days or until evidence of healing is noted

#### Valacyclovir

1 g 3 times daily for 7–10 days or until evidence of healing is noted

#### Famciclovir

500 mg 3 times daily for 7 days or until evidence of healing is noted

\*Data are from Evans et al.<sup>20</sup>

of bioterrorism, the issue of vaccination recently has come to the forefront as a public health concern. Smallpox vaccine is made from live vaccinia virus. Immunity induced by vaccinia is protective against the causative agent in smallpox, the variola virus. Although very successful in the campaign against variola, the smallpox vaccine earned the reputation of having one of the highest rates of vaccine-associated adverse events. Dermatologic complications include localized skin reactions without systemic symptoms,

generalized skin reactions without systemic symptoms (eg, erythema multiforme minor), and generalized skin reactions with systemic symptoms (eg, EV, generalized vaccinia) (Figures 6 and 7).<sup>23</sup> Data from the late 1960s show that adverse events to vaccinia inoculation are 10 times more likely to occur in those receiving the vaccine for the first time compared with those receiving a repeat vaccination. It is estimated that approximately 40% of the current US population are immunologically naive to vaccinia.<sup>22</sup>

Like eczema herpeticum, EV occurs in the setting of a compromised epidermal barrier. AD, regardless of disease activity, is a risk factor for developing EV. Although many primary care providers do not distinguish between AD and other forms of eczema, AD is a genetic disease with immune defects that may predispose to the spread of the virus.<sup>23</sup> To reduce the risk of inadvertent inoculation of a patient with AD, the current recommendations of the Centers for Disease Control and Prevention (CDC) include any history of AD or eczema as a contraindication to receipt of smallpox vaccine.<sup>24</sup>

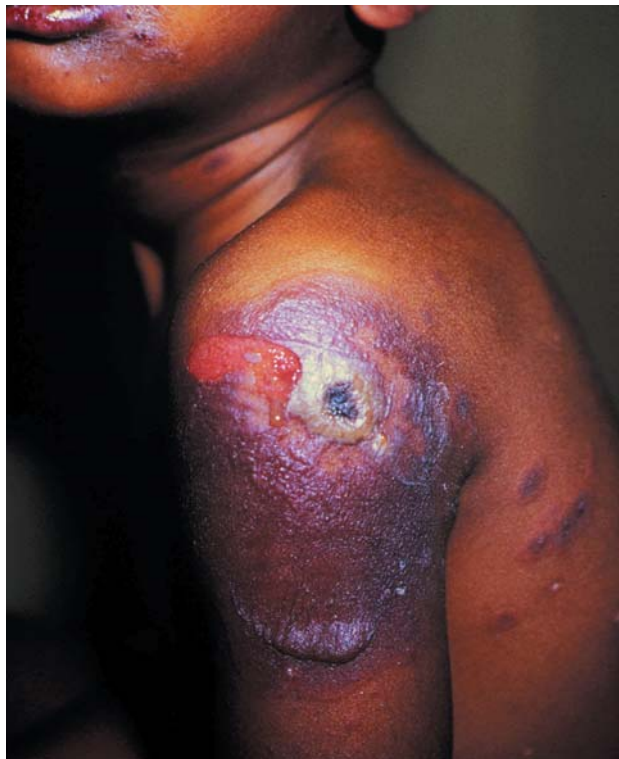EV presents with lesions distant from the inoculation site and may comprise umbilicated pustules, papules, vesicles, or erosions with a predilection for sites of previous AD lesions.<sup>24</sup> Following vaccination, characteristic lesions may appear concurrently with, or shortly after, lesions of the vaccination site (Figure 8).

A typical major reaction in a primary vaccine is marked by the formation of a papule, vesicle, ulcer, or crusted lesion surrounded by an area of induration on day 6 to 8 postvaccination. Most commonly, the

vaccination site progresses through papular, vesicular, pustular, and crusted stages, followed by separation of the crust and resultant scarring. The lesions of EV follow a similar clinical course. In cases of secondary transmission of vaccinia from a vaccinated individual to another person, the eruption of lesions typically occurs 5 to 19 days after exposure.<sup>25</sup> Confluent lesions are common in areas previously affected by AD and may cover the entire face or the antecubital and popliteal fossae. Patients often are systemically ill with fever, generalized lymphadenopathy, and malaise.<sup>24</sup>

EV should be suspected in any patient with a history of AD who exhibits the typical clinical presentation and either has been vaccinated against smallpox or has had contact with an individual who has been vaccinated 5 to 20 days prior to presentation. The diagnosis primarily is clinical and is based on the characteristic clinical presentation in combination with a history of exposure to vaccinia. Histopathologic findings are characteristic and include reticular degeneration of the epidermis with intranuclear and intracytoplasmic inclusion bodies (Figure 9). Although a presumptive diagnosis is sufficient to warrant treatment, the CDC can perform confirmatory tests. The presence of an *Orthopoxvirus* can be confirmed by electron microscopy of vesicular or pustular fluid, polymerase chain reaction, and restriction fragment length polymorphism testing.<sup>26</sup> The CDC recommends that immunologic studies for T-cell function and IgE levels be performed in cases of EV in an effort to identify particular laboratory markers characteristic of those patients at increased risk of development of EV so that the morbidity and mortality attributable to this complication may be lessened.<sup>23</sup>

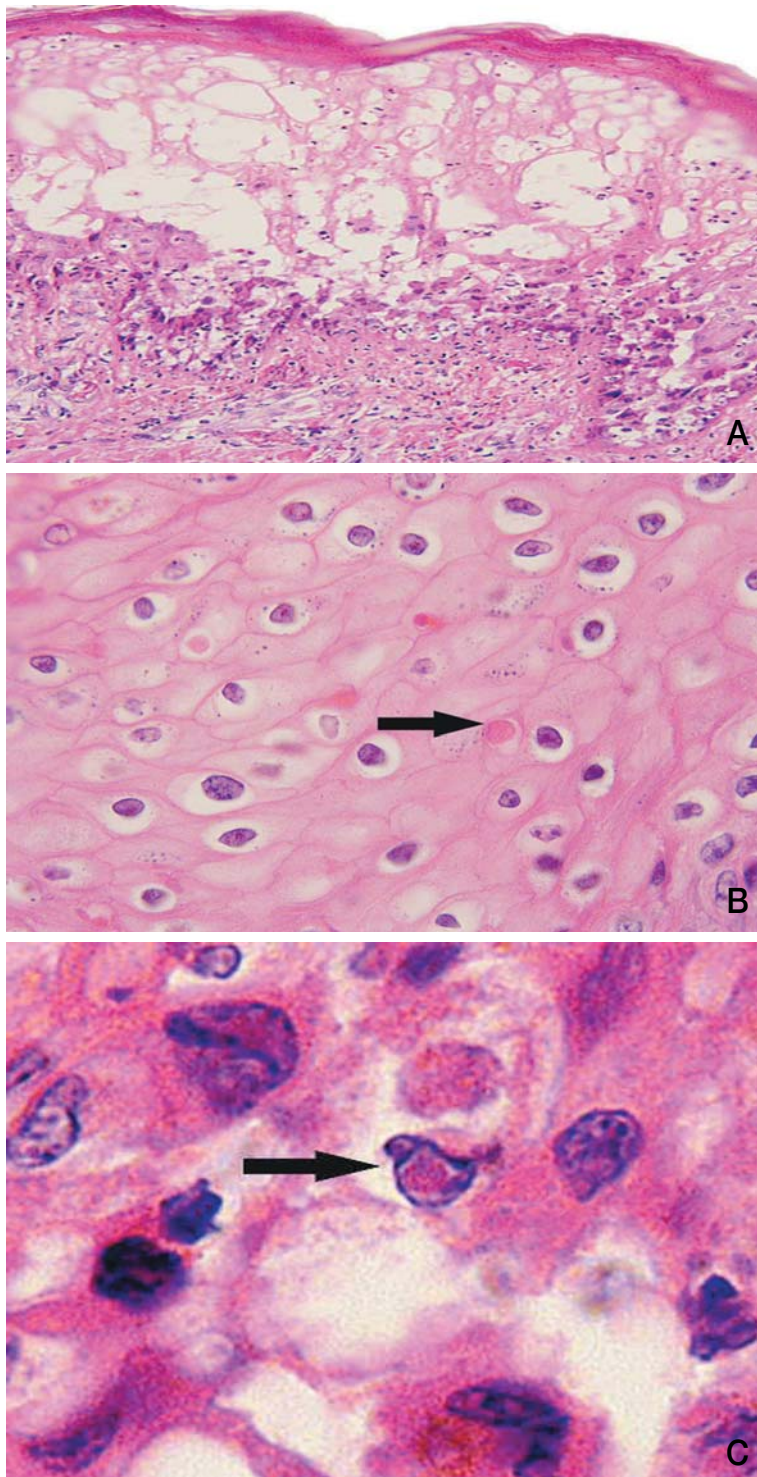
Treatment for established cases of EV consists of vaccinia immune globulin, hemodynamic support, wound care, and careful monitoring for the presence of superimposed infections. Vaccinia immune globulin is produced from the plasma of vaccinated individuals and contains a high titer of vaccinia-neutralizing antibody. Historically, the initial dose of vaccinia immune globulin used for patients with EV was 0.6 to 1.0 mL/kg administered by intramuscular injection.<sup>26</sup> For patients with severe extensive lesions, 5 to 10 mL/kg was administered intramuscularly in divided doses. The necessity for use of an intramuscular preparation stemmed from the high level of aggregated protein it contained. An intravenous preparation with a lower level of aggregated protein is now available through the CDC, with dosing guided by the investigational new drug protocol under which



**Figure 8.** Localized reaction following vaccinia immunization. Reprinted with permission from Brooke Army Medical Center teaching file.

it is being used. Guidelines for hemodynamic support are similar to those used for patients with sepsis. Electrolytes should be monitored closely with prompt correction of any abnormalities. Meticulous skin care is imperative in patients diagnosed with EV and is similar to that used for burn patients. Patients with EV also are at risk for the development of secondary skin infections and may require appropriate antibacterial and antifungal treatment as guided by results of skin and blood cultures.<sup>24</sup>

The prevention of EV is dependent on a thorough medical history and appropriate screening. In a pre-exposure setting, smallpox vaccination is contraindicated in any person with a current or past history of eczema or AD, regardless of disease severity. Individuals with close contact to anyone with a history of these conditions also should not receive the vaccine. The CDC recommends that smallpox vaccination also be deferred for those with active acute, chronic, or exfoliative skin conditions that disrupt the epidermis. The guidelines specifically mention Darier disease in a potential vaccine candidate or in a household contact with active disease.<sup>27</sup> In the event of a smallpox outbreak, the CDC will distribute specific modifications regarding populations to be vaccinated.<sup>26</sup>



**Figure 9.** Smallpox. Scanning magnification showing epidermal acanthosis with prominent reticular degeneration (the histologic findings of eczema vaccinatum are identical)(A). High magnification reveals a small intracytoplasmic eosinophilic Guarnieri body (B). High magnification of the cells at the base of the epidermis shows an individual intranuclear inclusion shown at the tip of the arrow (C)(H&E, original magnifications  $\times 100$ ,  $\times 400$ , and  $\times 1000$ ).

EV is one of the most severe adverse events that may occur following smallpox vaccination. As the current smallpox vaccination program accelerates, it is important for healthcare workers to screen potential vaccine candidates for a current or past history of skin disease. With uncertainties regarding

the most effective indicators for detection of patients at highest risk, many questions surround vaccination protocols in a pre-exposure setting. The development of immunologic studies capable of accurately identifying those at increased risk for EV following smallpox vaccination could have a

significant impact on the incidence of this devastating complication.<sup>23</sup> A better understanding of subtle underlying immunologic differences that increase susceptibility in particular individuals could lead to new, more specific recommendations concerning individuals who should not receive the vaccine.

## REFERENCES

1. Mooney MA, Janniger CK, Schwartz RA. Kaposi's varicelliform eruption. *Cutis*. 1994;53:243-245.
2. Bestue M, Cordero A. Kaposi's varicelliform eruption in a patient with healing peribuccal dermabrasion. *Dermatol Surg*. 2000;26:939-940.
3. Fortuno Y, Marcoval J, Kruger M, et al. Unilateral Darier's disease complicated by Kaposi's varicelliform eruption limited to the affected skin. *Br J Dermatol*. 2002;146:1102-1103.
4. Verner E, Shteinfeld M, Zuckerman F. Eczema herpeticum in a patient with Darier's disease during treatment with etretinate. *J Am Acad Dermatol*. 1985;13:678-680.
5. Masessa JM, Grossman ME, Knobler EH. Kaposi's varicelliform eruption in cutaneous T cell lymphoma. *J Am Acad Dermatol*. 1989;21:133-135.
6. Ng SK, Ang CB, Tham A. Kaposi's varicelliform eruption in a patient with pityriasis rubra pilaris. *J Am Acad Dermatol*. 1992;27:263.
7. Flint ED, Spencer DM, Wilkin JK. Eczema herpeticum in association with familial benign chronic pemphigus. *J Am Acad Dermatol*. 1993;28:257-258.
8. Fivenson DP, Breneman DL, Wander AH. Kaposi's varicelliform eruption, absence of ocular involvement. *Arch Dermatol*. 1990;126:1037-1039.
9. Saraswat A, Ratho RK, Kumar B. Two unusual cases of Kaposi's varicelliform eruption. *Acta Derm Venereol*. 2002;82:138-139.
10. Morganroth GS, Glick SA, Perez MI, et al. Kaposi's varicelliform eruption complicating irritant contact dermatitis. *J Am Acad Dermatol*. 1992;27:1030-1031.
11. Manders SM, Chetty BV. Eczema herpeticum occurring in autografted skin. *J Am Acad Dermatol*. 1991;24:509-510.
12. Nishimura M, Maekawa M, Hino Y. Kaposi's varicelliform eruption: development in a patient with a healing second-degree burn. *Arch Dermatol*. 1984;120:799-800.
13. Fukuzawa M, Oguchi S, Saida T. Kaposi's varicelliform eruption of an elderly patient with multiple myeloma. *J Am Acad Dermatol*. 2000;42:921-922.
14. Vestey JP, Howie SEM, Norval M, et al. Immune responses to herpes simplex virus in patients with facial herpes simplex and those with eczema herpeticum. *Br J Dermatol*. 1998;118:775-782.
15. Goodyear HM, McLeish P, Randall S, et al. Immunological studies of herpes simplex virus infection in children with atopic eczema. *Br J Dermatol*. 1996;134:85-93.
16. Wheeler CE Jr, Abele DC. Eczema herpeticum primary and recurrent. *Arch Dermatol*. 1966;93:162-171.
17. Cumpacker CS. Herpes simplex. In: Freedberg IM, Eisen AZ, Wolff K, et al, eds. *Fitzpatrick's Dermatology in General Medicine*. Vol 1. New York, NY: McGraw Hill; 1999:2414-2425.
18. Bork K, Brauninger W. Increasing incidence of eczema herpeticum: analysis of seventy-five cases. *J Am Acad Dermatol*. 1988;19:1024-1029.
19. Elder D, Elenitsas R, Jaworsky C, et al, eds. *Lever's Histopathology of the Skin*. Philadelphia, Pa: Lippincott, Williams and Wilkins; 1990.
20. Evans TY, Vander Straten MR, Carrasco DA, et al. Systemic antiviral agents. In: Wolverton, SE, ed. *Comprehensive Dermatologic Therapy*. Philadelphia, Pa: WB Saunders Co; 2001:85-106.
21. Jawitz JC, Hines HC, Moshell AN. Treatment of eczema herpeticum with systemic acyclovir. *Arch Dermatol*. 1985;121:274-275.
22. Schwartz GS, Holland EJ. Oral acyclovir for the management of herpes simplex virus keratitis in children. *Ophthalmology*. 2000;107:278-282.
23. Engler RJM, Kenner J, Leung DYM. Smallpox vaccination: risk considerations for patients with atopic dermatitis. *J Allergy Clin Immunol*. 2002;100:357-365.
24. Department of Health and Human Services. Smallpox vaccination and adverse reactions. *MMWR*. 2003;52:1-28.
25. Centers for Disease Control and Prevention. Smallpox vaccination and adverse events training module. Available at: [http://www.bt.cdc.gov/training/smallpoxvaccine/reactions/ec\\_vac.html](http://www.bt.cdc.gov/training/smallpoxvaccine/reactions/ec_vac.html). Accessed May 1, 2003.
26. Centers for Disease Control and Prevention. Negative staining electron microscopic protocol for rash illness. Available at: <http://www.bt.cdc.gov/agent/smallpox/lab-testing/pdf/em-rash-protocol.pdf>. Accessed May 1, 2003.
27. Centers for Disease Control and Prevention. Skin conditions that mean you should not get smallpox vaccine. Available at: <http://www.bt.cdc.gov/agent/smallpox/vaccination/skin-contras.asp>. Accessed May 1, 2003.

### DISCLAIMER

The opinions expressed herein are those of the authors and do not necessarily represent the views of the sponsor or its publisher. Please review complete prescribing information of specific drugs or combination of drugs, including indications, contraindications, warnings, and adverse effects before administering pharmacologic therapy to patients.

### FACULTY DISCLOSURE

The Faculty Disclosure Policy of the Albert Einstein College of Medicine requires that faculty participating in a CME activity disclose to the audience any relationship with a pharmaceutical or equipment company that might pose a potential, apparent, or real conflict of interest with regard to their contribution to the activity. Any discussions of unlabeled or investigational use of any commercial product or device not yet approved by the US Food and Drug Administration must be disclosed.