

# Phaeohyphomycosis Caused by *Coniothyrium*

Kimberly Siu, BA; Allan K. Izumi, MD

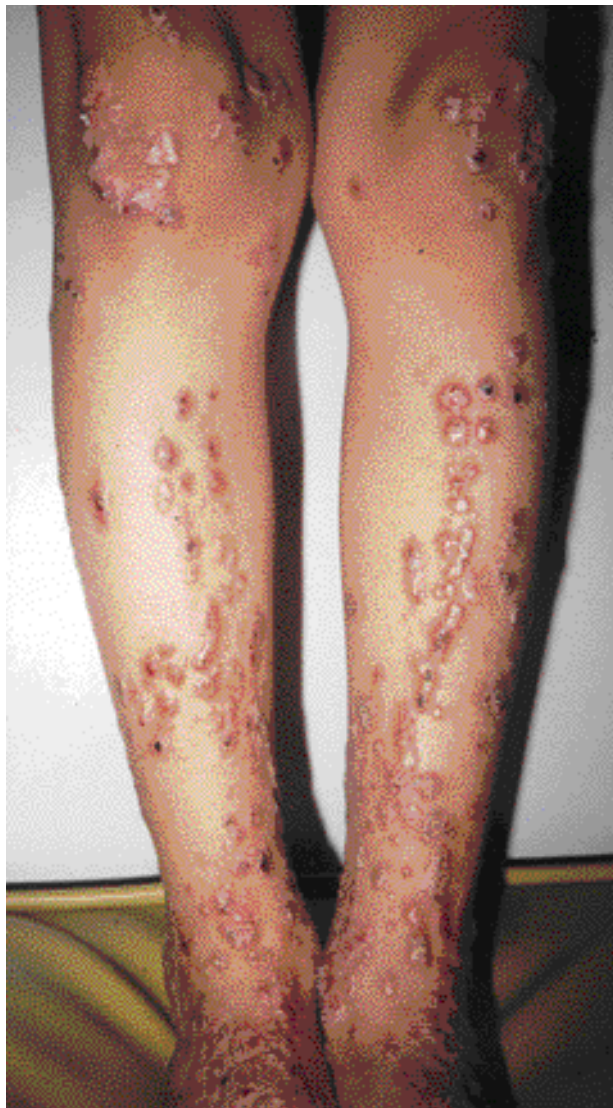
*A 49-year-old immunosuppressed heart transplant recipient developed a superficial and subcutaneous granulomatous infection caused by Coniothyrium. The patient responded to a combination of surgical excision and antifungal agents. We review phaeohyphomycotic infections including this second report of a Coniothyrium infection.*

*Cutis. 2004;73:127-130.*

Phaeohyphomycosis is a group of mycotic infections caused by dematiaceous fungi. Ajello coined the term *phaeohyphomycosis* to distinguish it from chromoblastomycosis.<sup>1</sup> The infection may present as superficial cutaneous, subcutaneous, or systemic infections that typically are introduced into the skin by trauma in individuals who are either immunocompetent or immunocompromised.<sup>1,2</sup> *Coniothyrium* is a type of phaeohyphomycotic infection in humans and is a saprophytic fungus that causes disease in roses and sugar cane.<sup>3</sup> This is a report of an immunosuppressed heart transplant recipient with diabetes with both a superficial and deep granulomatous infection caused by *Coniothyrium*. To our knowledge, the only other report of *Coniothyrium* causing human infection was found in a patient with acute myelogenous leukemia.<sup>3</sup>

## Case Report

A 49-year-old immunocompromised male heart transplant recipient with diabetes presented to our clinic. He was on a therapeutic regimen of azathioprine, mycophenolate mofetil, cyclosporine, prednisone, and insulin and had an 8-month history of gradually enlarging granulomatous annular and nodular plaques on his legs and knees. His history also was significant for a cytomegalovirus infection



**Figure 1.** Granulomatous nodular and subcutaneous plaques on the legs.

and disseminated herpes zoster. The granulomatous lesions developed at the sites of abrasions sustained during a motorcycle accident on a dirt-coral road. He was prescribed a short course of oral fluconazole prior to his office visit.

---

Accepted for publication November 7, 2003.

From the John A. Burns School of Medicine, University of Hawaii at Manoa.

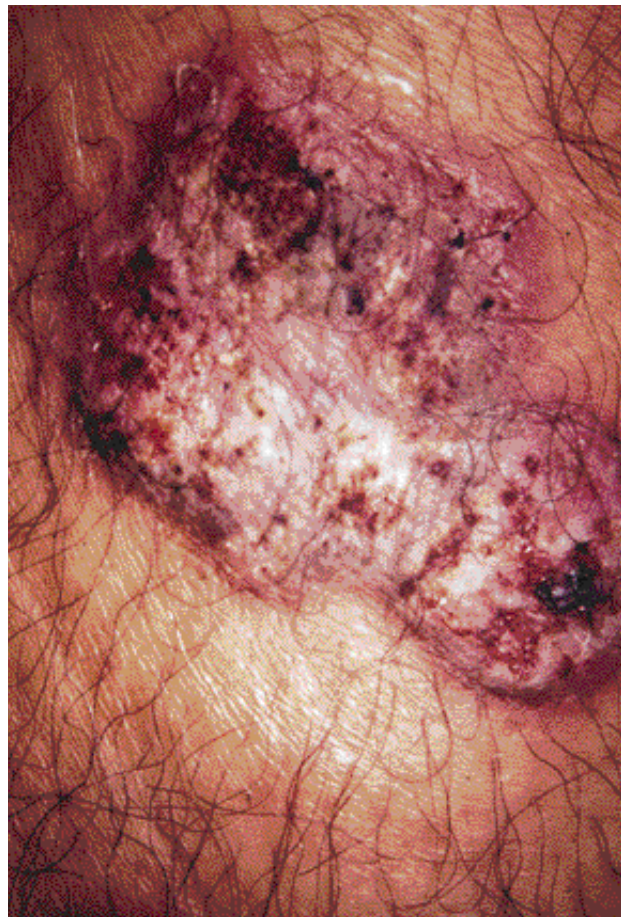The authors report no conflict of interest.

No reprints available from the authors.

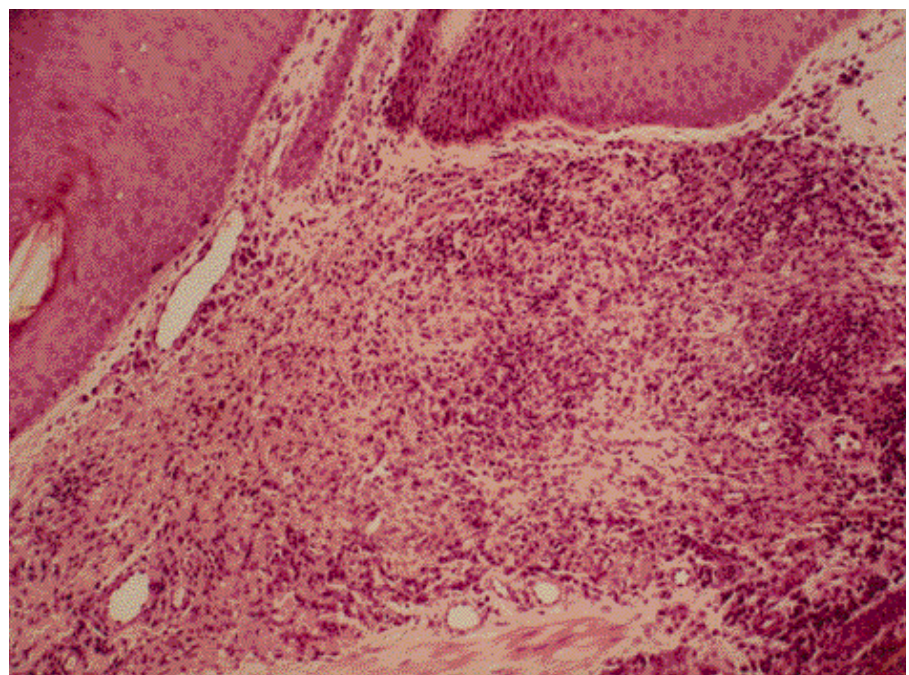
An examination revealed numerous superficial subcutaneous granulomatous nodules and plaques along the legs and knees. The surface of each plaque was studded with crusted, hemorrhagic, grainy particles (Figures 1 and 2). There was no regional lymphadenopathy.

Results of a punch biopsy of the skin showed surface crusting and pseudoepitheliomatous hyperplasia of the epidermis (Figure 3). There was a superficial middermal granulomatous infiltrate. No Medlar bodies were present. Results of a periodic acid–Schiff stain showed positive budding hyphae and spores within the dermis (Figure 4). Results of acid-fast and Gram stains were negative. A Sabouraud glucose agar culture from the tissue grew a moist white colony within 48 hours. The culture subsequently was identified as *Coniothyrium-Microsphaeropsis* complex.

Over a 2-year period, the patient was treated with surgery and a variety of systemic antifungals. He initially was prescribed a regimen of fluconazole 200 to 600 mg daily for 4 to 5 months with a poor response. His regimen was switched to itraconazole 200 mg daily because in vitro testing showed that the organism was relatively resistant to fluconazole (fluconazole minimum inhibitory concentration at 72 hours: 32 mcg/mL). He was prescribed fluconazole again after 3 months because of disease progression. The lesions gradually cleared over the following 10 months. A year later, while still on a therapeutic regimen of fluconazole, the patient

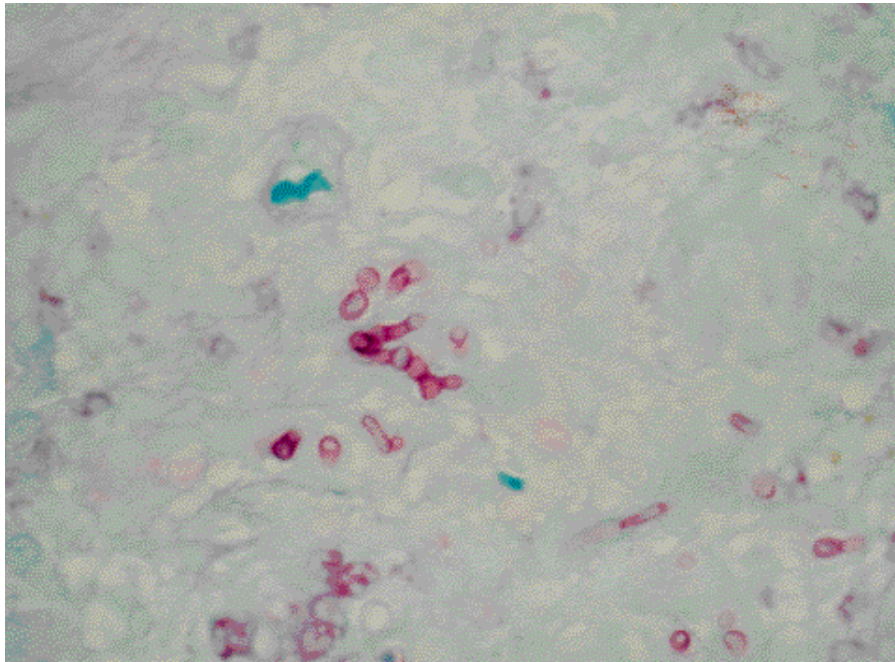


**Figure 2.** Granulomatous plaque studded with crusted, hemorrhagic, grainy particles.

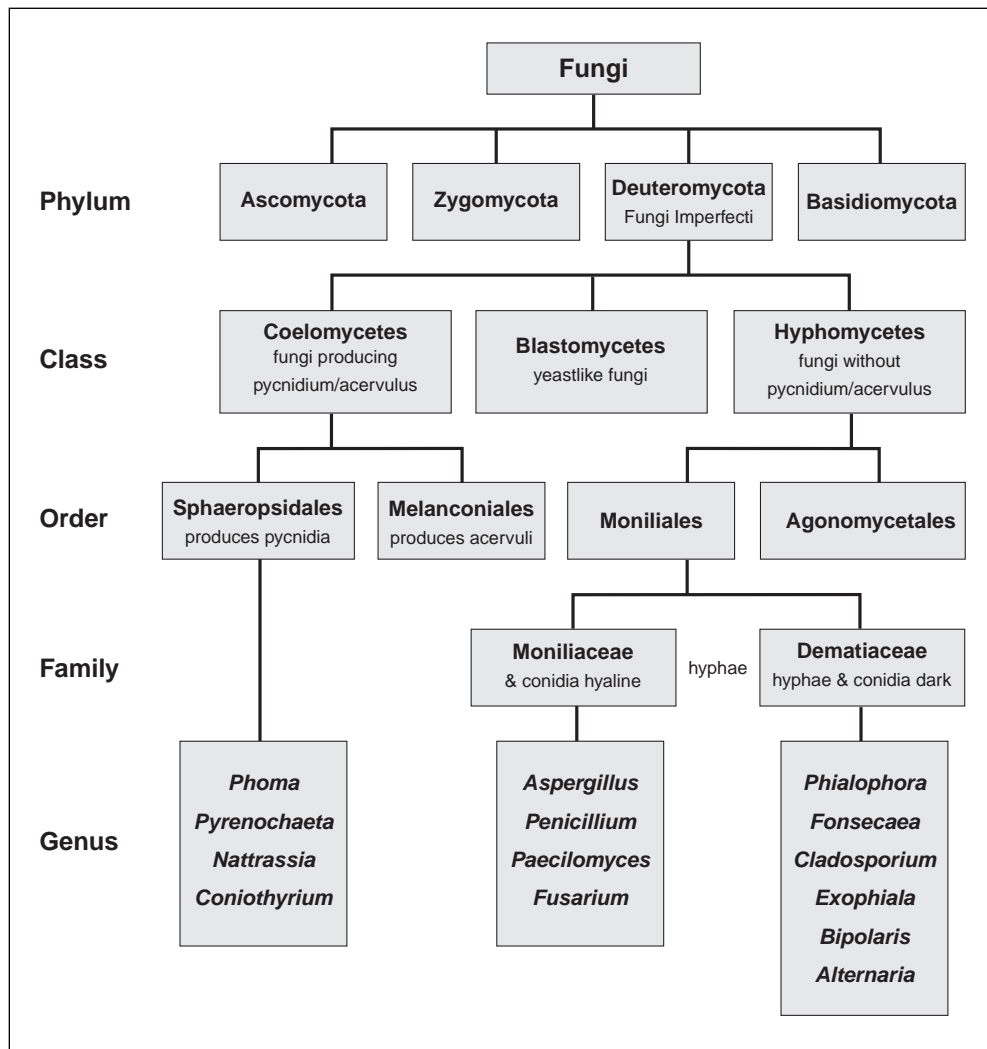


**Figure 3.** Pseudoepitheliomatous hyperplasia and granulomatous dermal infiltrate (H&E, original magnification  $\times 80$ ).





**Figure 4.** Periodic acid–Schiff stain results show positive spores and budding hyphae in superficial dermis (original magnification ×40).



**Figure 5.** Fungi classification.

developed new lesions that required the surgical removal of larger granulomatous nodules combined with intravenous amphotericin B 50 mg 5 times weekly that was tapered over 3 months, at which time the lesions resolved. The patient remained clear of symptoms after 4 months and was subsequently lost to follow-up.

### Comment

Phaeohyphomycotic agents are reviewed by Rinaldi<sup>4</sup> who lists 57 genera and 104 species. The reported cases of phaeohyphomycosis cover a wide spectrum of fungi primarily involving 2 phyla (Ascomycota and Deuteromycota)(Figure 5). Infections involving the Ascomycota phylum are uncommon, with the majority of phaeohyphomycotic agents belonging to the Deuteromycota phylum, which includes the Hyphomycetes and Coelomycetes classes. Cases of Hyphomycetes infections reported most commonly, but not inclusively listed, include *Bipolaris*, *Phialophora*, and *Exophiala*.<sup>4,5</sup> Coelomycetes infections are less common and include *Phoma* (13 cases),<sup>6</sup> *Nattrassia* (5 cases),<sup>7,8</sup> and a single report of *Coniothyrium* infection in a patient with acute myelogenous leukemia.<sup>3</sup> The taxonomic and culturing features of these fungi are beyond the scope of this paper; however, they are categorized in several standard references.<sup>9,10</sup>

Treatment of phaeohyphomycotic infections includes surgical excision combined with oral antifungals including ketoconazole, itraconazole, clotrimazole, econazole, miconazole, griseofulvin, amphotericin B, and 5-fluorocytosine.<sup>4,11-13</sup> Optimal dosage and duration of treatment for these infections are difficult to assess, and in vitro antifungal susceptibility testing is not always predictive of in vivo success, as demonstrated in this case.

*Acknowledgment*—Sara K.K. Meibom, MD, contributed to the research of this paper.

### REFERENCES

1. Ajello L, Georg LK, Steigbigel RT, et al. A case of phaeohyphomycosis caused by a new species of *Phialophora*. *Mycologia*. 1974;66:490-498. Cited by: McGinnis M. Chromoblastomycosis and phaeohyphomycosis: new concepts, diagnosis, and mycology. *J Am Acad Dermatol*. 1983;8:1-16.
2. Stone M, Rosen T, Clarridge J. Phaeohyphomycosis due to coelomycetes organisms. *Int J Dermatol*. 1988;27:404-405.
3. Kiehn TR, Polsky B, Punithalingam E, et al. Liver infection caused by *Coniothyrium fuckelii* in a patient with acute myelogenous leukemia. *J Clin Microbiol*. 1987;25:2410-2412.
4. Rinaldi M. Phaeohyphomycosis. *Dermatol Clin*. 1996;14:147-153.
5. Kwon-Chung K, Bennett J. *Medical Mycology*. Philadelphia, Pa: Lea and Febiger; 1992.
6. Goihman-Yahr M. Subcutaneous phaeohyphomycosis caused by *Phoma* species [letter]. *Int J Dermatol*. 1999;38:873-880.
7. Frankel D, Rippon J. *Hendersonula toruloidea* infection in man. *Mycopathologia*. 1989;105:175-186.
8. Sigler L, Summerbell R, Poole L, et al. Invasive *Nattrassia mangiferae* infections: case report, literature review, and therapeutic and taxonomic appraisal. *J Clin Microbiol*. 1997;35:433-440.
9. Sutton BC. *Coelomycetes: Fungi Imperfecti With Pycnidia, Acervuli and Stromata*. Kew, Surrey: Commonwealth Mycological Institute; 1980.
10. Guarro J, Gene J, Stchigel A. Developments in fungal taxonomy. *Clin Microbiol Rev*. 1999;12:454-500.
11. McGinnis M. Infections caused by black fungi. *Arch Dermatol*. 1987;123:1300-1302.
12. Hurley MA, Asafiran B. Subcutaneous phaeohyphomycosis: overview and case report. *J Foot Ankle Surg*. 1997;36:230-235.
13. Sharkey P, Graybill J, Rinaldi M, et al. Itraconazole treatment of phaeohyphomycosis. *J Am Acad Dermatol*. 1990;23:577-586.