

# Treatment of Severe, Recalcitrant, Major Aphthous Stomatitis With Adalimumab

Justin Vujevich, MD; Matthew Zirwas, MD

## GOAL

To understand recurrent aphthous stomatitis (RAS) to better manage patients with the condition

## OBJECTIVES

Upon completion of this activity, dermatologists and general practitioners should be able to:

1. Describe the 3 types of RAS lesions.
2. Discuss the pathogenesis of RAS.
3. Explain the treatment options for RAS.

**CME** Test on page 104.

This article has been peer reviewed and approved by Michael Fisher, MD, Professor of Medicine, Albert Einstein College of Medicine. Review date: July 2005.

This activity has been planned and implemented in accordance with the Essential Areas and Policies of the Accreditation Council for Continuing Medical Education through the joint sponsorship of Albert Einstein College of Medicine and Quadrant HealthCom, Inc. Albert Einstein College of Medicine

is accredited by the ACCME to provide continuing medical education for physicians.

Albert Einstein College of Medicine designates this educational activity for a maximum of 1 category 1 credit toward the AMA Physician's Recognition Award. Each physician should claim only that credit that he/she actually spent in the activity.

This activity has been planned and produced in accordance with ACCME Essentials.

Dr. Vujevich reports no conflict of interest. Dr. Zirwas is a consultant for and has received an unrestricted educational grant from Amgen. The authors discuss off-label use of adalimumab, etanercept, pentoxifylline, and thalidomide. Dr. Fisher reports no conflict of interest.

*We describe an 18-year-old man with a 7-year history of severe major aphthous stomatitis refractory to multiple standard therapies who responded completely to therapy with adalimumab, a fully humanized monoclonal antibody against tumor necrosis factor  $\alpha$  (TNF- $\alpha$ ).*

*Cutis.* 2005;76:129-132.

Accepted for publication April 18, 2005.

Dr. Vujevich is a dermatology resident, and Dr. Zirwas is Assistant Professor of Dermatology, both in the Department of Dermatology, University of Pittsburgh Physicians, Pennsylvania.

Reprints: Matthew Zirwas, MD, Falk Medical Bldg, 3601 Fifth Ave, 5th Floor, Pittsburgh, PA 15213 (e-mail: zirwasm@upmc.edu).

**R**ecurrent aphthous stomatitis (RAS) is a common disease of the oral mucosa, affecting approximately 1 in 5 individuals during their lifetime.<sup>1</sup> Clinically, these lesions manifest as painful erythematous erosions or ulcerations typically on nonkeratinized mucosa.

RAS lesions are classified into 3 groups, based on size. Minor recurrent aphthous ulcers, the most common variety, are painful ulcers less than 1.0 cm in diameter that occur on nonkeratinized mucosa. The second class, major recurrent aphthous ulcers, are similar in clinical appearance but are larger (>1.0 cm), more painful, longer lasting, and heal with scarring. The third group is herpetiform RAS.

These painful ulcers frequently cluster on the lower lip, heal without scarring, occur more often in women, and have a later onset of presentation.

The etiology of RAS is poorly understood and appears to be multifactorial. Predisposing factors such as heredity,<sup>2</sup> trauma,<sup>3</sup> emotional stress,<sup>4</sup> reactivation of latent virus,<sup>5</sup> hypersensitivity to certain foods,<sup>6</sup> and immunoglobulin A (IgA) deficiency<sup>7</sup> may contribute to the pathogenesis of individual cases.

RAS is typically an isolated finding but may occur as one manifestation of a systemic disease. Associated diseases include Behçet syndrome; Reiter syndrome; vitamin deficiency; inflammatory bowel disease; mouth and genital ulcers with inflamed cartilage (MAGIC) syndrome; periodic fever, aphthous stomatitis, pharyngitis, and adenitis (PFAPA) syndrome; Sweet syndrome; and cyclic neutropenia.<sup>8</sup> Although the immunopathogenesis of RAS is unknown, most evidence suggests RAS is a T-cell-mediated disorder resulting in the secretion of cytokines that have a cytotoxic effect on oral mucosa cells.

There appears to be an abnormality of cytokine expression in patients with RAS, with tumor necrosis factor  $\alpha$  (TNF- $\alpha$ ) being one of the overexpressed cytokines. Borra et al<sup>9</sup> utilized complementary DNA microarray analysis to demonstrate a helper T cell subtype 1-predominant immune response profile in aphthous ulcer specimens compared with control oral mucosa. Buno et al<sup>10</sup> examined the pattern of cytokine messenger RNA expression in lesional and normal mucosa from patients with RAS, and reported higher levels of the messenger RNAs of the helper T cell subtype 1 proinflammatory cytokines interleukin 2, interferon  $\gamma$ , and TNF- $\alpha$  in lesional biopsy specimens of patients with RAS compared with mucosa from healthy controls. Natah et al<sup>11</sup> reported that TNF- $\alpha$ -containing cells were more numerous in RAS oral specimens compared with control oral mucosa. Finally, Taylor et al<sup>12</sup> demonstrated enhanced release of TNF- $\alpha$  by peripheral blood monocytes in patients with RAS.

### Case Report

An 18-year-old man was referred to our clinic with a 7-year history of severe oral ulcerations. The lesions were extremely painful, were present on an essentially continuous basis, and healed with scarring. The ulcerations interfered with eating, drinking, and speaking. No relationship to trauma or food intake was noted.

The results of a review of symptoms were otherwise negative. Specifically, the patient had no gastrointestinal tract symptoms, fevers or chills,

ocular symptoms, genital ulcerations, or risk factors for human immunodeficiency virus. No amalgam or acrylic material was present in the mouth. Results of a physical examination revealed ulcers 1- to 2-cm in diameter with fibrinous bases and erythematous borders involving the buccal and labial mucosa (Figure, A), tongue, soft palate, and retropharynx.

Results of an oral biopsy demonstrated a mucosal ulceration with nonspecific inflammation. Test results measuring complete blood count; serum vitamins B<sub>1</sub>, B<sub>2</sub>, B<sub>6</sub>, and B<sub>12</sub>; serum folate and iron levels; and serum antinuclear antibodies were within reference range. The diagnostic evaluation also included a normal colonoscopy and esophagogastroduodenoscopy, with normal random mucosal biopsy results and a normal fundoscopic evaluation.

The patient's previous therapies included high-potency topical steroids, topical tacrolimus ointment, chlorhexidine rinses, topical tetracycline, topical lidocaine, oral colchicine (0.6 mg twice daily), oral dapsone (125 mg/d), oral azathioprine (250 mg/d), oral sulfasalazine, and oral prednisone ranging in doses of 10 to 60 mg. Only oral prednisone had been effective, and the dose required to ameliorate symptoms sufficiently to allow adequate oral intake and speech had averaged 40 mg/d over the previous 3 years, with no periods off prednisone during that time. Despite this dose of prednisone, an unintentional weight loss of 40 lb occurred secondary to decreased oral intake.

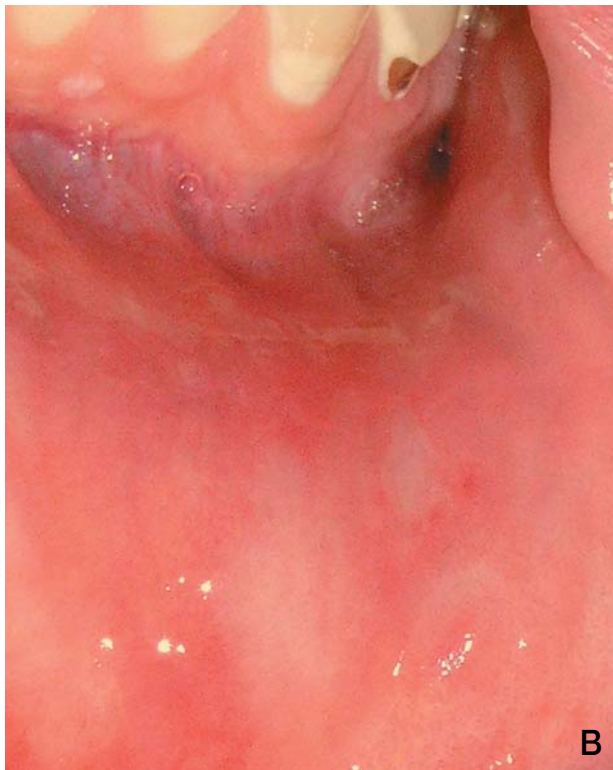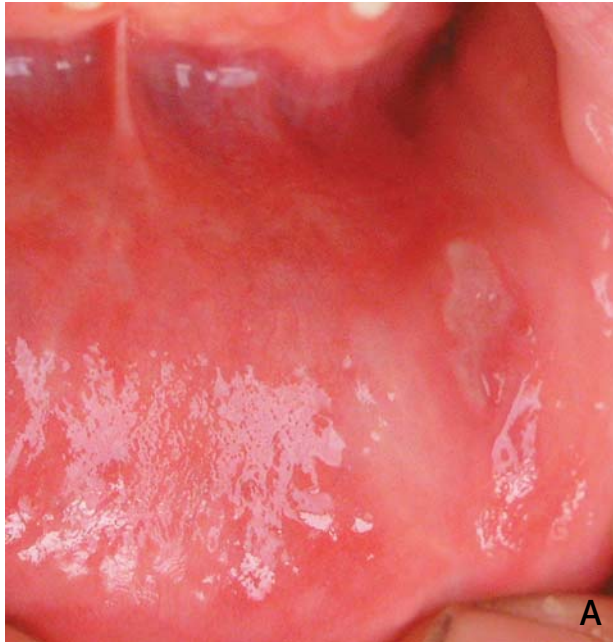
Based on the *in vitro* data showing up-regulation of TNF- $\alpha$  in RAS and a prior case report describing use of etanercept for RAS,<sup>13</sup> we decided to undertake a therapeutic trial of adalimumab, a monoclonal, fully human anti-TNF- $\alpha$  antibody, at a dosage of 40 mg injected subcutaneously every other week.

Two weeks after the first subcutaneous injection, our patient showed a 90% clinical improvement of ulcerations (Figure, B). Over the next several weeks, all remaining ulcerations had completely healed. After 4 months, our patient had no recurrence of ulcerations, and his therapy with oral prednisone was discontinued for the first time in 3 years. Our plan is to continue biweekly injections for a 6-month period, and if there is no recurrence of ulceration during this time, the interval between subcutaneous injections will be lengthened until the minimum required frequency of injections is achieved.

### Comment

Adalimumab is a recombinant, fully humanized IgG1 monoclonal antibody that binds specifically

to TNF- $\alpha$ , preventing the cytokine from binding to its p55 and p75 receptors and therefore neutralizing the activity of the cytokine.<sup>14</sup> It is approved by the US Food and Drug Administration for use in the treatment of moderate to severe rheumatoid



Major aphthous ulcer on the buccal and labial mucosa before (A) and 14 days after (B) the patient's first adalimumab injection.

arthritis in adults who have had an inadequate response to disease-modifying antirheumatic drugs. The recommended dosage in these patients is 40 mg injected subcutaneously every other week.

Anti-TNF- $\alpha$  therapies have shown success in the treatment of RAS. Pentoxifylline has been shown to reduce the number of recurrent aphthous ulcers in an open clinical trial.<sup>15</sup> Thalidomide has been reported to achieve up to a 50% remission in patients with recurrent aphthous ulcers in one crossover study versus placebo.<sup>16</sup>

Recent reports have shown successful treatment of RAS with TNF- $\alpha$  monoclonal antibody blocking agents. Robinson and Guitart<sup>13</sup> reported a 50-year-old woman with partial improvement in chronic RAS after biweekly subcutaneous injections of etanercept, a dimeric fusion protein combining the extracellular portion of the human TNF receptor (p75) linked to the Fc portion of IgG. Kaufman et al<sup>17</sup> reported dramatic improvement of RAS in patients with Crohn disease using a single 5 mg/kg intravenous infusion of infliximab, a chimeric TNF- $\alpha$  monoclonal IgG1 antibody composed of the mouse TNF- $\alpha$  receptor linked to the Fc portion of IgG.

To our knowledge, this is the first report demonstrating effectiveness of adalimumab for the treatment of RAS. There are several advantages to using this agent. First, it binds to TNF- $\alpha$  with greater affinity than does etanercept,<sup>18</sup> providing a more complete blockage of TNF- $\alpha$ . Second, it is dosed subcutaneously, making it more convenient for patients than infliximab, which requires an intravenous infusion. Finally, it is a fully humanized product, so the probability of neutralizing antibody development is low.

In summary, we present a patient with severe, debilitating major RAS who was recalcitrant to multiple standard therapies. The patient's lesions responded dramatically to subcutaneous adalimumab injections. We believe this agent has significant potential as a novel therapy for severe cases of RAS.

## REFERENCES

1. Stanley HR. Aphthous lesions. *Oral Surg Oral Med Oral Pathol Oral*. 1972;33:407-416.
2. Miller MF, Garfunkel AA, Ram CA, et al. The inheritance of recurrent aphthous stomatitis. observations on susceptibility. *Oral Surg Oral Med Oral Pathol*. 1980;49:409-412.
3. Wray D, Graykowski EA, Norkins AL. Role of mucosal injury in initiating recurrent aphthous stomatitis. *Br Med J (Clin Res Ed)*. 1981;283:1569-1570.

4. Ship II, Morris AL, Durocher RT, et al. Recurrent ulcerations and recurrent herpes labialis in a professional school student population. *Oral Surg Oral Med Oral Pathol.* 1960;13:1191-1202.
5. Eglin RP, Lehner T, Subak-Sharpe JH. Detection of DNA complementary to herpes-simplex virus in mononuclear cells from patients with Behçet's syndrome and recurrent oral ulcers. *Lancet.* 1982;18:1356-1361.
6. Thomas HC, Ferguson A, McLennan JG, et al. Food antibodies in oral disease: a study of serum antibodies to food proteins in aphthous ulceration and other oral diseases. *J Clin Pathol.* 1973;26:371-374.
7. Porter SR, Scully C. Orofacial manifestations in primary immunodeficiencies involving IgA deficiency. *J Oral Pathol Med.* 1993;22:117-119.
8. Scully C, Gorsky M, Lozada-Nur F. Aphthous ulcerations. *Dermatol Ther.* 2002;15:185-205.
9. Borra RC, Andrade PM, Silva ID, et al. The Th1/Th2 immune-type response of the recurrent aphthous ulceration analyzed by cDNA microarray. *J Oral Pathol Med.* 2004;33:140-146.
10. Buno IJ, Huff JC, Weston WL, et al. Elevated levels of interferon gamma, tumor necrosis factor alpha, interleukins 2, 4, and 5, but not interleukin 10, are present in recurrent aphthous stomatitis. *Arch Dermatol.* 1998;134:827-831.
11. Natah SS, Hayrinen-Immonen R, Hietanen J, et al. Immunolocalization of tumor necrosis factor-alpha expressing cells in recurrent aphthous ulcer lesions (RAU). *J Oral Pathol Med.* 2000;29:19-25.
12. Taylor LJ, Bagg J, Walker DM, et al. Increased production of tumour necrosis factor by peripheral blood leukocytes in patients with recurrent oral aphthous ulceration. *J Oral Pathol Med.* 1992;21:21-25.
13. Robinson ND, Guitart J. Recalcitrant, recurrent aphthous stomatitis treated with etanercept. *Arch Dermatol.* 2003;139:1259-1262.
14. Bang LM, Keating GM. Adalimumab: a review of its use in rheumatoid arthritis. *Biodrugs.* 2004;18:121-139.
15. Wahba-Yahav AV. Pentoxifylline in intractable recurrent aphthous stomatitis: an open trial. *J Am Acad Dermatol.* 1995;33:680-682.
16. Revuz J, Guillaume JC, Janier M, et al. Crossover study of thalidomide vs placebo in severe recurrent aphthous stomatitis. *Arch Dermatol.* 1990;126:923-927.
17. Kaufman I, Caspi D, Yeshurun D, et al. The effect of infliximab on extraintestinal manifestations of Crohn's disease. *Rheumatol Int.* August 12, 2004; [Epub ahead of print]. Available at: <http://www.springerlink.com/app/home/contribution.asp?wasp=439297a7d65044d9b5fdf6561240c0a2&referrer=parent&backto=issue,89,108,journal,1,52;linkingpublicationresults,1:101577,1>. Accessed February 10, 2005.
18. Khanna D, McMahon M, Furst D. Safety of tumour necrosis factor-alpha antagonists. *Drug Saf.* 2004;27:304-324.

**DISCLAIMER**

The opinions expressed herein are those of the authors and do not necessarily represent the views of the sponsor or its publisher. Please review complete prescribing information of specific drugs or combination of drugs, including indications, contraindications, warnings, and adverse effects before administering pharmacologic therapy to patients.

**FACULTY DISCLOSURE**

The Faculty Disclosure Policy of the Albert Einstein College of Medicine requires that faculty participating in a CME activity disclose to the audience any relationship with a pharmaceutical or equipment company that might pose a potential, apparent, or real conflict of interest with regard to their contribution to the activity. Any discussions of unlabeled or investigational use of any commercial product or device not yet approved by the US Food and Drug Administration must be disclosed.