

Resistant Scalp Folliculitis Secondary to *Demodex* Infestation

Angela M. Sanfilippo, MD; Joseph C. English III, MD

GOAL

To understand scalp folliculitis secondary to *Demodex* infestation to better manage patients with the condition

OBJECTIVES

Upon completion of this activity, dermatologists and general practitioners should be able to:

1. Describe the characteristics of *Demodex* mites.
2. Discuss the role of *Demodex* mites in rosacea and pustular folliculitis.
3. Identify treatment options for demodicosis.

CME Test on page 309.

This article has been peer reviewed and approved by Michael Fisher, MD, Professor of Medicine, Albert Einstein College of Medicine. Review date: October 2005.

This activity has been planned and implemented in accordance with the Essential Areas and Policies of the Accreditation Council for Continuing Medical Education through the joint sponsorship of Albert Einstein College of Medicine and Quadrant HealthCom, Inc. Albert Einstein College of Medicine

is accredited by the ACCME to provide continuing medical education for physicians.

Albert Einstein College of Medicine designates this educational activity for a maximum of 1 category 1 credit toward the AMA Physician's Recognition Award. Each physician should claim only that credit that he/she actually spent in the activity.

This activity has been planned and produced in accordance with ACCME Essentials.

Drs. Sanfilippo and English report no conflict of interest. The authors discuss off-label use for selenium sulfide 2.5% shampoo and sulfacetamide 10% plus sulfur 5% cream. Dr. Fisher reports no conflict of interest.

Folliculitis is a common complaint and its etiology may be related to a variety of factors. We examine a case involving a 57-year-old white man presenting with scalp erythema and folliculitis secondary to Demodex mite infestation. We discuss the pathophysiology of Demodex folliculitis, as well as the epidemiology, clinical manifestation, diagnosis, and treatment of this infection.

Cutis. 2005;76:321-324.

Accepted for publication August 17, 2005.

Dr. Sanfilippo is a dermatology resident and Dr. English is Assistant Professor of Dermatology, University of Pittsburgh Medical Center, Department of Dermatology, Pennsylvania. Reprints: Joseph C. English III, MD, University of Pittsburgh, Department of Dermatology, 190 Lothrop St, Suite 145, Lothrop Hall, Pittsburgh, PA 15213 (e-mail: englishjc@upmc.edu).

Folliculitis is a common complaint seen in dermatology practice. The differential diagnosis of folliculitis is broad and includes *Demodex* folliculitis. In humans, the *Demodex* mite species *Demodex folliculorum* and *Demodex brevis* have been found to inhabit the pilosebaceous unit. *D folliculorum* typically is found in the follicular infundibulum; *D brevis* exists in the sebaceous and meibomian glands.¹ Although the prevalence of *Demodex* approaches 100% in middle-aged and elderly adults,¹ mite density normally is low in healthy skin.² *Demodex* mites are considered pathogenic only when they are found in large numbers or in an intradermal location³; therefore, it has been suggested that *D folliculorum* may play a role in various papular and pustular eruptions of the

head and neck, such as demodicosis and rosacea.³ We examine a case of scalp folliculitis secondary to *Demodex* infection and the role that this organism plays in the pathogenesis of folliculitis, as well as the available treatment options.

Case Report

A 57-year-old white man presented to our department in June 2004 with an “infected scalp” and scalp irritation for 2 months. The patient was diagnosed with bacterial folliculitis and treated with clindamycin 1% gel twice daily for 1 month. He presented for follow-up in July 2004 with continued complaint of scalp pruritus and rash (Figure 1). Results of an examination showed a deep pink 10×7-cm plaque on the scalp with hyperkeratosis and pustules. An ectoparasite wet mount prepared from one of the pustules revealed the presence of several *Demodex* mites (Figure 2). The patient was treated with sulfacetamide 10% plus sulfur 5% cream twice daily, in addition to a 2-week course of selenium sulfide 2.5% shampoo once daily. When the patient was seen for follow-up in September 2004, his entire scalp had cleared (Figure 3). He was instructed to continue the selenium sulfide 2.5% shampoo twice weekly for 6 months to prevent recurrence.

Comment

The *Demodex* mite is a ubiquitous arthropod measuring approximately 0.1 to 0.4 mm in length.

Typically, it infests areas around the eyelids, nose, and ear canals in human hosts.⁴ The life cycle of the mite is 18 to 24 days. The female mite lays 20 to 24 eggs in a hair follicle where the eggs are nourished by the surrounding pilosebaceous unit. The eggs hatch and the nymphs continue to live in the follicle where their main source of food is human glandular secretions.⁵ The mite primarily is an

asymptomatic inhabitant of human pilosebaceous follicles and poses no harm to the host.¹

The role of *D folliculorum* in cutaneous disease in humans remains controversial. The pathogenicity is difficult to establish secondary to the localization of the disease, the widespread prevalence of infection with the *D folliculorum* mite, and the obligate nature of the parasite; therefore,

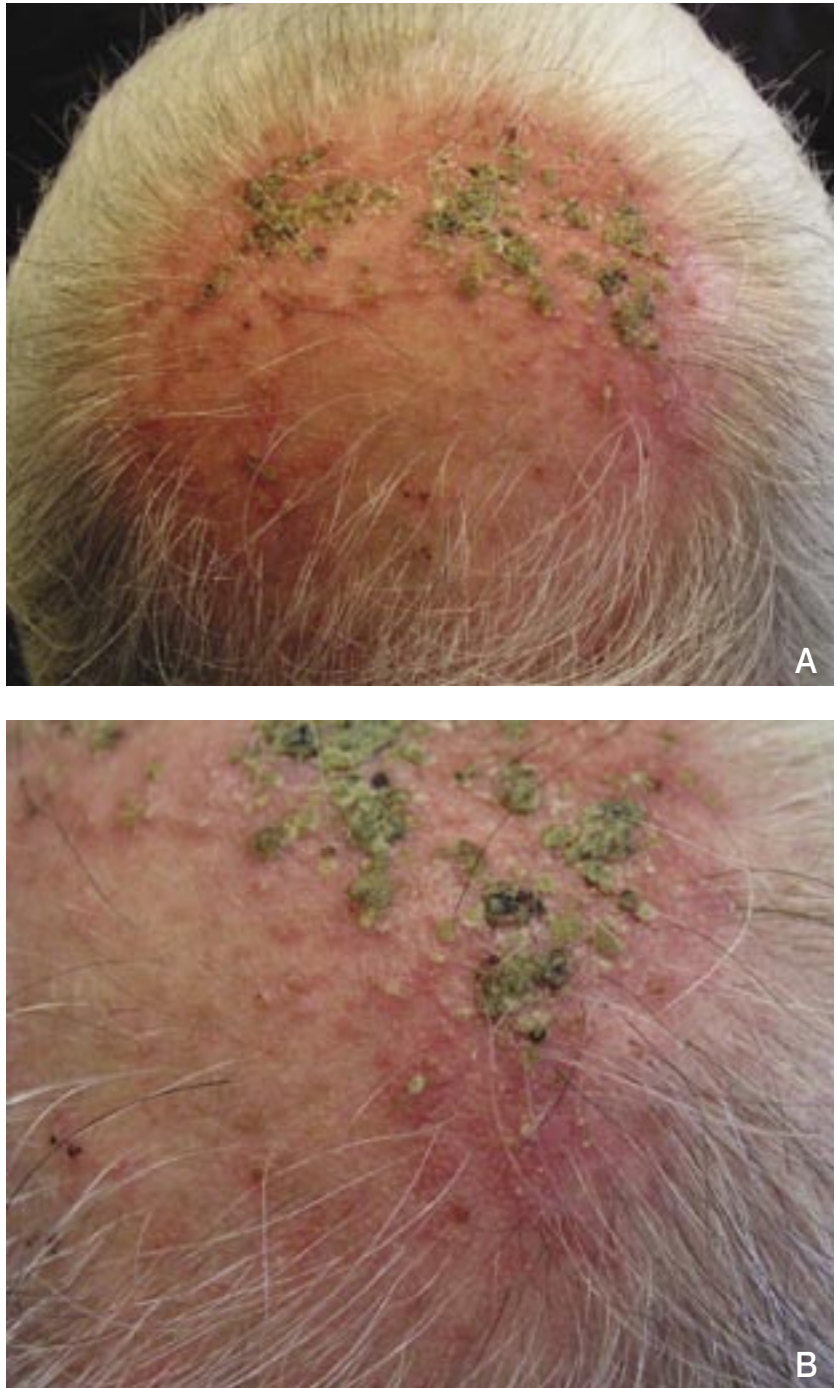


Figure 1. The patient's scalp shows an erythematous plaque with hyperkeratosis and pustules before treatment (A and B).

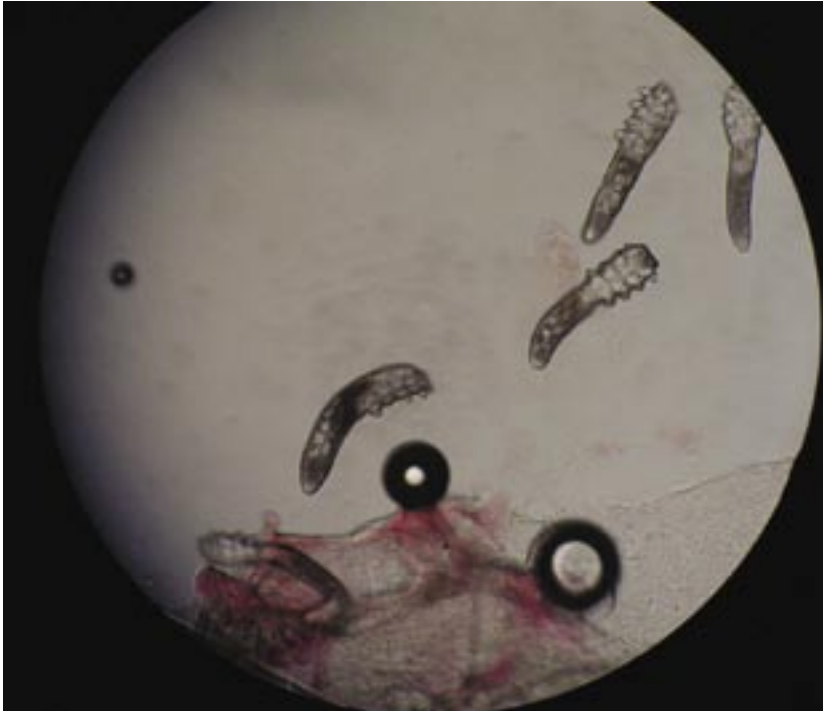

Figure 2. An ectoparasite wet mount shows the presence of several *Demodex folliculorum* organisms (original magnification $\times 40$).

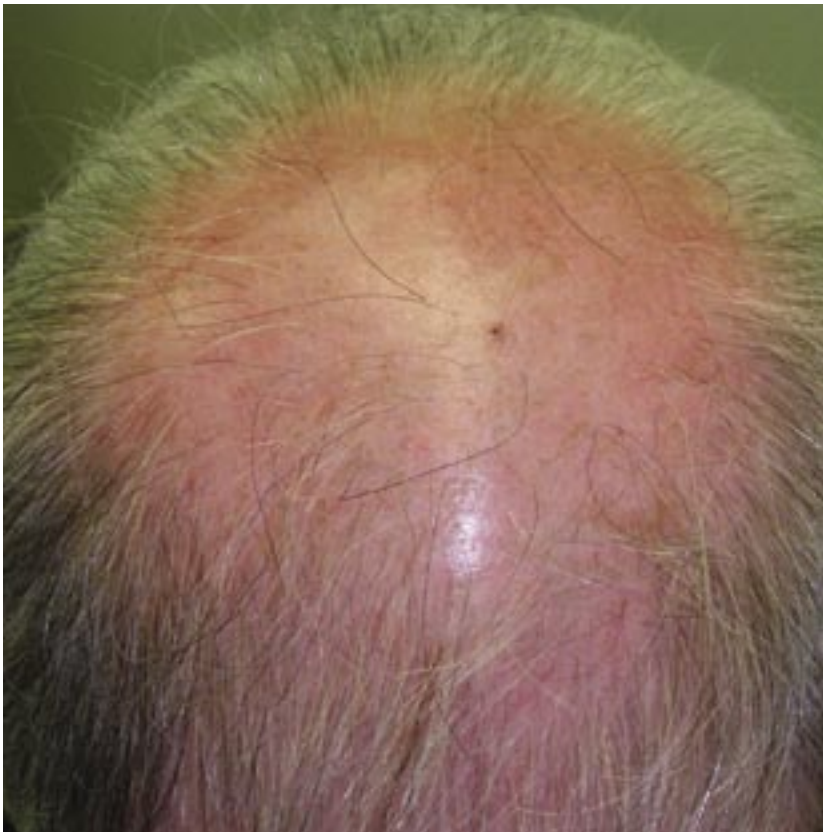

Figure 3. Clearing of patient's scalp following treatment with sulfacetamide 10% plus sulfur 5% cream twice daily and selenium sulfide 2.5% shampoo once daily for 2 weeks.

the detection of the presence of the mite is not, in and of itself, enough evidence to establish pathogenicity.⁶ Results of immunohistochemical staining have shown that helper T lymphocytes predominate in the dermal infiltrate of demodicosis suggesting a possible role of cell-mediated immune response and delayed hypersensitivity.⁷ There also is evidence for a humoral immune response component with increased macrophages and Langerhans cells in the presence of infestation with *Demodex*.⁷

Demodex mites have been implicated as a causative agent in rosacea and pustular folliculitis.⁶ It is important to consider the possibility that the vascular changes of rosacea create an environment that is favorable to the multiplication of *Demodex* mites and their penetration into the dermis.⁸ Forton and Seys⁶ reported that *Demodex* mites are associated with the inflammatory symptoms of rosacea and that the mites are present in greater numbers and higher frequencies in patients with rosacea. Additionally, a study by Georgala et al⁷ evaluated the importance of *D folliculorum* in the etiology and course of rosacea and showed that *D folliculorum* was found in 83 (90.2%) of 92 rosacea subjects studied but in only 11 (11.9%) of the 92 controls, thereby concluding that although *Demodex* mites may not be the cause of rosacea, they may represent an important cofactor. Finally, Vollmer⁹ examined 388 follicles in 24 resections of skin for the presence of histologic folliculitis and *Demodex* mites. Results showed that *Demodex* mites were found in 87 (42%) of 208 follicles with inflammation but in just 18 (10%) of 180 follicles without inflammation. Furthermore, 87 (83%) of 105 follicles with *Demodex* showed inflammation,

which demonstrated a nonrandom association between these 2 entities.⁹ A study by Meinking et al¹⁰ supported the rapid clearing of papulopustular dermatosis of the scalp and granulomatous rosacea when treated with scabicial preparations such as permethrin or ivermectin, thereby supporting the pathogenic role of *Demodex* in papulopustular eruptions.

On the other hand, a review by Aylesworth and Vance¹¹ found that 117 (10%) of 1124 skin biopsies and 198 (12%) of 1692 follicles incidentally revealed that follicular mites were found in patients with various unrelated skin disorders, thereby suggesting that *Demodex* is a normal inhabitant of the hair follicle and is not pathogenic.¹¹ Other histologic evidence that failed to show a correlation between *Demodex* presence and skin disease was an examination of the results of 108 biopsy specimens of rosacea, of which only 20 (19%) contained *Demodex*.¹² There was no correlation between *Demodex* mites and skin disease in a study of 29 biopsy samples of the head and neck by Nutting and Green.¹³ We must note that the reported prevalence of *Demodex* presence is partially determined by the preciseness of the detection method used.

There are several treatment options available for demodicosis. In our case, the patient cleared with a combination of sulfacetamide 10% plus sulfur 5% cream, in addition to selenium sulfide 2.5% shampoo. Other commonly used treatment options include ivermectin,¹⁰ topical antibiotics, and topical retinoids.

The persistence of the patient's folliculitis despite treatment with clindamycin 1% gel; rapid clearance after therapy with sulfacetamide 10% plus sulfur 5% cream twice daily and selenium sulfide 2.5% shampoo once daily is initiated; and positive results of the ectoparasite wet mount suggest a pathogenic role of *Demodex* in causing the patient's symptoms. Although the link between folliculitis and *Demodex* infection remains controversial, this case demonstrates the importance of

considering the possible role of *Demodex* in the differential diagnosis of rosacea and papulopustular eruptions of the head and neck.

REFERENCES

1. Norn MS. *Demodex folliculorum*. incidence, regional distribution, pathogenicity. *Dan Med Bull*. 1971;18:14-17.
2. Plewig G, Klingman AM. The role of *Demodex*. In: Plewig J, Klingman AM, eds. *Acne and Rosacea*. 2nd ed. Berlin, Germany: Springer-Verlag; 1993:482-486.
3. Ayres S Jr, Ayres S 3rd. Demodectic eruptions (demodicidosis) in the human. 30 years' experience with 2 commonly unrecognized entities: pityriasis folliculorum (*Demodex*) and acne rosacea (*Demodex* type). *Arch Dermatol*. 1961;83:816-827.
4. Woolley TA. *Acarology: Mites and Human Welfare*. New York, New York: Wiley Interscience; 1988.
5. Baker E. *An Introduction to Acarology*. New York, New York: MacMillan Company; 1952.
6. Forton F, Seys B. Density of *Demodex folliculorum* in rosacea: a case-control study using standardized skin-surface biopsy. *Br J Dermatol*. 1993;128:650-659.
7. Georgala S, Katoulis AC, Kylafis GD, et al. Increased density of *Demodex folliculorum* and evidence of delayed hypersensitivity reaction in subjects with papulopustular rosacea. *J Eur Acad Dermatol Venereol*. 2001;15:441-444.
8. Spickett SG. Aetiology of rosacea. *Br Med J*. 1962;1:1625-1626.
9. Vollmer RT. *Demodex*-associated folliculitis. *Am J Dermatopathol*. 1996;18:589-591.
10. Meinking TL, Taplin D, Hermida JL, et al. The treatment of scabies with ivermectin. *N Engl J Med*. 1995;333:26-30.
11. Aylesworth R, Vance JC. *Demodex folliculorum* and *Demodex brevis* in cutaneous biopsies. *J Am Acad Dermatol*. 1982;7:583-589.
12. Marks R, Harcourt-Weber JN. Histopathology of rosacea. *Arch Dermatol*. 1969;100:683-691.
13. Nutting WB, Green AC. Pathogenesis associated with hair follicle mites (*Demodex* spp) in Australian Aborigines. *Br J Dermatol*. 1976;94:307-312.

DISCLAIMER

The opinions expressed herein are those of the authors and do not necessarily represent the views of the sponsor or its publisher. Please review complete prescribing information of specific drugs or combination of drugs, including indications, contraindications, warnings, and adverse effects before administering pharmacologic therapy to patients.

CONFLICT OF INTEREST STATEMENT

The Conflict of Interest Disclosure Policy of Albert Einstein College of Medicine requires that authors participating in any CME activity disclose to the audience any relationship(s) with a pharmaceutical or equipment company. Any author whose disclosed relationships prove to create a conflict of interest, with regard to their contribution to the activity, will not be permitted to present.

The Albert Einstein College of Medicine also requires that faculty participating in any CME activity disclose to the audience when discussing any unlabeled or investigational use of any commercial product, or device, not yet approved for use in the United States.