

Extramammary Paget's Disease Resistant to Surgery and Imiquimod Monotherapy But Responsive to Imiquimod Combination Topical Chemotherapy With 5-Fluorouracil and Retinoic Acid: A Case Report

Jian Nan Ye, MD; David C. Rhew, MD; Felix Yip, MD; Leon Edelstein, MD

GOAL

To gain a better understanding of treatments for extramammary Paget's disease (EMPD) to better manage patients with the condition

OBJECTIVES

Upon completion of this activity, dermatologists and general practitioners should be able to:

1. Describe the treatment options for patients with EMPD.
2. Identify patterns of EMPD.
3. Recognize the clinical presentation of EMPD.

CME Test on page 228.

This article has been peer reviewed and approved by Michael Fisher, MD, Professor of Medicine, Albert Einstein College of Medicine. Review date: March 2006.

This activity has been planned and implemented in accordance with the Essential Areas and Policies of the Accreditation Council for Continuing Medical Education through the joint sponsorship of Albert Einstein College of Medicine and Quadrant HealthCom, Inc. Albert

Einstein College of Medicine is accredited by the ACCME to provide continuing medical education for physicians.

Albert Einstein College of Medicine designates this educational activity for a maximum of 1 AMA PRA Category 1 Credit™. Physicians should only claim credit commensurate with the extent of their participation in the activity.

This activity has been planned and produced in accordance with ACCME Essentials.

Drs. Ye, Rhew, Yip, and Edelstein report no conflict of interest. The authors discuss off-label use of 5-fluorouracil, imiquimod, and retinoic acid. Dr. Fisher reports no conflict of interest.

Accepted for publication June 1, 2005.

Dr. Ye is Director, Dermatology and Laser Service; Dr. Yip is Chief, Urology Service; and Dr. Edelstein is Professor of Dermatology and Pathology, all at the School of Medicine, University of California, Davis. Drs. Ye and Yip also are Attending Physicians, Garfield Medical Center, Monterey Park, California. Dr. Edelstein also is President, California Age Research Institute, Davis. Dr. Rhew is Vice President of Content Development, Zynx Health Incorporated, Los Angeles, California, and Clinical Associate Professor, University of California, Los Angeles.

Reprints: Jian Nan Ye, MD, 99 N La Cienega Blvd, Suite M-100, Beverly Hills, CA 90211 (e-mail: jimyedai@aol.com).

Extramammary Paget's disease (EMPD) is an uncommon skin neoplasm that usually affects the elderly population and occurs in the genital, anorectal, or axillary areas. The recommended treatment of EMPD involves surgical excision, including Mohs micrographic surgery; however, surgery is associated with a high rate of recurrence. There have been reports of successful treatment of recurrence with monochemotherapy involving topical imiquimod 5% cream. We report

a case of EMPD recurrence after surgery that was resistant to imiquimod monotherapy but that completely resolved after imiquimod was combined with topical 5-fluorouracil (5-FU) and retinoic acid. To our knowledge, this is the first reported case of imiquimod combination therapy with 5-FU and retinoic acid for the treatment of recurrent EMPD.

Cutis. 2006;77:245-250.

Extramammary Paget's disease (EMPD) is an uncommon clinical condition. However, cases of EMPD increasingly have been reported in recent years because of advancements in diagnostic technique and increased awareness of the disease. There are 3 patterns of EMPD: (1) cutaneous in situ epithelial with no associated underlying cancer; (2) epithelial with an associated underlying adnexal cancer; and (3) disease associated with underlying organ involvement (ie, genitourinary, gastrointestinal, or another distant site). Treatment of EMPD is problematic because the disease is associated with a high rate of recurrence. Preliminary results with topical imiquimod monotherapy demonstrate that this treatment may serve as a potential nonsurgical cure for the disease. We report a case of a patient who failed to respond to surgery or imiquimod monotherapy but who responded to imiquimod combination therapy with 5-fluorouracil (5-FU) and retinoic acid.

Case Report

A 68-year-old Chinese man presented with a pruritic rash in the scrotal area of 7 years' duration (Figure 1). Results of a skin biopsy revealed diffuse clusters of malignant pagetoid intraepidermal epithelial proliferation that stained positive with colloidal iron, mucicarmine, and periodic acid-Schiff with diastase (Figure 2). The results were diagnostic for EMPD. Results of detailed clinical and laboratory examinations showed no evidence of malignancy in other sites.

The patient underwent a large surgical excision with skin flap repair. One year later, he complained of an itchy rash within the surgical scar. Results of a repeat biopsy confirmed EMPD. The patient refused further surgery. As an alternative treatment, imiquimod 5% cream was applied nightly (Monday through Friday) for 6 weeks; because of moderate irritation, the application was decreased to every other day for the next 4 weeks. In general, the patient tolerated the treatment well and only reported erythema, burning, and some tenderness in the affected area. At the end of the 10-week treatment, histologic evaluation results revealed residual epidermal EMPD.

The patient was then treated with imiquimod, 5-FU, and retinoic acid combination chemotherapy. The protocol involved applying 5-FU 5% cream every morning, retinoic acid 0.1% gel every afternoon, and imiquimod every evening. After 12 days, the patient complained of severe burning and pain in the affected area, and results of an examination showed severe erosive erythema (Figure 3). At that

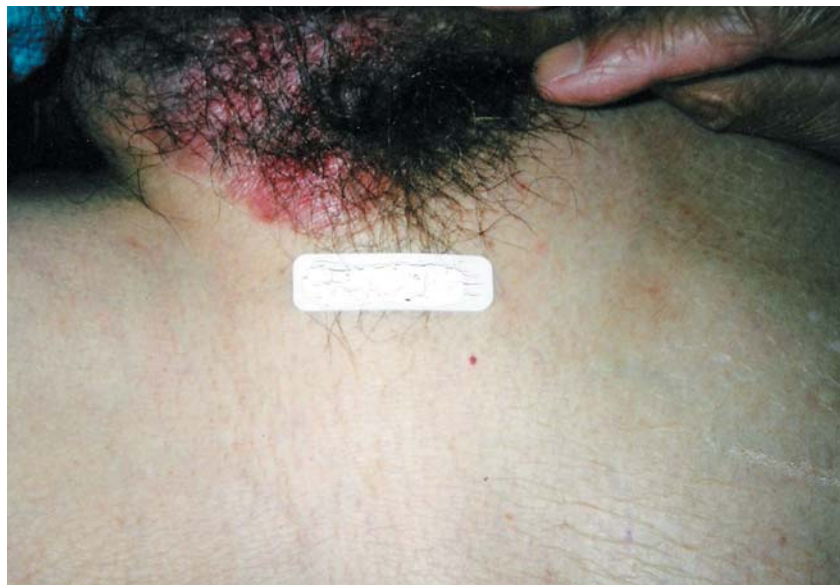

Figure 1. Extramammary Paget's disease involving the scrotum.

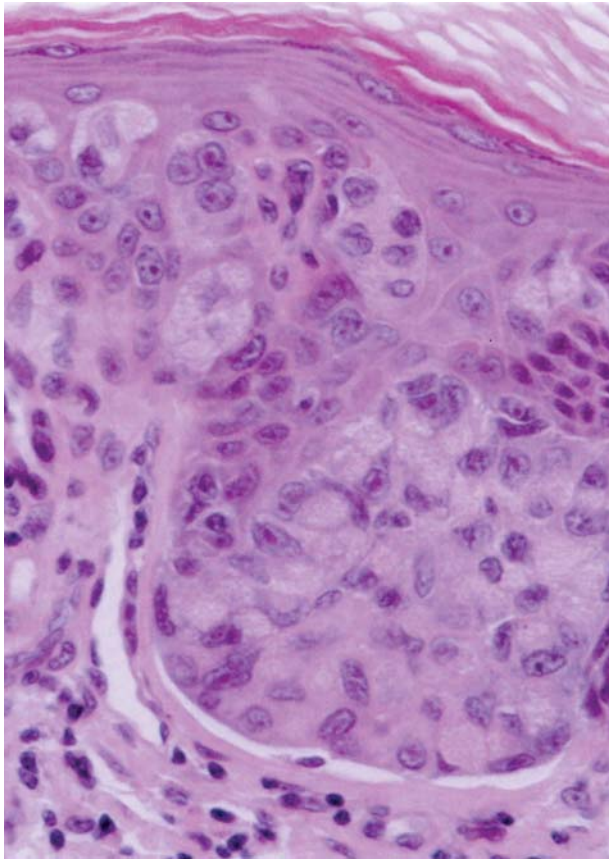


Figure 2. Histopathology of lesion with pleomorphic Paget's cells before treatment (H&E, original magnification $\times 400$).

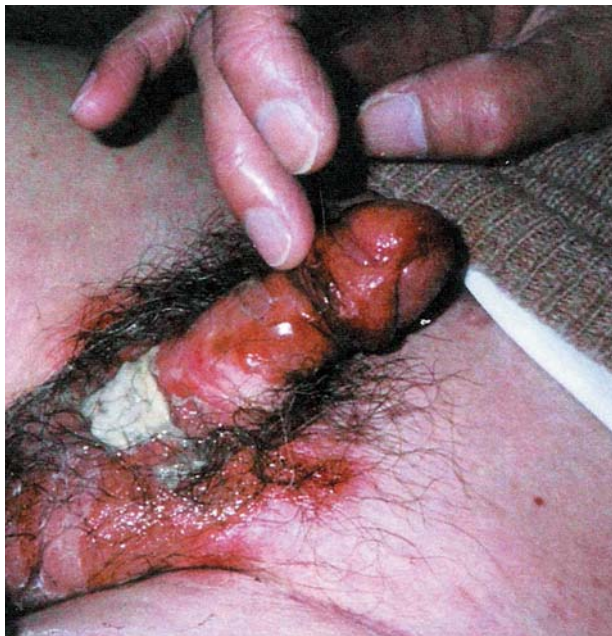

Figure 3. Erosive erythema after 12 days of combination topical chemotherapy.

point, topical chemotherapy was discontinued. Zinc oxide 2% and polysporin ointment were applied alternatively 4 times daily for 2 weeks.

In the third week after the topical chemotherapy, results of multiple punch biopsies on several sites revealed no residual malignancy. The patient remained asymptomatic, and the results of a repeat biopsy revealed no residual microscopic malignancy at the 2-year follow-up visit.

Comment

EMPD is a multifocal epidermal malignancy that possibly is related to the proliferation of pleuripotential epithelial stem cells. EMPD follows an unpredictable clinical course, ranging from indolent skin disease to aggressive malignancy. In general, EMPD appears in individuals aged 50 to 80 years, particularly in those who are white. Typical anatomic sites involve the vulvar, perianal, perineal, scrotal, and penile regions. Less common sites include the thighs, buttocks, axilla, eyelids, and external ear canal. The lesions of EMPD present as well-defined erythematous plaques that usually are accompanied by pruritus.

The main differential diagnoses of EMPD include psoriasis, contact dermatitis, fungal infection, lichen sclerosis, atopic dermatitis, Bowen's disease, melanoma, histiocytosis, pagetoid basal cell carcinoma, and mycosis fungoides. The nonspecific presentation of EMPD often leads to a misdiagnosis, and an average of one year may pass before a biopsy is performed and a definitive diagnosis is made. Microscopically, the margins of EMPD are multicentric and vague, with skip areas that frequently extend beyond the clinically detectable lesion, which results in the high rate of recurrence of EMPD. In addition, there is a lack of clinical experience with cutaneous EMPD because the disease has a relatively rare occurrence. Case reports constitute the majority of literature on EMPD. The successful management of EMPD is compromised by the multifocal nature of the disease; recurrence of lesions after conventional surgical management is high, ranging from 44% to 75%. Even with Mohs micrographic surgery, the lesions have a reported recurrence rate of 27%.¹⁻²

Imiquimod is an immunomodulator that stimulates the production of a wide range of cytokines, including interleukins 1, 6, 8, and 12; interferon; and tumor necrosis factor. Imiquimod activates B-cell responses by increasing the expression of class II major histocompatibility complex markers, which increase immunoglobulin production. Imiquimod also may enhance Langerhans cell migration from the skin to the lymph nodes, thus improving

Case Reports of Successful Treatment of Extramammary Paget's Disease With Topical Imiquimod 5% Cream*

Author (Year)	Patient Medical History	Imiquimod 5% Cream Treatment Regimen	Side Effects	Length of Time Disease Free (at Time of Reporting)
Zampogna et al (2002) ⁶	57-year-old white man; 4-y history of 3×5-cm plaque on scrotum; pretreated 6 mo previously with ED&C	Nightly for 6 nights, then 4 d of rest, then every other day for 16 wk	Flulike symptoms (fatigue, malaise, low-grade fever), erosive erythema	1 y
	72-year-old white man; 10-y history of an eruption in perineal and L inguinal area	Nightly for 3 wk, then decreased to every other day for 7.5 wk	Nausea, vomiting, erythema, burning, tenderness	4 mo
Qian et al (2003) ⁷	73-year-old white man; multiple Mohs surgeries and PDTs during previous 8 y	3 times weekly for 6 wk	Erythema	14 mo
Wang et al (2003) ⁸	75-year-old white woman; burning lesion 1 y after local excision of L upper vulva	Nightly for 6 nights, then 4 d of rest, then 2–3 times weekly for 5 wk	Local irritation, erosive erythema, tenderness	2 wk
Berman et al (2003) ⁹	68-year-old white man; 4 y post Mohs surgery; eczematous eruption on R scrotum	Daily for 6 wk	Erythema	6 mo

*ED&C indicates electrodesiccation and curettage; L, left; PDTs, photodynamic therapies; R, right.

antigen presentation.³ An *in vitro* study has demonstrated that imiquimod inhibits tumor-associated angiogenesis and diminishes tumor burden in transplantable murine carcinoma.⁴ Results of a biopsy specimen from one melanoma patient also showed apoptosis after treatment with topical imiquimod cream and systemic dacarbazine.⁵

We identified 5 cases (in 4 reports) in which the effect of topical imiquimod monotherapy applied

to the perianal/genital area of patients with EMPD was evaluated.⁶⁻⁹ All 5 cases showed a clinical and histologic cure, with minimal functional disturbance. In the study with the longest follow-up period, the patient remained disease free at the 14-month follow-up visit.⁷ In the study with the most frequent dosing interval, the medication was applied once daily.⁹ Treatment duration ranged from 6 to 16 weeks (Table).⁶⁻⁹

5-FU has selective toxicity in premalignant and malignant epithelial lesions. 5-FU is a chemotherapeutic drug that induces notable regression in advanced locally progressing EMPD.^{10,11} The mechanisms of action of 5-FU are based on the drug's steric similarity to uracil and its irreversible binding to thymidylate synthetase, which prevents the synthesis of thymidine from uridine. Consequently, RNA and DNA synthesis are inhibited, faulty RNA is produced, and cell toxicity ensues. Paget's cells have a high metabolic activity that requires abundant RNA. This high demand for RNA synthesis may be responsible for the sensitivity of Paget's cells to 5-FU.

Six cases (in 6 reports) published in the English literature evaluated the effect of 5-FU monotherapy in the treatment of EMPD.¹¹⁻¹⁶ Four reports showed clinical cure after treatment with 5-FU.^{12-14,16} In 2 of the reports, microscopic evidence of disease persisted after treatment¹²⁻¹³; in one report, no follow-up biopsy was performed¹⁴; in another report, no microscopic evidence of disease after treatment was identified.¹⁶ In the case report by Del Castillo et al,¹⁶ the patient applied topical 5-FU 5% intermittently (at the patient's discretion) to the affected axilla region for one year. The surgical removal of the lesion after one year of intermittent treatment showed no evidence of EMPD. In the case reports by Bewley et al¹¹ and Eliezri et al,¹⁵ application of 5-FU 5% increased the disease margins. In summary, these reports demonstrate that topical 5-FU cannot be considered a safe and effective first-line choice of treatment due to its erosive feature and false impression of total clinical resolution.

Retinoic acid has antiproliferative activity and induces apoptosis by its selective binding activity to the γ receptor in the nuclear receptor-independent pathway in neoplastic cells.¹⁷⁻¹⁸ We identified no published reports of topical retinoic acid for the treatment of EMPD. The most common use of retinoid antitumor agents is in the treatment of leukemia.

In our case report, the tumor recurred after initial surgery and remained after 10 weeks of monotherapy with imiquimod. The reason imiquimod therapy failed in this case may relate to the presence of the tumor in the area of scar tissue; imiquimod by itself could not achieve adequate tissue penetration to induce the appropriate immune response. Consequently, we applied 5-FU cream in the morning to induce a selective toxicity in the Paget's cell, and retinoic acid gel in the afternoon to promote an antiproliferative apoptosis and to facilitate the penetration of imiquimod, which was applied in the evening. This combination therapy could potentiate a stronger stimulation of cytokines and interferon, which would then lead to the activation of T and

B cells, natural killer cells, and a macrophage host response, all of which could be responsible for the destruction of the intraepithelial EMPD. In conclusion, we have demonstrated that a combination treatment of topical imiquimod, 5-FU, and retinoic acid may serve as an effective treatment option for patients who have failed imiquimod monotherapy.

Acknowledgments—The authors would like to thank their colleagues John O'Dea, MD; Tony Chin, MD; Robert Uyeda, MD; and Simon Chan, MD, for reviewing and critiquing this manuscript. The authors also would like to thank Irma Marques for editing the manuscript.

REFERENCES

1. Zollo JD, Zeitouni NC. The Roswell Park Cancer Institute experience with extramammary Paget's disease. *Br J Dermatol.* 2000;142:59-65.
2. Coldiron BM, Goldsmith BA, Robinson JK. Surgical treatment of extramammary Paget's disease. a report of six cases and a reexamination of Mohs micrographic surgery compared with conventional surgical excision. *Cancer.* 1991;67:933-938.
3. Sauder DN. Immunomodulatory and pharmacologic properties of imiquimod. *J Am Acad Dermatol.* 2000;43(1 pt 2): S6-S11.
4. Sidky YA, Borden EC, Weeks CE, et al. Inhibition of murine tumor growth by an interferon-inducing imidazoquinolineamine. *Cancer Res.* 1992;52:3528-3533.
5. Steinmann A, Funk Jo, Schuler G, et al. Topical imiquimod treatment of a cutaneous melanoma metastasis. *J Am Acad Dermatol.* 2000;43:555-556.
6. Zampogna JC, Flowers FP, Roth WI, et al. Treatment of primary limited cutaneous extramammary Paget's disease with topical imiquimod monotherapy: two case reports. *J Am Acad Dermatol.* 2002;47(suppl 4):S225-S235.
7. Qian Z, Zeitoun NC, Shieh S, et al. Successful treatment of extramammary Paget's disease with imiquimod. *J Drugs Dermatol.* 2003;2:73-76.
8. Wang LC, Blanchard A, Judge DE, et al. Successful treatment of recurrent extramammary Paget's disease of the vulva with topical imiquimod 5% cream. *J Am Acad Dermatol.* 2003;49:769-772.
9. Berman B, Spencer J, Villa A, et al. Successful treatment of extramammary Paget's disease of the scrotum with imiquimod 5% cream. *Clin Exp Dermatol.* 2003;28 (suppl 1):36-38.
10. Voigt H, Bassermann R, Nathrath W. Cytoreductive combination chemotherapy for regionally advanced unresectable extramammary Paget's carcinoma. *Cancer.* 1992;70:704-708.

Extramammary Paget's Disease

11. Bewley AP, Bracka A, Staughton RC, et al. Extramammary Paget's disease of the scrotum: treatment with topical 5-fluorouracil and plastic surgery. *Br J Dermatol*. 1994;131:445-446.
12. Kawatsu T, Miki Y. Triple extramammary Paget's disease. *Arch Dermatol*. 1971;104:316-319.
13. Fetherston WC, Friedrich EG. The origin and significance of vulvar Paget's disease. *Obstet Gynecol*. 1972;39:734-744.
14. Haberman HF, Goodall J, Llewellyn M. Extramammary Paget's disease. *Can Med Assoc J*. 1975;118:161-162.
15. Eliezri YD, Silvers DN, Horan DB. Role of preoperative topical 5-fluorouracil in preparation for Mohs micrographic surgery of extramammary Paget's disease. *J Am Acad Dermatol*. 1987;17:497-505.
16. Del Castillo LF, Garcia C, Schoendorff C, et al. Spontaneous apparent clinical resolution with histologic persistence of a case of extramammary Paget's disease: response to topical 5-fluorouracil. *Cutis*. 2000;65:331-333.
17. Hsu CA, Rishi AK, Su-Li X. Retinoid induced apoptosis in leukemia cells through a retinoic acid nuclear receptor-independent pathway. *Blood*. 1997;89:4470-4479.
18. Meister B, Fink FM, Hittmair A, et al. Antiproliferative activity and apoptosis induced by retinoic acid receptor-gamma selectively binding retinoids in neuroblastoma. *Anticancer Res*. 1998;18:1777-1786.

DISCLAIMER

The opinions expressed herein are those of the authors and do not necessarily represent the views of the sponsor or its publisher. Please review complete prescribing information of specific drugs or combination of drugs, including indications, contraindications, warnings, and adverse effects before administering pharmacologic therapy to patients.

CONFLICT OF INTEREST STATEMENT

The Conflict of Interest Disclosure Policy of Albert Einstein College of Medicine requires that authors participating in any CME activity disclose to the audience any relationship(s) with a pharmaceutical or equipment company. Any author whose disclosed relationships prove to create a conflict of interest, with regard to their contribution to the activity, will not be permitted to present.

The Albert Einstein College of Medicine also requires that faculty participating in any CME activity disclose to the audience when discussing any unlabeled or investigational use of any commercial product, or device, not yet approved for use in the United States.