

# Tretinoin Microsphere Gel 0.1% for Photodamaged Facial Skin: A Placebo-Controlled Trial

Jonathan S. Weiss, MD; Joel S. Shavin, MD; Marge Nighland, MS; Rachel Grossman, MD

*Tretinoin microsphere gel (TMG) 0.1% was evaluated as a treatment of photodamaged skin. The study included a 6-month, randomized, double-blinded, placebo-controlled phase and an additional 6-month open-label phase during which all subjects received TMG 0.1%. Forty-five subjects with moderate to severe photodamaged facial skin applied study gel topically to the face once nightly (22 subjects received TMG 0.1% and 23 subjects received placebo). At 6 months, TMG 0.1% was found to be superior to placebo in improving overall severity of photodamage ( $P=.0003$ ) and in the investigator's global assessment of clinical response ( $P<.0001$ ). Statistically significant improvement relative to placebo was observed in fine wrinkling ( $P<.0001$ ), mottled hyperpigmentation ( $P=.0002$ ), yellowing/sallowiness ( $P<.0001$ ), and lentiginosities ( $P=.0054$ ). The improvements observed after 6 months of open-label therapy were consistent with the results observed in TMG 0.1%-treated subjects during double-blinded treatment. Most signs and symptoms of cutaneous irritation were mild throughout the treatment period. At one month,*

*a higher proportion of subjects in the TMG 0.1% group relative to the placebo group experienced an increase in severity of cutaneous irritation. After 6 months, the difference between treatment groups was statistically significant only for peeling ( $P=.001$ ) and dryness ( $P=.007$ ).*

*Cutis. 2006;78:426-432.*

Several topical tretinoin products have been shown to improve photodamaged skin.<sup>1-7</sup> In 1997, a new formulation, tretinoin microsphere gel (TMG) 0.1%, was introduced in the United States for the treatment of acne vulgaris. This formulation uses microsponge technology to encapsulate tretinoin in an aqueous gel without oils or organic solvents that can contribute to irritation. Given the sensitivity of photodamaged facial skin, it would be beneficial to identify agents that are equally efficacious and less irritating than currently approved formulations of tretinoin.

## Methods

**Study Design and Treatment**—This was a single-center, 6-month, randomized, double-blinded, placebo-controlled study, with an additional 6 months of open-label TMG 0.1% treatment during which the placebo group crossed over to active treatment. The study protocol was approved by the local institutional review board, and written informed consent was obtained from all subjects prior to enrollment.

Subjects who satisfied all entry criteria were randomized to TMG 0.1% or placebo (vehicle gel). Subjects were instructed to apply a pea-size amount (approximately 0.25 g) of gel to the entire face once nightly after washing with a skin cleanser. A moisturizer with sunscreen (sun protection factor 15) was to be applied daily. An additional sunscreen (sun protection factor 30) was to be applied prior to extended

Accepted for publication March 17, 2006.

Drs. Weiss and Shavin are from Gwinnett Clinical Research Center, Inc, Snellville, Georgia. Dr. Weiss also is from Emory University School of Medicine, Atlanta, Georgia. Ms. Nighland and Dr. Grossman are from Johnson & Johnson Consumer and Personal Products Worldwide, Skillman, New Jersey.

This study was supported by OrthoNeutrogena. Drs. Weiss and Shavin report no conflict of interest. Ms. Nighland is an employee of and receives stock as a bonus program from Johnson & Johnson Consumer and Personal Products Worldwide. Dr. Grossman is an employee and stockholder of Johnson & Johnson Consumer and Personal Products Worldwide.

Reprints: Jonathan S. Weiss, MD, Gwinnett Clinical Research Center, Inc, 2383 Pate St, Snellville, GA 30078-3233 (e-mail: jsweissgd@bellsouth.net).

Table 1.

**Improvement From Baseline in Overall Severity of Photodamage**

	Change From Baseline*	Tretinoin Microsphere Gel 0.1%, n (%) (n=18) <sup>†</sup>	Placebo, n (%) (n=22) <sup>†</sup>	P Value <sup>‡</sup>
Month 6	-2	2 (11.1)	1 (4.5)	.0003
	-1	13 (72.2)	4 (18.2)	
	0	3 (16.7)	17 (77.3)	
P value <sup>§</sup>		<.0001	.0625	
Month 12	-3	1 (5.6)	0 (0)	.0337
	-2	2 (11.1)	1 (4.5)	
	-1	15 (83.3)	17 (77.3)	
	0	0 (0)	4 (18.2)	
P value <sup>§</sup>		<.0001	<.0001	

\*Units on a severity scale of 0 to 9 (0=none, 1-3=mild, 4-6=moderate, 7-9=severe); negative change from baseline represents improvement.

<sup>†</sup>Four subjects in the tretinoin microsphere gel 0.1% group and one subject in the placebo group withdrew from the study before the 6-month assessment.

<sup>‡</sup>Between-treatment effect (Wilcoxon rank sum test).

<sup>§</sup>Within-treatment effect (Wilcoxon signed rank test).

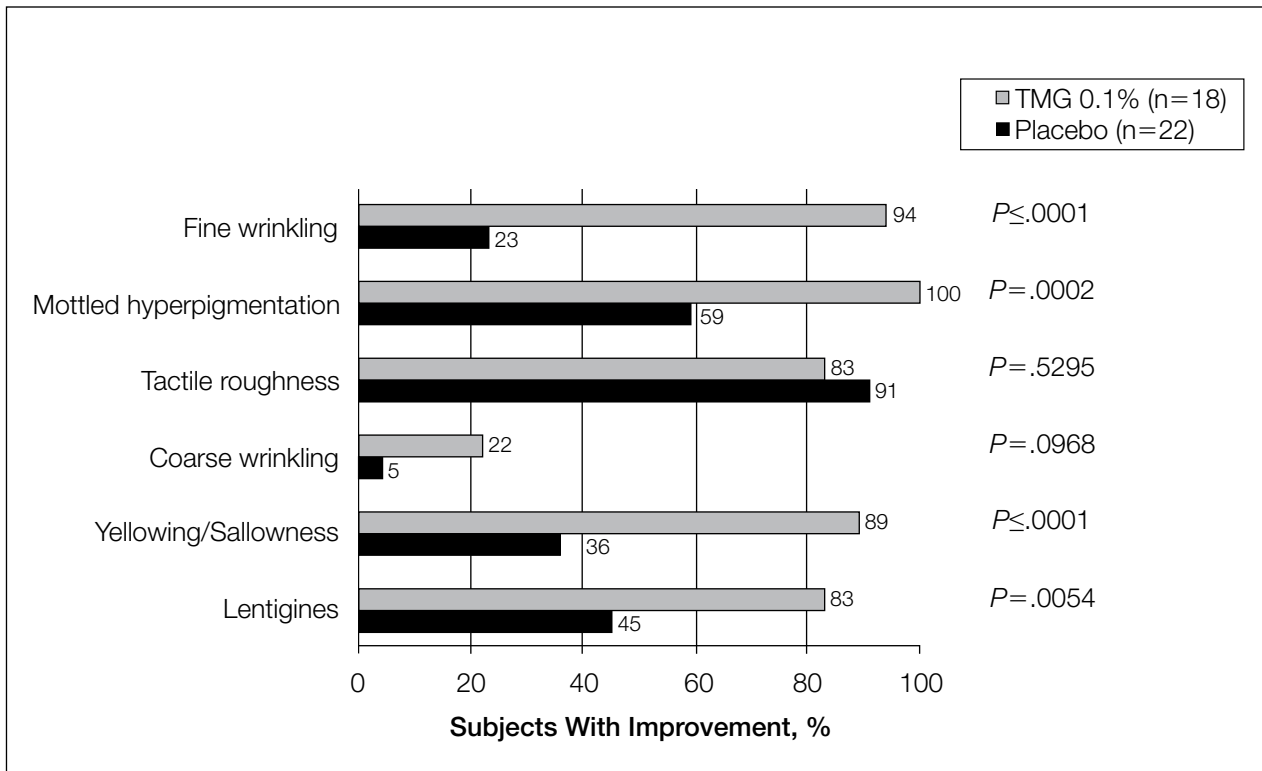
periods of exposure to UV light. If excess irritation occurred, less frequent applications could be made or the medication could be discontinued temporarily. Short-term therapy (ie,  $\leq 5$  days) with a topical corticosteroid was permitted in the event of excessive skin irritation. No topical medication except study gel was to be applied to the face during the study. The use of cosmetics was to be minimized. Neither the study gel nor any other emollients were to be applied to the face for 24 hours prior to study visits. Cosmetics were not to be applied on the day of study visits.

**Criteria for Evaluation**—Efficacy and safety evaluations were performed during clinic visits at baseline and months 1, 2, 4, 6, 9, and 12. The following assessments were performed at each visit: overall severity of photodamage, severity of individual signs of photodamage (fine wrinkling, mottled hyperpigmentation, tactile roughness, coarse wrinkling, yellowing/sallowness, and lentigenes), severity of cutaneous irritation (erythema, peeling, dryness, itching, and burning/stinging), and the subject's self-assessments (skin texture, skin color, small wrinkles, skin tightness, and overall

appearance and feel of skin). The investigator's global assessment of clinical response was determined at 6 and 12 months. Adverse events were recorded at all study visits. Severity ratings for clinical assessments of photodamage and cutaneous irritation were graded on a 10-point scale, categorized into 4 levels: 0=none, 1 to 3=mild, 4 to 6=moderate, 7 to 9=severe.

**Study Subjects**—Eligible subjects included men and nonpregnant nonnursing women in good health, aged 30 to 75 years. Subjects had to have moderate to severe photodamaged facial skin, defined as an overall severity grade of at least 4 at baseline, with a clinical grade for fine wrinkles of at least 4 at baseline. Before starting treatment, subjects were required to discontinue systemic retinoids and skin bleaching agents for at least 3 months and discontinue all topical retinoids and products containing  $\alpha$ -hydroxy acids for 30 days.

Key exclusion criteria included a diagnosis within the previous year of basal cell or squamous cell carcinoma on the face or a history of malignant melanoma at any site; therapy within the previous year for



**Figure 1.** Percentage of subjects with improvement from baseline to month 6 in clinical signs of photodamage as assessed by the investigator. TMG indicates tretinoin microspheres gel.

photodamaged or aging facial skin; any skin condition that could require concurrent therapy or confound the evaluation; a history of psychiatric or psychological disorders not controlled by medication; hypersensitivity to any of the formulation components of TMG 0.1%; excessive facial hair; need for electrolysis, waxing, or depilatories on the face during the study; and use of any known photosensitizing agents.

**Statistical Methods**—The primary efficacy endpoint was the change from baseline to month 6 in the overall severity rating of photodamage. The Wilcoxon rank sum test was used to compare treatment groups (TMG 0.1% vs placebo) for change from baseline in overall photodamage severity, severity of individual clinical signs, severity of cutaneous irritation, and subject self-assessments. The Wilcoxon rank sum test also was used to compare the global evaluation of clinical response across treatment groups. Within-group change from baseline in overall photodamage severity, clinical signs, cutaneous irritation, and subject self-assessments were tested using the Wilcoxon signed rank test. For subjects randomized to TMG 0.1%, the change from month 6 to month 12 in overall severity of photodamage was tested using the Wilcoxon signed rank test, in which month 6 served as baseline. All tests were 2-tailed with statistical significance at  $P \leq .05$ .

## Results

**Subject Characteristics**—Forty-five subjects were enrolled in the study: 22 received TMG 0.1%, and 23 received placebo. Eighteen TMG 0.1% subjects (82%) and 22 placebo subjects (96%) completed the study (ie, 12 months of treatment). One subject in the TMG 0.1% group withdrew after 5 weeks because of cutaneous irritation. Other reasons for withdrawal included lost to follow-up (3 TMG 0.1% subjects) and personal reasons (1 placebo subject). Subjects ranged in age from 38 to 73 years. All subjects were white, and all subjects were women except for one subject. The treatment groups were balanced at baseline with respect to demographics, skin type (Fitzpatrick score), and severity of photodamage. Baseline cutaneous irritation was more prevalent in the placebo group than the TMG 0.1% group. The difference between groups was statistically significant for dryness: 3 TMG 0.1% subjects (13.6%) and 10 placebo subjects (43.5%) ( $P = .0290$ ). All reports of baseline cutaneous irritation were in the mild category (scores of 1–3), with the exception of one subject in the placebo group with moderate erythema (score of 4).

**Response to Treatment**—In the TMG 0.1% group, the improvement from baseline in overall severity of photodamage was statistically significant at month 6 ( $P < .0001$ ) (Table 1). TMG 0.1% also was statistically

significantly better than placebo in improving overall photodamage severity ( $P=.0003$ ). Subjects in the TMG 0.1% group who continued to receive TMG 0.1% in the open-label phase also exhibited statistically significant improvements in overall severity of photodamage at month 12 ( $P<.0001$ ), as did subjects in the placebo group who crossed over to TMG 0.1% ( $P<.0001$ ).

All clinical signs of photodamage, except tactile roughness, showed greater improvement in the TMG 0.1% group relative to the placebo group at month 6 (Figure 1). The difference between treatment groups was statistically significant for fine wrinkling ( $P<.0001$ ), mottled hyperpigmentation ( $P=.0002$ ), yellowing/sallowness ( $P<.0001$ ), and lentigines ( $P=.0054$ ). The improvements in clinical signs observed at month 12 were consistent with the month 6 results in the TMG 0.1% treatment group.

The difference between treatment groups in the investigator's global assessment of clinical response was statistically significant in favor of TMG 0.1% at 6 and 12 months ( $P<.0001$  and  $P=.0103$ , respectively)(Table 2). Figure 2 summarizes

the results of each of the overall clinical response variables. The subject's self-assessments generally showed favorable responses in the TMG 0.1% group relative to the placebo group; however, the difference between treatment groups was statistically significant only for overall appearance and feel of skin. Figures 3 and 4 depict representative clinical responses of subjects after 6 and 12 months of treatment with TMG 0.1%.

**Safety**—Most signs and symptoms of cutaneous irritation were rated mild in intensity (score of 1–3) throughout the treatment period. Severity scores generally increased after the start of treatment and peaked at month 1. The proportion of subjects who experienced an increase in severity of cutaneous irritation at month 1 was statistically significantly higher in the TMG 0.1% group than the placebo group for all 5 variables (erythema,  $P=.0005$ ; peeling,  $P<.0001$ ; dryness,  $P<.0001$ ; itching,  $P=.0005$ ; burning/stinging,  $P<.0001$ ). At 6 months, severity ratings were either unchanged from baseline or increased by  $\leq 3$  grade points (mild) for all subjects. The difference between the TMG 0.1% and placebo groups at month 6 was statistically significant only for peeling ( $P=.001$ ) and dryness ( $P=.007$ ).

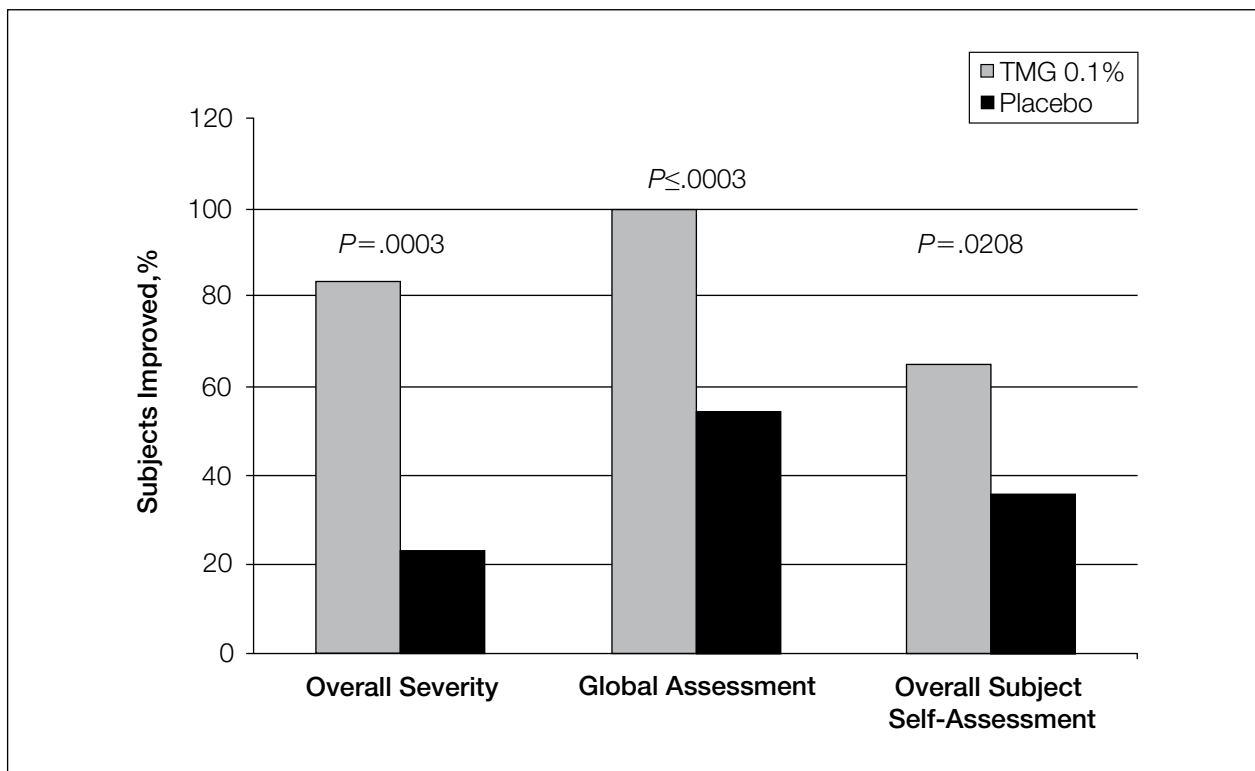
Table 2.

## Investigator's Global Assessment of Clinical Response

	Rating	Tretinoin Microsphere Gel 0.1%, n (%) (n=18)*	Placebo, n (%) (n=22)*	P Value <sup>†</sup>
Month 6	Much improved	2 (11.1)	0 (0)	<.0001
	Improved	14 (77.8)	3 (13.6)	
	Slightly improved	2 (11.1)	9 (40.9)	
	No change	0 (0)	10 (45.5)	
	Worse	0 (0)	0 (0)	
Month 12	Much improved	7 (38.9)	1 (4.5)	.0103
	Improved	9 (50.0)	15 (68.2)	
	Slightly improved	2 (11.1)	3 (13.6)	
	No change	0 (0)	3 (13.6)	
	Worse	0 (0)	0 (0)	

\*Four subjects in the tretinoin microsphere gel 0.1% group and one subject in the placebo group withdrew from the study before the 6-month assessment.

<sup>†</sup>Between-treatment effect (Wilcoxon rank sum test).



**Figure 2.** Percentage of subjects with improvement from baseline to month 6 in investigator's assessment of overall severity, investigator's global assessment of clinical response, and subject's self-assessment of overall appearance and feel of skin. TMG indicates tretinoin microsphere gel.

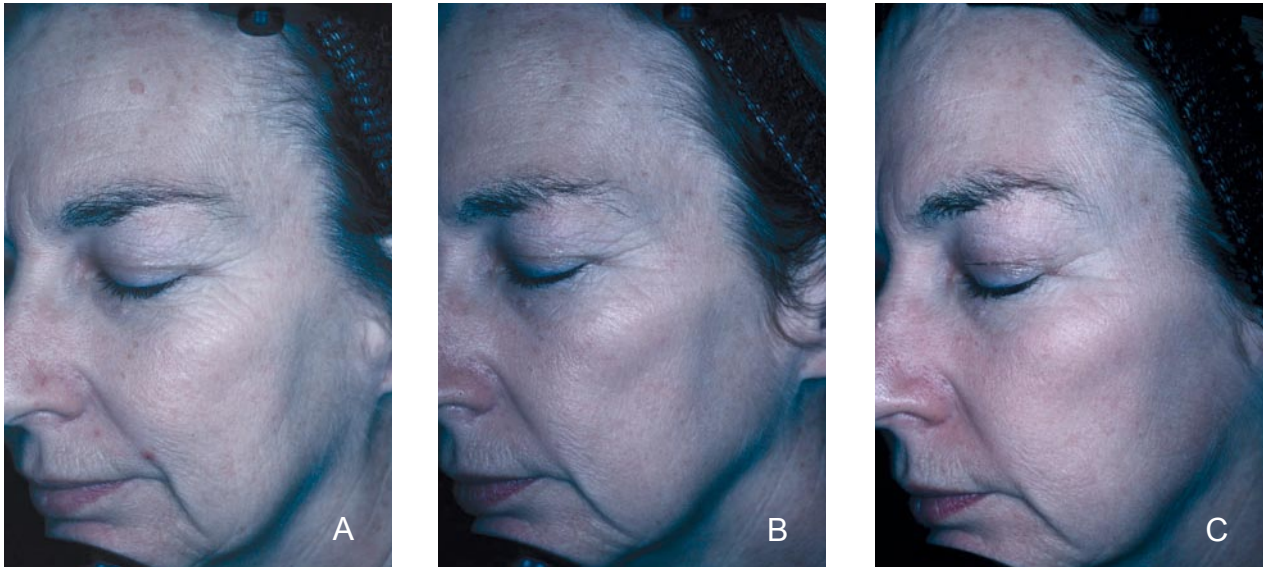
The overall incidence of adverse events was similar in the TMG 0.1% (32%) and placebo (30%) groups during double-blinded treatment. The most common adverse events in both groups were infections, occurring in 4 TMG 0.1% subjects (18.2%) and 5 placebo subjects (21.7%). The incidence and type of adverse events during open-label treatment were consistent with those in TMG 0.1%-treated subjects in the double-blinded phase.

### Comment

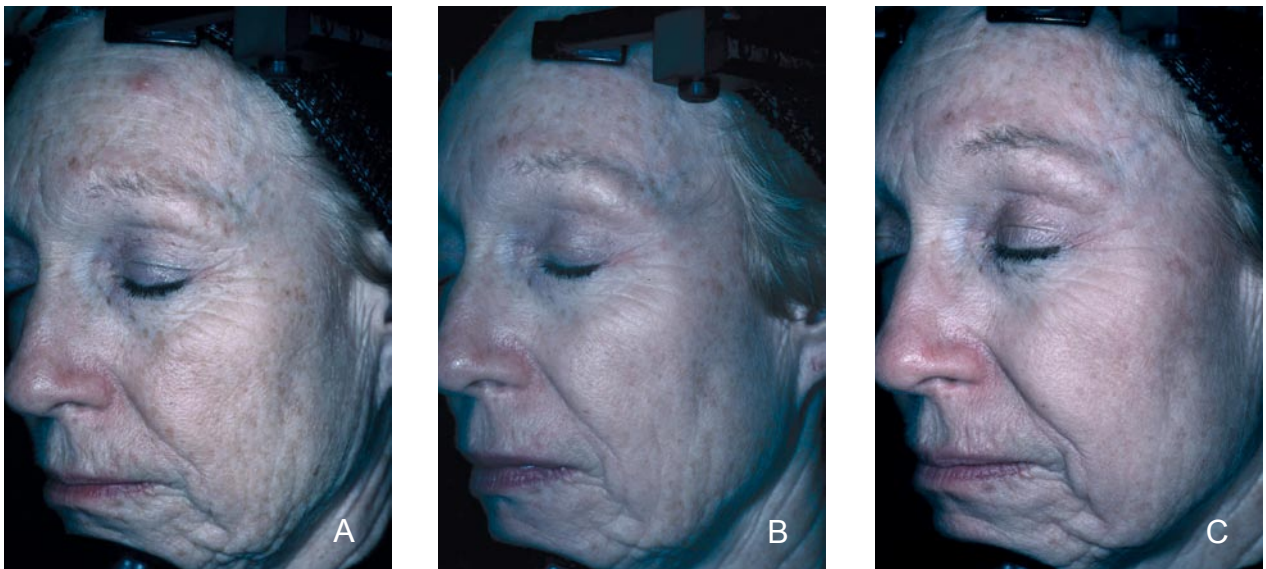
In this study, TMG was effective and safe in the treatment of photodamaged skin. TMG 0.1% produced statistically significant improvements relative to placebo in overall photodamage severity ( $P = .0003$ ), individual clinical signs of photodamage (fine wrinkling [ $P < .0001$ ], mottled hyperpigmentation [ $P = .0002$ ], yellowing/sallowness [ $P < .0001$ ], and lentigines [ $P = .0054$ ]), and the investigator's global assessment ( $P < .0001$ ). The results observed with TMG 0.1% are consistent with those of other topical tretinoin products.<sup>1-7</sup> Previous studies have reported response rates of 51% to 79% for improvement in overall severity of facial photodamage following treatment with tretinoin emollient cream 0.05% or 0.02% for 6 months.<sup>4,5,7</sup> Tretinoin

cream concentrations lower than 0.02% are not consistently effective.<sup>4,5</sup> In our study, all subjects in the TMG 0.1% group showed at least some improvement in the investigator's global assessment at 6 and 12 months, though 3 subjects who crossed over from placebo to TMG 0.1% experienced no change after 6 months of treatment. These results compare with previous studies where 77% to 95% of subjects treated with tretinoin cream (0.05%–0.1%) for 12 to 48 weeks showed at least some improvement in a global assessment.<sup>1,2,3,6</sup> The subject's self-assessment of improvement was generally less favorable than the investigator's global assessment in our study. In the authors' experience, this is a common finding. Although the investigator is able to detect change at intermittent assessment visits, the subject is less able to notice improvement over time under continuous observation.

TMG was well-tolerated. Most cutaneous irritation was mild throughout the treatment period. Only one subject withdrew because of cutaneous irritation. Evidence suggests that the irritant effects of tretinoin may be concentration dependent.<sup>1,2,6</sup> A lower concentration of TMG (0.04%) is available and will allow increased flexibility in dosing patients with photodamaged skin.



**Figure 3.** Subject at baseline (A); after 6 months of treatment with tretinoin microsphere gel 0.1%, graded as slightly improved (B); and after 12 months of treatment with tretinoin microsphere gel 0.1%, graded as improved (C).



**Figure 4.** Subject at baseline (A); after 6 months of treatment with tretinoin microsphere gel 0.1%, graded as improved (B); and after 12 months of treatment with tretinoin microsphere gel 0.1%, graded as much improved (C).

### Conclusion

TMG 0.1% was shown to be more effective than placebo in improving photodamaged skin. Cutaneous irritation was mild in most subjects. A higher proportion of TMG 0.1% subjects relative to placebo subjects experienced an increase in cutaneous irritation, but the differences between treatment groups occurred primarily in the first month of treatment. Dryness and peeling can easily be countered by applying moisturizers, which were prohibited at the time of evaluation in

this study. Topical retinoids (tretinoin, adapalene, tazarotene) are the only drugs that have been shown in controlled trials to be safe and effective for the treatment of photodamage.<sup>8,9</sup> There is little evidence that other products such as vitamin C,  $\alpha$ - or  $\beta$ -hydroxy acids, or plant-derived nucleotides have comparable efficacy.

*Acknowledgments*—The manuscript was prepared with the writing assistance of Karen M. Miner, PhD. Mark Van Buskirk, MS, assisted with the statistical analysis.

## REFERENCES

1. Weiss JS, Ellis CN, Headington JT, et al. Topical tretinoin improves photoaged skin. a double-blind vehicle-controlled study. *JAMA*. 1988;259:527-532.
2. Leyden JJ, Grove GL, Grove MJ, et al. Treatment of photodamaged facial skin with topical tretinoin. *J Am Acad Dermatol*. 1989;21:638-644.
3. Lever L, Kumar P, Marks R. Topical retinoic acid for treatment of solar damage. *Br J Dermatol*. 1990;122:91-98.
4. Weinstein GD, Nigra TP, Pochi PE, et al. Topical tretinoin for treatment of photodamaged skin. a multi-center study. *Arch Dermatol*. 1991;127:659-665.
5. Olsen EA, Katz HI, Levine N, et al. Tretinoin emollient cream: a new therapy for photodamaged skin. *J Am Acad Dermatol*. 1992;26:215-224.
6. Griffiths CE, Kang S, Ellis CN, et al. Two concentrations of topical tretinoin (retinoic acid) cause similar improvement of photoaging but different degrees of irritation. a double-blind, vehicle-controlled comparison of 0.1% and 0.025% tretinoin creams. *Arch Dermatol*. 1995;131:1037-1044.
7. Nyirady J, Bergfeld W, Ellis C, et al. Tretinoin cream 0.02% for the treatment of photodamaged facial skin: a review of 2 double-blind clinical studies. *Cutis*. 2001;68:135-142.
8. Guenther LC. Topical tazarotene therapy for psoriasis, acne vulgaris, and photoaging. *Skin Therapy Lett*. March 2002;7:1-4.
9. Weiss JS, Ellis CN, Goldfarb MT, et al. Tretinoin treatment of photodamaged skin. cosmesis through medical therapy. *Dermatol Clin*. 1991;9:123-129.