

Treatment of Severe Cutaneous Ulcerative Lichen Planus With Low Molecular Weight Heparin in a Patient With Hepatitis C

Julie A. Neville, MD; John G. Hancox, MD; Phillip M. Williford, MD; Gil Yosipovitch, MD

The ulcerative variant of lichen planus (LP) commonly involves the oral mucosa but is uncommon and difficult to treat when located on other areas. We describe an unusual case of ulcerative LP involving several surfaces, including the palms and scrotum, in a 50-year-old man with hepatitis C. The patient was recalcitrant to treatment with conventional therapy but obtained clearance with a sustained response using low molecular weight heparin (LMWH). This treatment is an option for patients with LP who are not ideal candidates for standard therapy.

Cutis. 2007;79:37-40.

Ulcerative, or erosive, lichen planus (LP) is a common variant of LP when the oral mucosa is involved but is uncommon on other cutaneous surfaces. On acral surfaces, ulcerative LP usually is found on the soles and rarely on the palms. In these locations, ulcerative LP typically presents as chronic, painful, cicatricial bullae and ulceration of the cutaneous surface.¹ Such involvement often is associated with nail changes and scarring alopecia.² The association between oral erosive LP and genital erosions in males is only rarely reported and, when genital lesions are present, the glans penis is the usual site of involvement. Genital involvement in females occurs more commonly, with one study demonstrating vulvar and vaginal involvement in 25% of females with oral LP.^{3,4}

Accepted for publication January 6, 2006.

From the Department of Dermatology, Wake Forest University School of Medicine, Winston-Salem, North Carolina.

The authors report no conflict of interest.

Reprints: Gil Yosipovitch, MD, Department of Dermatology, Wake Forest University School of Medicine, Medical Center Blvd, Winston-Salem, NC 27157-1071 (e-mail: gyosipov@wfuwmc.edu).

LP rarely can be a cause of cicatricial conjunctivitis, necessitating early treatment to prevent scarring.⁵ Nail involvement, including thinning, ridging, and distal splitting of the nail (onychoschizia), often occurs in patients with cutaneous disease. The patient also can be affected by onychomadesis, pterygium formation, longitudinal striation (onychorrhaxis), and absence of the nails (anonychia).⁶

We report the case of a patient with hepatitis C who developed ulcerative LP on several cutaneous surfaces, including his palm and scrotum, recalcitrant to treatment with standard therapy. The patient had clearance of the erosions using low molecular weight heparin (LMWH).

Case Report

A 50-year-old white man with a history of oral LP presented to our clinic with a 1-year history of painful ulcerations on the palm of the right hand and scrotum. Three years prior, he was diagnosed with histopathologically confirmed oral LP; direct immunofluorescence was negative for immunoglobulin (Ig) G, IgA, IgM, and complement 3. Topical corticosteroids produced resolution of the oral erosions and remission of his disease until an ulcer on the palm of the right hand developed. Despite 60 mg of oral prednisone, there was no remission of the ulcerative hand lesion. One month later, while the patient was on prednisone, he developed new scrotal and oral erosions. The patient also had a history of recurrent conjunctivitis and reported shedding of several fingernails and toenails. The pain associated with the ulcerations was debilitating, requiring narcotic analgesics and inhibiting his work in construction.

Physical examination revealed a 7×4-cm ulcerative plaque on the right palm with tense bullae at the periphery (Figure 1). Examination of the oral

mucosa showed healing erosions with a reticulate white plaque on the right buccal mucosa. The left conjunctiva was injected. Several fingernails and toenails showed pachyonychia with yellowish discoloration and onychomadesis with proximal pterygium formation on one fingernail. No scarring alopecia was noted on the scalp. The scrotum had extensive erosions (Figure 2).

One month prior to presenting to our clinic, tests for human immunodeficiency virus and syphilis were negative. Additional studies revealed a negative herpes simplex virus culture from the scrotum, mildly elevated aspartate aminotransferase at 58 U/L (reference range, 0–36 U/L) and alanine aminotransferase at 58 U/L (reference range, 5–35 U/L), and positive hepatitis C antibody. The patient had a history of consuming significant quantities of alcoholic beverages.

A punch biopsy from the right palm showed irregular epidermal hyperplasia with hyperkeratosis, hypergranulosis, and interface changes, with a bandlike infiltrate composed of lymphocytes and histiocytes in the papillary dermis (Figure 3).

Treatment options were limited by the patient's recently diagnosed or confirmed seropositivity for hepatitis C, alcohol consumption, and concomitant elevated liver function tests. Prior to receiving the histologic confirmation of LP, the patient was started on topical tacrolimus, applied to the erosions on the palm and scrotum with improvement but not clearance of the erosions on the scrotum within one month. Over the next month, he was treated with clobetasol foam under occlusion to the palm in addition to topical tacrolimus, with no improvement of this area. The patient continued on the topical therapies and was started on LMWH. Because of confusion with the dosage and difficulty dividing the dosage in the prefilled syringe, the patient received 30 mg subcutaneously biweekly the first 2 weeks and then continued on the prescribed dose of 3 mg subcutaneously biweekly thereafter. After 2 weeks of treatment, he experienced significant improvement and stopped using topical medications; after 4 weeks, he had complete resolution of the lesions on his palms, scrotum, and oral mucosa (Figures 4 and 5). LMWH subsequently was discontinued and the patient was in remission for 18 months. He developed a slight flare of LP on the palm, which was controlled with topical clobetasol and tacrolimus. His nails were unchanged. Treatment for hepatitis C was never initiated.

Comment

Ulcerative LP rarely involves multiple cutaneous surfaces, as was the case in our patient who

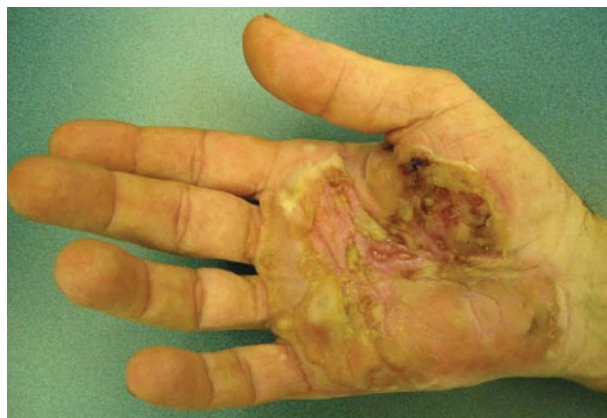

Figure 1. Ulcerative plaque on the right palm with tense bullae at the periphery.

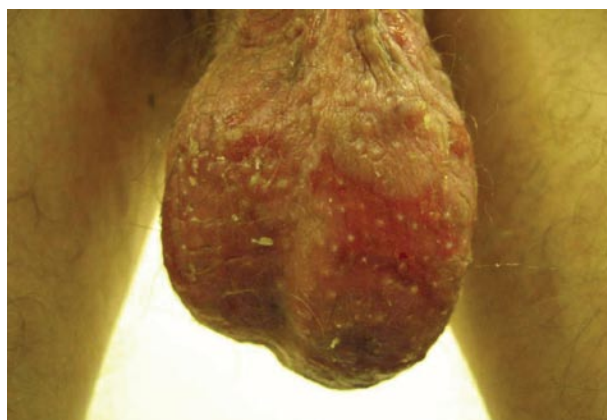

Figure 2. Erosions on the scrotum.

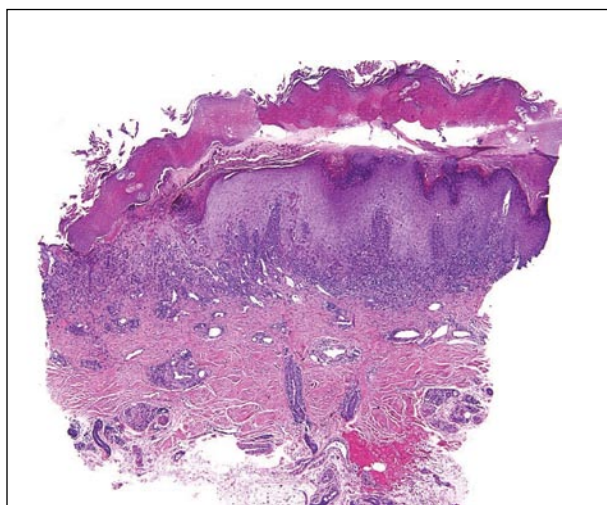


Figure 3. Irregular epidermal hyperplasia with hyperkeratosis, hypergranulosis, and interface changes, with a bandlike infiltrate composed of lymphocytes and histiocytes in the papillary dermis (H&E, original magnification $\times 10$).

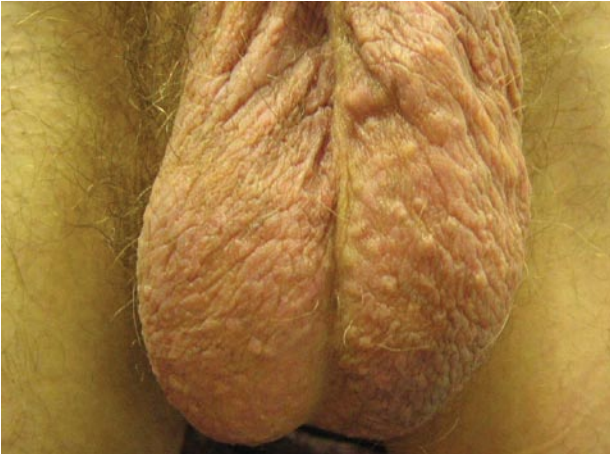

Figure 4. Resolution of the erosions on the scrotum after treatment with topical tacrolimus and low molecular weight heparin.

experienced involvement of the palm, scrotum, oral mucosa, nails, and possibly the conjunctiva. The patient had been followed by an ophthalmologist for conjunctivitis and fortunately did not have the cicatricial form of the disease.

Treatment for erosive LP often is difficult, but reported systemic therapies include cyclosporine, azathioprine, dapsone, thalidomide, and acitretin.^{7,8} Topically applied corticosteroids and calcineurin inhibitors, such as pimecrolimus and tacrolimus, have been reported to improve oral ulcerations.⁹⁻¹¹ Erosive LP involving the palms and soles has proven more difficult to treat. Surgical excision and split-thickness skin grafting was reported in several papers as an effective method of treatment.^{1,12} Prednisone also has been used to treat LP but can increase hepatitis C viral load, decrease alanine aminotransferase levels, and may increase morbidity.^{13,14}

Treatment of cutaneous LP with LMWH may be effective, as demonstrated in 3 studies, one of which included a patient with palmoplantar LP.¹⁵⁻¹⁷ The mechanism of action is unclear; however, several theories are purported. First, LP may be a type 4 hypersensitivity response to an unknown antigen in the epithelium, and heparin, even at low doses that provide no anticoagulant activity, may inhibit this delayed-type hypersensitivity.¹⁵ Heparin may act as a competitive inhibitor of heparanase, a component of the dermal extracellular matrix, thought to enhance the ability of T lymphocytes to migrate to target tissue.¹⁵ By inhibiting heparanase, patients may have a decreased inflammatory response and suppressed delayed-type hypersensitivity. Heparin also may act through a different mechanism by inhibiting the production of tumor necrosis factor α .¹⁸ In one published study, 11 of

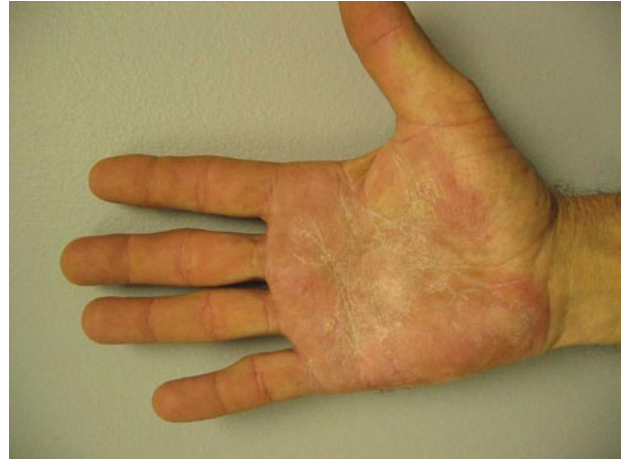

Figure 5. Resolution of the right palm ulceration after treatment with low molecular weight heparin.

18 patients (61%) with cutaneous LP treated with this modality had complete response.¹⁶ Heparin was not as effective at treating oral erosive LP.¹⁵

Studies examining LMWH have used low doses of this medication, 3 mg weekly, to mitigate the risk of anticoagulation while providing an effective dose. With this regimen, response to treatment occurred at 4 to 13 weeks.^{15,16} Because of confusion with the dosage, our patient received a higher dosage of 30 mg biweekly and responded within 2 weeks. These results suggest that increased dosing and frequency of injection may lead to a more rapid response, but these benefits must be weighed against the risk of dose-dependent side effects from anticoagulation.

The packaging of LMWH poses a challenge in the administration of low dosages. The medication comes in a prefilled syringe, with the smallest dose being 30 mg in 0.3 mL of diluent. Given the small volume, it was not possible to have the patient consistently deliver 3 mg of the medication. To overcome this obstacle, we diluted the LMWH in 10 mL of sterile saline. The patient was given insulin syringes and instructed on how to draw up and administer 1 mL (3 mg) of medication biweekly at home.

Although our patient received topical therapy, it only somewhat helped. We feel the significant resolution occurred with LMWH. In fact, topical therapy was discontinued when LMWH was working well, and the major improvement in the palmar disease occurred without topicals.

This case demonstrated the possible effectiveness of LMWH in the treatment of LP and this medication should be considered in treating patients with chronic LP, especially those patients who are not ideal candidates for standard therapy.

REFERENCES

1. Crotty CP, Su WP, Winkelmann RK. Ulcerative lichen planus: follow-up of surgical excision and grafting. *Arch Dermatol*. 1980;116:1252-1256.
2. Isogai Z, Koashi Y, Sunohara A, et al. Ulcerative lichen planus: a rare variant of lichen planus. *J Dermatol*. 1997;24:270-272.
3. Eisen D. The evaluation of cutaneous, genital, scalp, nail, esophageal, and ocular involvement in patients with oral lichen planus. *Oral Surg Oral Med Oral Pathol Oral Radiol Endod*. 1999;88:431-436.
4. Eisen D. The clinical features, malignant potential, and systemic association of oral lichen planus: a study of 723 patients. *J Am Acad Dermatol*. 2002;46:207-214.
5. Thorne JE, Jabs DA, Nikolskaya OV, et al. Lichen planus and cicatrizing conjunctivitis: characterization of five cases. *Am J Ophthalmol*. 2003;136:239-243.
6. Kim H, Pomeranz MK. Lupus erythematosus and lichen planus overlap syndrome. *J Drugs Dermatol*. 2004;3:311-312.
7. Henderson RL Jr, Williford PM, Molnar JA. Cutaneous ulcerative lichen planus exhibiting pathergy, response to acitretin. *J Drugs Dermatol*. 2004;3:191-192.
8. Camisa C, Popovsky JL. Effective treatment of oral erosive lichen planus with thalidomide. *Arch Dermatol*. 2000;136:1442-1443.
9. Esquivel-Pedraza L, Fernandez-Cuevas L, Ortiz-Pedroza G, et al. Treatment of oral lichen planus with topical pimecrolimus 1% cream. *Br J Dermatol*. 2004;150:771-773.
10. Hodgson TA, Sahni N, Kaliakatsou F, et al. Long-term efficacy and safety of topical tacrolimus in the management of ulcerative/erosive oral lichen planus. *Eur J Dermatol*. 2003;13:466-470.
11. Kaliakatsou F, Hodgson TA, Lewsey JD, et al. Management of recalcitrant ulcerative oral lichen planus with topical tacrolimus. *J Am Acad Dermatol*. 2002;46:35-41.
12. Cram DL, Kierland RR, Winkelmann RK. Ulcerative lichen planus of the feet. bullous variant with hair and nail lesions. *Arch Dermatol*. 1966;93:692-701.
13. McHutchison JG, Ponnudurai R, Bylund DL, et al. Prednisone withdrawal followed by interferon alpha for treatment of chronic hepatitis C infection. *J Clin Gastroenterol*. 2001;32:133-137.
14. Fong TL, Valinluck B, Govindarajan S, et al. Short-term prednisone therapy affects aminotransferase activity and hepatitis C virus RNA levels in chronic hepatitis C. *Gastroenterology*. 1994;107:196-199.
15. Hodak E, Yosipovitch G, David M, et al. Low-dose low-molecular-weight heparin (enoxaparin) is beneficial in lichen planus: a preliminary report. *J Am Acad Dermatol*. 1998;38:564-568.
16. Stefanidou MP, Ioannidou DJ, Panayiotides AD, et al. Low molecular weight heparin; a novel alternative therapeutic approach for lichen planus. *Br J Dermatol*. 1999;141:1040-1045.
17. Pacheco H, Kerdel F. Successful treatment of lichen planus with low-molecular-weight heparin: a case series of seven patients. *J Dermatolog Treat*. 2001;12:123-126.
18. Ferahbas A, Uksal U, Kutlugun C, et al. Low-molecular-weight heparin (enoxaparin) in the treatment of lichen planus. *J Eur Acad Dermatol Venereol*. 2003;17:604-605.