

Series Editor: Camila K. Janniger, MD

# Corrective Camouflage in Pediatric Dermatology

Aurora Tedeschi, MD; Federica Dall'Oglio, MD, PhD; Giuseppe Micali, MD; Robert A. Schwartz, MD, MPH; Camila K. Janniger, MD

*Many dermatologic diseases, including vitiligo and other pigmentary disorders, vascular malformations, acne, and disfiguring scars from surgery or trauma, can be distressing to pediatric patients and can cause psychological alterations such as depression, loss of self-esteem, deterioration of quality of life, emotional distress, and, in some cases, body dysmorphic disorder. Corrective camouflage can help cover cutaneous unaesthetic disorders using a variety of water-resistant and light to very opaque products that provide effective and natural coverage. These products also can serve as concealers during medical treatment or after surgical procedures before healing is complete.*

*Between May 2001 and July 2003, corrective camouflage was used on 15 children and adolescents (age range, 7–16 years; mean age, 14 years). The majority of patients were girls. Six patients had acne vulgaris; 4 had vitiligo; 2 had Becker nevus; and 1 each had striae distensae, allergic contact dermatitis, and postsurgical scarring. Parents of all patients were satisfied with the cosmetic cover results. We consider corrective makeup to be a well-received and valid adjunctive therapy for use during traditional long-term treatment and as a therapeutic alternative in patients in whom conventional therapy is ineffective.*

*Cutis.* 2007;79:110-112.

Accepted for publication August 24, 2005.

Drs. Tedeschi, Dall'Oglio, and Micali are from the Dermatology Clinic, University of Catania, Italy. Drs. Schwartz and Janniger are from Dermatology and Pediatrics, UMDNJ-New Jersey Medical School, Newark.

The authors report no conflict of interest.

Reprints: Aurora Tedeschi, MD, Clinica Dermatologica, Università di Catania, Piazza S. Agata La Vetere, 6, 95124 Catania, Italy (e-mail: cldermct@dimtel.nti.it).

Camouflage, or corrective maquillage, is a technique that can minimize the appearance of unaesthetic disorders, including pigmentary, vascular, and inflammatory conditions, and disfiguring scars from surgery or trauma (Table 1).<sup>1-8</sup> The alterations in appearance caused by these disorders can be psychologically damaging, especially for pediatric patients, and can lead to depression, loss of self-esteem, deterioration of quality of life, emotional distress, and, in some cases, body dysmorphic disorder.<sup>9-10</sup>

## History

The camouflage technique was introduced in the United States in the late 1960s and in France 20 years later.<sup>1-4</sup> Since then, its use has spread to the United Kingdom and the rest of Europe, including Italy.<sup>1,2,8</sup> Camouflage can be used to supplement medical or surgical treatments in pediatric patients who need an immediate remedy for dermatologic problems of cosmetic concern.

Table 1.

### Dermatoses That Might Benefit From Corrective Camouflage

Acne
Allergic/Irritant contact dermatitis
Hemangiomas
Hypopigmentation/Hyperpigmentation disorders
Scars (from surgery, burns, acne)
Striae distensae
Vascular malformations

Table 2.

### Steps of Corrective Camouflage

Clinical and psychological evaluation
Skin cleansing and hydrating
Application of green and/or yellow undercover
Application of foundation

### Methods

**Patient Population**—Between May 2001 and July 2003, 15 children and adolescents (12 girls, 3 boys) aged 7 to 16 years (mean age, 14 years) underwent consultation for corrective camouflage in Catania, Italy. Six patients had acne vulgaris; 4 had vitiligo; 2 had Becker nevus; and 1 each had striae distensae, allergic contact dermatitis, and postsurgical scarring.

**Using Corrective Camouflage**—A clinical evaluation was conducted on patients who might benefit from a cosmetic camouflage program (Table 2). Older children (aged 14 and older) were provided a questionnaire designed to evaluate the relationship between the dermatosis and the level of psychological discomfort. If the patient was deemed eligible for camouflage, the skin was then cleansed and hydrated using nonallergenic and noncomedogenic products. Pigmentary changes were

corrected through the application of green and/or yellow undercover to neutralize red (as observed in port-wine stains, erythema, inflammatory acne vulgaris, and red scars) and gray-brown or blue defects (as observed in congenital melanocytic nevi).<sup>5</sup> An appropriate foundation color selected from among light to very opaque, water-resistant or waterproof, noncomedogenic and nonallergenic products was applied to the forehead, nose, and chin, and allowed to dry. Waterproof characteristics of the foundation and its superior wearability were enhanced by the application of a powder, gently pressed with a puff or sponge, and allowed to set for approximately 5 minutes. Excess powder was dusted away with a fluffy powder brush.<sup>5,6</sup>

The patients returned to the camouflage clinic after 15 days to reevaluate quality of life after corrective camouflage and to determine their ability (or their parents' ability) to correctly apply the foundation.

### Results

All patients underwent cosmetic camouflage with excellent results (Figures 1 and 2). All parents were satisfied with the cosmetic cover results in their children, particularly the natural appearance provided by the camouflage.

### Comment

Corrective makeup is a well-received and valid adjunctive option for patients with skin disorders

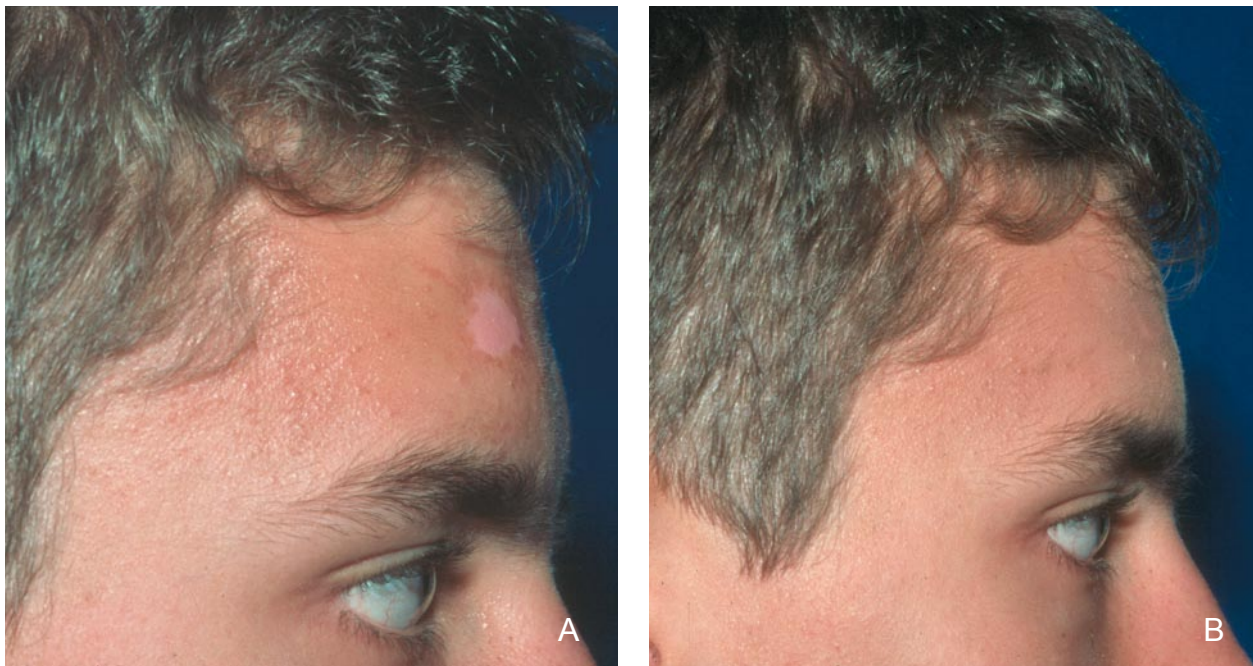
Figure not  
available online

A

Figure not  
available online

B

**Figure 1.** A 15-year-old adolescent girl with inflammatory acne vulgaris before (A) and after (B) camouflage therapy applied to acne lesions.



**Figure 2.** A 16-year-old adolescent boy with vitiligo before (A) and after (B) camouflage therapy applied to the hypopigmented area.

affecting appearance; it can be used during traditional long-term therapies. It also is a useful therapeutic alternative in patients in whom conventional therapy is ineffective. Furthermore, it can have a positive effect on patients' social lives. In our patient population, the complete cover of unaesthetic disorders definitely lessened psychological discomfort. The questionnaire administered to older children (aged 14 and older) at the beginning of the study revealed the level of impact that certain disorders or defects had on these patients' lives. Patients with acne scars reported embarrassment and difficulty establishing new relationships; patients with vitiligo reported irritability, worry, and embarrassment, and limitations in social life, including discontinuation of sports such as swimming; and some patients with postsurgical scarring revealed body dysmorphic disorder. After corrective camouflage, all patients reported substantial improvements in their quality of life.

### Conclusion

Corrective camouflage is a valid adjunctive tool that can be used during traditional long-term therapies. It also is a useful therapeutic alternative in patients in whom a conventional cosmetic approach, self-tanning preparations, or tattooing would be ineffective, inappropriate, or ill advised.

### REFERENCES

1. Tedeschi A, Dall'Oglio F, Micali G. Our experience in the corrective camouflage in dermatology practice.

Presented at: XI Congress of the European Academy of Dermatology and Venereology (EADV); October 2-6, 2002; Prague, Czech Republic.

2. West LE, West D, Tedeschi A, et al. A corrective cosmetic cover clinic within a dermatology practice. Poster presented at: 62nd Annual Meeting of the American Academy of Dermatology; February 6-11, 2004; Washington, DC. P276.
3. Cohen S. The use of 'covermark' in the treatment of skin disfigurements. *S Afr Med J.* 1965;39:301.
4. Jung HD. The treatment of disfiguring skin changes using water resistant make-up Covermark. *Z Haut Geschlechtskr.* 1970;45:351-356.
5. Roberts NC. Corrective cosmetics—need, evaluation and use. *Cutis.* 1988;41:439-441.
6. Draelos ZK. Cosmetic camouflaging techniques. *Cutis.* 1993;52:362-364.
7. Hell B, Frangillo-Engler F, Heissler E, et al. Camouflage in head and neck region—a non-invasive option for skin lesions. *Int J Oral Maxillofac Surg.* 1999;28: 90-94.
8. Caputo R, Barbareschi M, Baggini G, et al. The corrective make-up lab: the Italian experience. Poster presented at: 60th Annual Meeting of the American Academy of Dermatology; February 22-27, 2002; New Orleans, La. P430.
9. Patterson WM, Bienvenu OJ, Chodynicky MP, et al. Body dysmorphic disorder. *Int J Dermatol.* 2002;40: 688-690.
10. Patterson WM, Stibich AS, Dobke M, et al. Mutilating facial acne conglobata. *Cutis.* 2000;66:139-140.