

Thyroid Dermopathy: An Underrecognized Cause of Leg Edema

Faraz Kureshi, BSc; Mark D.P. Davis, MD; Nicole M. Burkemper, MD; Roger H. Weenig, MD; Mark R. Pittelkow, MD; Gail L. Gamble, MD

Leg edema is a common clinical problem and the differential diagnosis is extensive. We present 4 patients in whom thyroid dermopathy was the cause of leg edema. Examination of the eyes and the nature of the edema were clues to the diagnosis of thyroid dermopathy. Clinical signs should be documented and analysis of skin biopsy specimens should be performed in patients suspected to have thyroid dermopathy.

Cutis. 2007;79:219-224.

Leg edema is a common clinical problem with many causes.¹ Thyroid dermopathy as a cause of leg edema may be underdiagnosed and should be included in the differential diagnosis of nonpitting leg edema. Thyroid dermopathy is readily diagnosed on clinical examination and by histopathologic examination of a skin biopsy specimen. We present 4 patients with thyroid dermopathy (Table).

Case Reports

Patient 1—A 54-year-old woman presented with a 5-year history of progressive leg edema that was thought to be lymphedema but was unresponsive to compression techniques. The patient had a history of Graves disease and was receiving replacement thyroid hormone.

Physical examination revealed nonpitting edema and induration of the skin of both legs (Figure 1A). Discrete and confluent subcutaneous masses with overlying pink to violaceous patches were noted. The hardened edema was almost plaquelike and occurred circumferentially on the distal limbs and both feet. In addition, bilateral exophthalmos was

noted, which was greater on the left side than the right side.

An incisional skin biopsy specimen demonstrated typical histologic findings for thyroid dermopathy (also called pretibial myxedema or Graves dermopathy)(Figure 1B). Alcian blue stain highlighted a marked increase in dermal mucin. The findings from direct immunofluorescence were nondiagnostic, and culture results were negative for fungal, mycobacterial, and bacterial growth. The patient was treated with topical corticosteroids and tap water wet wraps, and intensive low-stretch compression therapy was initiated at our lymphedema clinic.

Patient 2—A 69-year-old man was referred to the dermatology department with progressive swelling of the feet, legs, and hands. Swelling of his legs had developed in 2001, initially starting on the shins and eventually progressing to the feet. Prominent skin folds also developed, followed by progressive thickening of the fingers and toes, with knotty changes over the fingers, toes, forearms, and wrists. The patient also had a history of Graves disease. In 1999, Graves ophthalmopathy including proptosis, conjunctival edema, blurred vision, and intermittent double vision developed. The patient received orbital ionizing radiation and started taking propylthiouracil 50 mg orally twice daily.

On physical examination, his hands were large and coarse with plaques and nodules. Several nodules also were noted on the forearms and dorsa of the toes. Large erythematous to more violaceous indurated plaques and secondary hyperkeratosis with a brown dirty-appearing scale were noted on the legs (Figure 2). The patient also had thyroid acropachy.

The patient's thyroid peroxidase (TPO) antibody levels were markedly increased (3750 IU/mL; reference range, ≤ 40 IU/mL), as was his thyroid-stimulating immunoglobulin (TSI, previously known as long-acting thyroid stimulator) value (17; reference range, ≤ 1.3 TSI index). His thyroid-stimulating hormone (TSH) and free thyroxine

Accepted for publication February 8, 2006.

From the Departments of Dermatology and Physical Medicine and Rehabilitation, Mayo Clinic, Rochester, Minnesota.

Supported by the Mayo Foundation for Medical Education and Research. The authors report no conflict of interest.

Reprints not available from the authors.

Patient Characteristics*

Patient No./ Sex/ Age, y	Duration of Edema, y	Prior Diagnoses	Duration of Graves Disease, y	Laboratory Values			
				TPO Antibody, IU/mL [†]	TSH, mIU/L [§]	FT ₄ , ng/dL	TSI [‡]
1/F/54	5	Lymphedema	10	NA	9.8	0.3	2
2/M/69	3	Unknown	7	3750	17	1.4	0.9
3/F/69	0.8	Cellulitis, erythromelalgia	2	NA	NA	3.4	1
4/F/47	4	Lymphedema, cellulitis	12	85	13	0.43	1.1

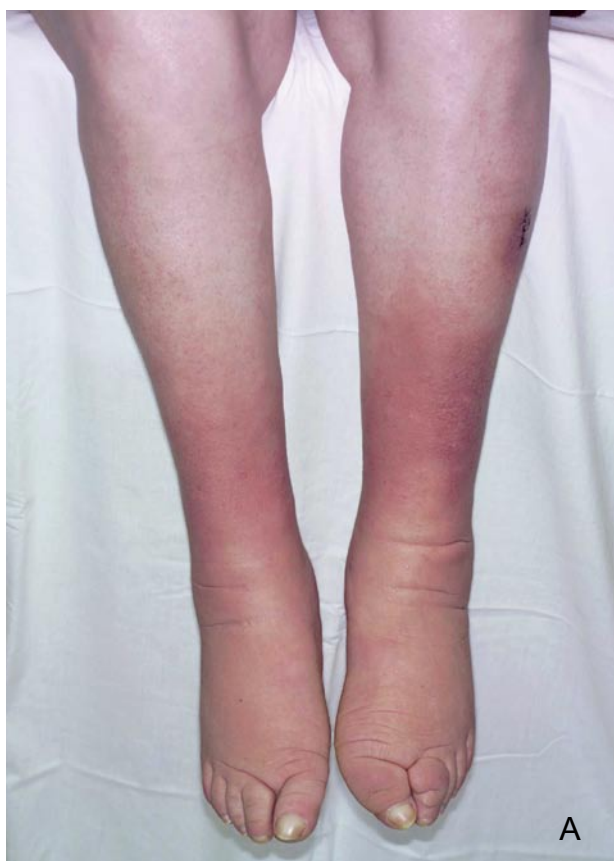*TPO indicates thyroid peroxidase; TSI, thyroid-stimulating immunoglobulin; TSH, thyroid-stimulating hormone; FT₄, free thyroxine; F, female; NA, not available; M, male.

[†]Reference range, ≤40 IU/mL.

[‡]Reference range, ≤1.3 TSI index.

[§]Reference range, 0.3–5.0 mIU/L.

^{||}Reference range, 0.8–1.8 ng/dL.



(FT₄) concentrations were within reference range. Results of biopsy specimens were consistent with thyroid dermopathy.

Mechanical measures to decrease thyroid dermopathy were recommended. The lesions responded within 2 days of initiating manual lymphatic drainage of the face, neck, and trunk, and low-stretch compression therapy of the lower legs and hands. Substantial tissue softening was noted on the hands, with measured volume reduction recorded in the lower extremities. Manual lymphatic drainage,

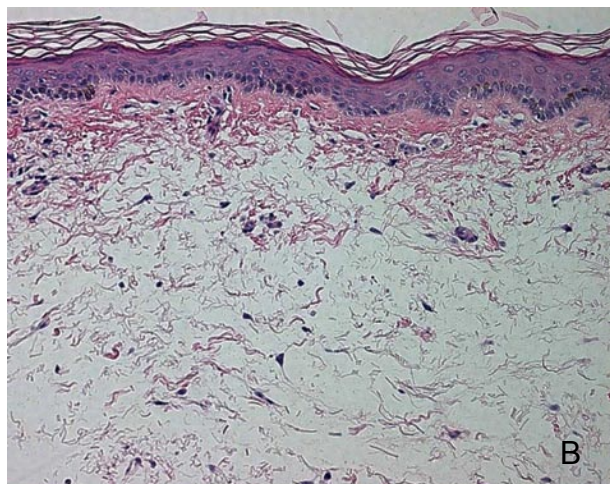


Figure 1. A 54-year-old woman (patient 1) with hardened indurated pretibial skin. The hardened edema was circumferential and almost plaque-like in appearance (A). An incisional skin biopsy specimen indicated mucin deposition in the dermis (H&E, original magnification ×20)(B).

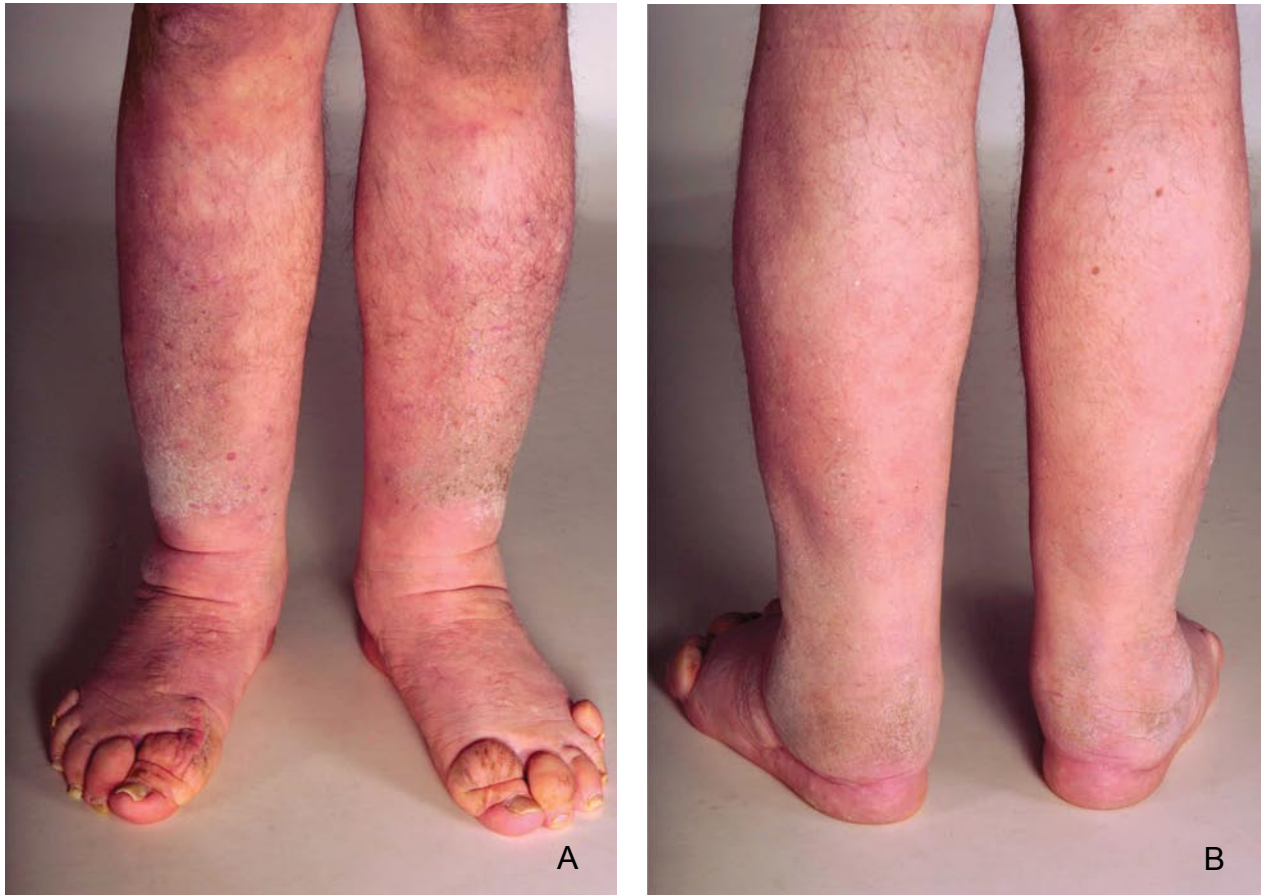


Figure 2. A 69-year-old man (patient 2) with fixed edema on his legs (A and B).

exercises, and complex low-stretch compression therapy of the face and upper and lower extremities were recommended to be continued at a local treatment program.

Patient 3—A 69-year-old woman presented with a 10-month history of worsening lower extremity edema. Symptoms began with an erythematous plaque on the right dorsal foot, which progressed to the leg. The patient was hospitalized in her hometown for presumptive cellulitis. She later received a diagnosis of erythromelalgia from a dermatologist and started receiving 325 mg of aspirin 3 times daily, without benefit. The edema and erythema continued to progress from the right lower extremity to the knee. Approximately 4 months later, the left lower extremity was similarly affected. The edema and erythema had not responded to oral antibiotics, furosemide, and topical hydrocortisone cream 2.5%, or compression stockings (ankle pressure, 20–30 mm Hg).

The patient had a history of Graves disease and had had radioactive iodine ablation 2 years earlier. Physical examination noted indurated edematous skin with diffuse erythema on the bilateral lower extremities from the knees down, which was not

warm to the touch (Figure 3A). Several areas had a peau d'orange–like appearance. Some superficial scaling and verrucous hyperplasia also were apparent distally. Coarse facial features and exophthalmos were noted. The hands had vague thickening bilaterally but no erythema.

A skin biopsy specimen was obtained from the right lower leg. Results of histopathologic analysis were consistent with thyroid dermatopathy (Figure 3B). Results of thyroid function tests were within reference range. The patient was seen in our lymphedema clinic and a program of low-stretch compression therapy was instituted. She also was given a prescription for triamcinolone acetonide ointment 0.1%.

Patient 4—A 47-year-old woman presented with a 4-year history of eye changes and progressive swelling of the lower legs. Her condition began as red patches on the legs that progressed to disabling edema. She was unable to wear shoes, walk, or perform many of her normal daily tasks. The leg edema was managed as lymphedema with an intermittent compression pump and wraps. She had received multiple courses of antibiotics for cellulitis. During the previous 4 years, she had noticed protrusion of her eyes.

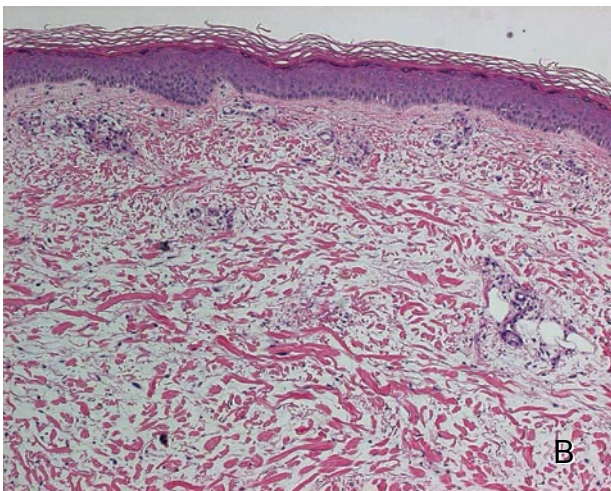
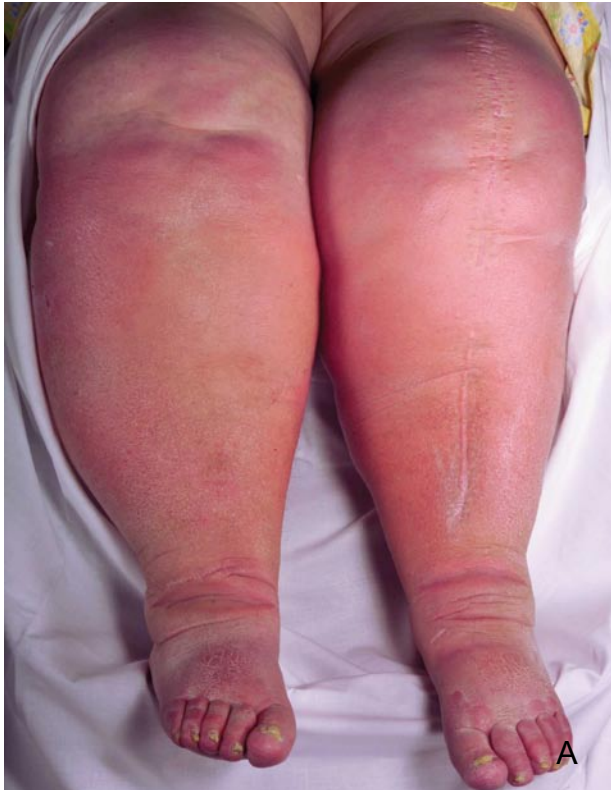

Figure 3. A 69-year-old woman (patient 3) with fixed edema (A). A skin biopsy specimen from the right lower leg indicated mucin deposition in the dermis (H&E, original magnification $\times 20$)(B).

She also had a history of cervical cancer, total abdominal hysterectomy, bilateral salpingo-oophorectomy, lymphadenectomy, and pelvic radiotherapy.

Twelve years earlier, the patient had been diagnosed with Graves disease and subsequently was treated with radioactive iodine. Physical examination indicated massive bilateral lower extremity edema with brawny induration and papillomatous

changes of the lower legs extending to the thighs (Figures 4A and 4B). Nonpitting edema of the feet was present, with creasing and squaring of the toes consistent with lymphedema. The upper extremities were not involved. Prominent bilateral exophthalmos was noted (Figure 4C).

The patient's TPO antibody and TSI concentrations were elevated, but TSH and FT₄ concentrations were normal. Lymphoscintigraphy showed no substantial changes. The use of low-stretch compression therapy of the lower extremities at the lymphedema clinic markedly reduced the edema.

Comment

Diagnosis of Thyroid Dermopathy—We present 4 patients in whom delay in the diagnosis of thyroid dermopathy ranged from 10 months to 5 years. Prior diagnoses varied from lymphedema to cellulitis to erythromelalgia. The patients had extensive and disabling involvement of the skin, contrary to previous reports that thyroid dermopathy merely is a cosmetic problem.²

Clues to the diagnosis were apparent in all patients because of the history (Graves disease) and physical examination (the character of the edema and presence of exophthalmos). Although thyroid dermopathy is rare, the physician should be alert to the historical and objective signs of this condition when assessing patients with edema to establish the correct diagnosis and prevent unnecessary treatments, such as multiple courses of antibiotics.

Thyroid dermopathy is characterized by localized nonpitting edema secondary to the deposition of dermal and subcutaneous hyaluronic acid. The nonpitting edema form of thyroid dermopathy is the most prevalent. The nodular form has been reported in 20% of cases and the plaquelike form occurs in 21% of cases. The elephantiasis form is a rare and extreme form of thyroid dermopathy, occurring in only 1 of 150 patients with skin involvement. Hyperpigmentation and progressive thickening accompany nonpitting edema, and the skin becomes thickened, woody, and firm, with a black-gray appearance. The combined incidence of the polypoid and elephantiasis types represents less than 1% of cases. More than one type can coexist. Although the pretibial area is the region most commonly involved (99.4% of cases),³ patient 2 illustrates that other areas of the body, such as the upper extremities, may be affected. Thyroid dermopathy can occur anywhere on the body, including the hands, arms, shoulders, ankles, ears, and face, and in skin grafts, surgical scars, sports injuries, and animal bites.

**Figure not
available online**

A

**Figure not
available online**

B

**Figure not
available online**

C

Figure 4. A 47-year-old woman (patient 4) with fixed edema (A and B). The patient also displayed prominent bilateral exophthalmos (C).

The history of Graves disease in patients with nonpitting edema was a clue to the diagnosis of thyroid dermopathy in our patients. Thyroid dermopathy, however, is reported to occur in less than 5% of all patients with Graves disease.⁴ Cases of thyroid dermopathy also have been reported in patients with other forms of thyroid disease, such as Hashimoto thyroiditis, primary hypothyroidism, and euthyroidism.^{3,5,6} The dermatologic manifestations of autoimmune thyroid disease have been reviewed.⁷

All of our patients had exophthalmos, which is another major clinical clue to the diagnosis of thyroid dermopathy. Thyroid dermopathy has a high incidence in patients with Graves ophthalmopathy (approximately 15%)⁴; conversely, in a study of 178 patients with thyroid dermopathy, 97% had Graves ophthalmopathy.³

Of interest, our patients had signs suggestive of lymphedema. Bull et al⁸ reported that thyroid dermopathy in its most extreme form clinically resembles lymphedema. Studies with quantitative lymphoscintigraphy and fluorescence microlymphography in 2 patients with extensive thyroid dermopathy confirmed the presence of both functional and structural changes in the lymphatic system. The authors suggested that mucin deposition in the dermis causes compression of the dermal lymphatics, resulting in dermal edema and clinical features of lymphedema.⁸

Similar to previous reports, the majority of patients (3/4) presented in the current report were women. Women are affected more frequently than men, with a female-male ratio of 4:1.²

A diagnosis of thyroid dermopathy can be confirmed by examination of skin biopsy specimens.

Skin biopsy specimens from patients with thyroid dermopathy show normal collagen and wide separation of the superficial dermal collagen bundles. Mucin stains (Alcian blue or colloidal iron) indicate the presence of mucin between the separated collagen bundles.

The cause of thyroid dermopathy is poorly understood. In our patients, the TSH and FT₄ levels were normal, but TPO antibody and TSI levels were high in those patients tested. It has been proposed that fibroblasts are stimulated by TSI to produce excessive amounts of glycosaminoglycan. TSH and TSH-receptor antibody binding sites have been identified on fibroblasts of patients with thyroid dermopathy.⁹ Testing for TSI and TPO antibodies should be considered in patients with leg edema because they provide a rationale for management.

The natural history of thyroid dermopathy is not well-understood. Little is known about the long-term outcome of patients with thyroid dermopathy. Of the 178 patients with thyroid dermopathy followed up by Fatourechy et al³ for a mean of 7.9 years, 26% of the patients had complete remission, 24.2% of the patients had moderate improvement (partial remission), and 50% of the patients had no improvement or minimal improvement of dermopathy at last follow-up.

Treatment—Treatment options for thyroid dermopathy are limited. Currently, topical corticosteroids are the only treatments with established efficacy³; however, this approach often does not provide substantial benefit, especially for patients with more severe dermopathy. Patients with more mild forms of dermopathy often are not treated. The beneficial effect of topical corticosteroid therapy on long-term remission rates remains undetermined.

Suppression of the TSI would seem a logical therapeutic goal. Newer treatment regimens, such as octreotide, an insulin analog, and high-dose intravenous immunoglobulin show promise but require further investigation.^{10,11} Other treatment options include rituximab, anti-tumor necrosis factor agents, or other biologic drugs that target autoantibody production or inflammatory-immune mediators.

The association of thyroid dermopathy with clinical features of lymphedema provides some therapeutic options directed at reducing swelling of the extremities, trunk, or head and neck, depending on the sites of involvement. Manual compression therapy, including manual lymph drainage techniques in

combination with low-stretch compression therapy, has been found to be helpful.¹² Our patients were referred to the lymphedema clinic, a specialized program to administer these physical interventions and educate patients in low-stretch compression therapy and skin care. All patients had beneficial volume reduction of the involved extremities.

Conclusion

We present 4 patients with leg edema as a sign of previously unrecognized thyroid dermopathy. This condition should be included in the differential diagnosis of leg edema, especially in patients who have a history or signs of Graves disease.

REFERENCES

1. Cho S, Atwood JE. Peripheral edema. *Am J Med.* 2002;113:580-586.
2. Omohundro C, Dijkstra JW, Camisa C, et al. Early onset pretibial myxedema in the absence of ophthalmopathy: a morphologic evolution. *Cutis.* 1996;58:211-214.
3. Fatourechy V, Pajouhi M, Fransway AF. Dermopathy of Graves disease (pretibial myxedema); review of 150 cases. *Medicine (Baltimore).* 1994;73:1-7.
4. Georgala S, Katoulis AC, Georgala C, et al. Pretibial myxedema as the initial manifestation of Graves' disease. *J Eur Acad Dermatol Venereol.* 2002;16:380-383.
5. Cannavo SP, Borgia F, Vaccaro M, et al. Pretibial myxoedema associated with Hashimoto's thyroiditis. *J Eur Acad Dermatol Venereol.* 2002;16:625-627.
6. Srebrnik A, Ophir J, Brenner S. Euthyroid pretibial myxedema. *Int J Dermatol.* 1992;31:431-432.
7. Ai J, Leonhardt JM, Heymann WR. Autoimmune thyroid diseases: etiology, pathogenesis, and dermatologic manifestations. *J Am Acad Dermatol.* 2003;48:641-659.
8. Bull RH, Coburn PR, Mortimer PS. Pretibial myxoedema: a manifestation of lymphoedema? *Lancet.* 1993;341:403-404.
9. Prabhakar BS, Bahn RS, Smith TJ. Current perspective on the pathogenesis of Graves' disease and ophthalmopathy. *Endocr Rev.* 2003;24:802-835.
10. Antonelli A, Navarranne A, Palla R, et al. Pretibial myxedema and high-dose intravenous immunoglobulin treatment. *Thyroid.* 1994;4:399-408.
11. Heymann WR. Advances in the cutaneous manifestations of thyroid disease. *Int J Dermatol.* 1997;36:641-645.
12. Susser WS, Heermans AG, Chapman MS, et al. Elephantiasic pretibial myxedema: a novel treatment for an uncommon disorder. *J Am Acad Dermatol.* 2002;46:723-726.