

Persistent Inflammatory Reaction to Hyaluronic Acid Gel: A Case Report

Emil Bisaccia, MD; Alexander Lugo, MD; Omar Torres, MD; Brad Johnson, MD; Dwight Scarborough, MD

Soft tissue augmentation is widely used to enhance or improve a patient's appearance. Hyaluronic acid is considered to be one of the best fillers for cosmetic procedures, mainly because of its lack of immunogenicity. We report a case of a persistent inflammatory reaction to injectable hyaluronic acid gel used for the correction of melolabial folds.

Cutis. 2007;79:388-389.

Soft tissue augmentation is one of the most common cosmetic procedures performed by dermatologists. The unique benefits of limited downtime and uncommonly encountered side effects contribute to the broad usage of this procedure.

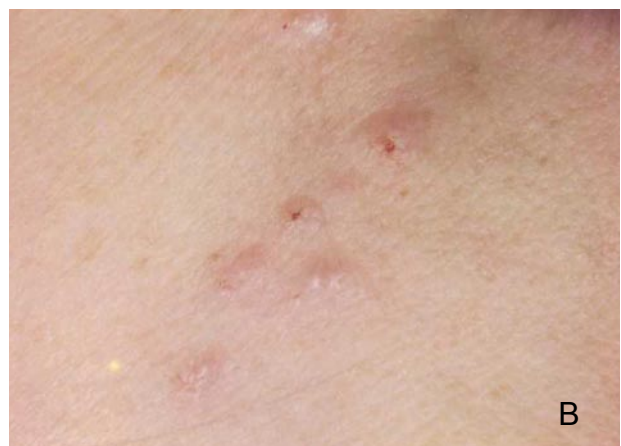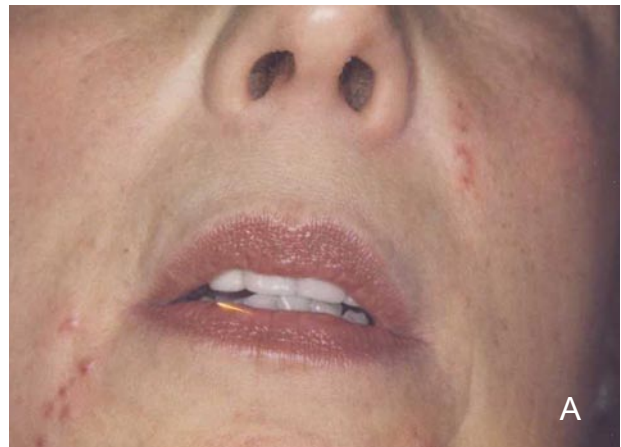
Soft tissue augmentation is used to enhance or improve a patient's appearance. Before modern procedures were established, soft tissue augmentation was performed utilizing candle wax, beeswax, paraffin, and various oils.¹ These modalities were discontinued because of undesirable reactions, displacement of the material to adjacent tissues, chronic edema, scarring, and granuloma formation, causing undesirable results.

Hyaluronic acid is considered to be one of the best fillers for cosmetic procedures, mainly because of its lack of immunogenicity.² However, case reports have revealed tissue reactions to hyaluronic acid.³⁻⁶ We report a case of a persistent inflammatory reaction to injectable hyaluronic acid gel used for correction of the melolabial folds.

Case Report

A 56-year-old woman presented for a cosmetic consultation for correction of the melolabial folds.

Treatment options were discussed with the patient and the dermal filler, injectable hyaluronic acid gel, was chosen as the most appropriate filler for the patient. Injection of 0.7 mL of hyaluronic acid gel along the melolabial folds, using a linear threading technique, was performed. The procedure was well-tolerated and the patient was satisfied with the immediate results. Twenty-seven days after the filler was injected, the patient developed asymptomatic erythematous indurated papules along the injection sites (Figure). The diagnosis of persistent inflammatory reaction to



Erythematous indurated papules along the injection sites for the correction of the melolabial folds (A and B).

Accepted for publication February 16, 2006.

From the Affiliated Dermatology Cosmetic Dermatology Center, Morristown, New Jersey. Dr. Bisaccia also is from Columbia University, College of Physicians and Surgeons, New York, New York. Dr. Scarborough also is from Ohio State University Hospitals, Columbus.

The authors report no conflict of interest.

Reprints: Emil Bisaccia, MD, 182 South St, Suite 1, Morristown, NJ 07960.

injectable hyaluronic acid gel was made. The patient was subsequently treated with intralesional triamcinolone acetonide injections at 10 mg/mL. After 2 sessions of intralesional triamcinolone acetonide injections, 2 weeks apart, the inflammatory reactions subsided, leaving no scarring.

Comment

Hyaluronic acid is a naturally occurring substance found within the intercellular space of the dermis. Injectable hyaluronic acid gel is a nonanimal partially cross-linked hyaluronic acid that is biosynthetically produced by bacterial fermentation. Its major advantage is that no pretest is necessary because of the probable biocompatibility of the hyaluronic acid. A review of 144,000 patients treated with hyaluronic acid for soft tissue augmentation found a 0.15% and 0.06% incidence of adverse events in 1999 and 2000, respectively. Most adverse events had been hypersensitivity reactions.⁷ Local adverse events usually are transient and include bruising, tenderness, discomfort, edema, and erythema.^{8,9} These side effects reportedly have been reduced with the use of a newer generation injectable hyaluronic acid gel, which has a 6-fold reduction in the protein load, producing less reactivity at the injection site.¹⁰ However, a few cases of hypersensitive skin reactions and granulomatous foreign body formation with hyaluronic acid have been reported in the medical literature.³⁻⁶ Although this filler is suggested to be inert in nature, we report another case of persistent inflammatory reaction over areas injected with injectable hyaluronic acid gel for cosmetic purposes. To avoid invasive testing with the possibility of scarring in a cosmetic patient and considering the reports of inflammatory and granulomatous reactions to injectable hyaluronic acid gel, a skin biopsy was not performed. We report this case so that

the practicing dermatologist is aware of the possibility of a persistent inflammatory reaction to injectable hyaluronic acid gel.

REFERENCES

1. Bisaccia E, Scarborough DA. Soft tissue augmentation. In: Bisaccia E, Scarborough DA. *The Columbia Manual of Dermatologic Cosmetic Surgery*. New York, New York: McGraw-Hill; 2002:109-133.
2. Richter AW, Ryde EM, Zetterstrom EO. Nonimmunogenicity of a purified sodium hyaluronate preparation in man. *Int Arch Allergy Appl Immunol*. 1988;59:45-48.
3. Lupon JR, Alster TS. Cutaneous hypersensitivity reaction to injectable hyaluronic acid gel. *Dermatol Surg*. 2000;26:135-137.
4. Raulin C, Greve B, Hartschuh W, et al. Exudative granulomatous reaction to hyaluronic acid (Hyliform). *Contact Dermatitis*. 2000;43:178-179.
5. Shafir R, Amir A, Gur E. Long-term complications of facial injections with Restylane (injectable hyaluronic acid). *Plast Reconstr Surg*. 2000;106:1215-1216.
6. Fernandez-Acenero J, Zamora E, Borbujo J. Granulomatous foreign body reaction against hyaluronic acid: report of a case after lip augmentation. *Dermatol Surg*. 2003;29:1225-1226.
7. Friedman PM, Mafong EA, Kauvar AN, et al. Safety data of injectable nonanimal stabilized hyaluronic acid for soft tissue augmentation. *Dermatol Surg*. 2002;28:491-494.
8. Naoum C, Dasiou-Plakida D. Dermal filler materials and botulin toxin. *Int J Dermatol*. 2001;40:609-621.
9. Narins RS, Brandt F, Leyden J, et al. A randomized, double blind, multicenter comparison of the efficacy and tolerability of Restylane versus Zyplast for the correction of nasolabial folds. *Dermatol Surg*. 2003;29:588-595.
10. Klein AW. Skin filling collagen and other injectables of the skin. *Dermatol Clin*. 2001;19:491-508.